



Effects of Aloe Vera and Chitosan Nanoparticle Thin-Film Membranes on Wound Healing in Full Thickness Infected Wounds with Methicillin Resistant Staphylococcus Aureus

Reza Ranjbar¹, Alireza Yousefi^{2*}

¹Molecular Biology Research Center, Systems Biology and Poisonings Institute, Baqiyatallah University of Medical Sciences, Tehran, Iran

²Department of Surgery and Diagnostic Imaging, Faculty of Veterinary Medicine, Urmia University, Urmia, Iran

*Corresponding author: Alireza Yousefi

Address: Department of Surgery and Diagnostic Imaging, Faculty of Veterinary Medicine, Urmia University, Nazloo Road, Urmia, 57153 1177, Iran.

Tel: +98-443-2770508; Fax: +98-443-2771926

e-mail: alireza.yousefi4@yahoo.com

Received: August 28, 2017

Revised: November 11, 2017

Accepted: November 21, 2017

ABSTRACT

Objective: To assess effect of Aloe vera with chitosan nanoparticle biofilm on wound healing in full thickness infected wounds with antibiotic resistant gram positive bacteria.

Method: Thirty rats were randomized into five groups of six rats each. Group I: Animals with uninfected wounds treated with 0.9% saline solution. Group II: Animals with infected wounds treated with saline. Group III: Animals with infected wounds were dressed with chitosan nanoparticle thin-film membranes. Group IV: Animals with infected wounds were treated topically with Aloe vera and Group V: Animals with infected wounds were treated topically with Aloe vera and dressed with chitosan nanoparticle thin-film membranes. Wound size was measured on 6, 9, 12, 15, 18 and 21 days after surgery.

Results: Microbiology, reduction in wound area and hydroxyproline contents indicated that there was significant difference ($p < 0.05$) between group V and other groups. Quantitative histological studies and mean rank of the qualitative studies demonstrated that there was significant difference ($p < 0.05$) between group V and other groups.

Conclusion: The Aloe vera with chitosan nanoparticle thin-film membranes had a reproducible wound healing potential and hereby justified its use in practice.

Keywords: Aloe vera; Chitosan nanoparticle; Thin-film membrane; MRSA; Wound; Rat.

Please cite this paper as:

Ranjbar R, Yousefi AR. Effects of Aloe Vera and Chitosan Nanoparticle Thin-Film Membranes on Wound Healing in Full Thickness Infected Wounds with Methicillin Resistant Staphylococcus Aureus. *Bull Emerg Trauma*. 2018;6(1):8-15. doi: 10.29252/beat-060102.

Introduction

Increasing the rate of wound healing in burns and skin injuries has always been of great interest to medical professions. Wound healing is a complex

process by which heals through the same process [1]. Dysfunctional immune system and presence of an infection which may be the normal flora or other opportunistic microbes that is in the environment. The most common infections in the wounds are caused by

Staphylococcus aureus, *Pseudomonas aeruginosa*, *Enterococcus* species and *Escherichia coli* [2]. Different course of antibiotic resistance, especially in methicillin resistant *Staphylococcus aureus* (MRSA) demand a new approach to management of innovative treatments [3]. To manage medical treatment of infected wounds, lots of agents and protocols have been proposed in the literature [4,5].

Aloe vera leaves contain two products. One is the gel, in the inner side of the leaf and the other is the bitter yellow juice on the outside of inner layer before the external covering. Aloe vera gel is composed of 98.5 percent water and its viscous (gel form) due to the sugar of glucomannan. This gel has about 200 active ingredients including minerals, vitamins, proteins, lipids, amino acids and polysaccharides [6]. These compounds can be noted like acemannan which strengthens the immune system and Brady kinase that has anti-inflammatory properties and magnesium lactate that reduce itching and the other soothing and anti-inflammatory such as sialic acid and antiprostaglandins [7]. The yellow juice contains anthraquinone glycosides like Aloin, Aloe-emodin, Barbaloin which are potentially laxative. Effect of Aloe vera gel for wound healing is to modulate and optimize the immune system to accelerate wound healing process [8]. Aloe vera shows a beneficial effect by reducing the inflammation significantly and providing a more mature granulation tissue which could accelerate healing and might produce a sound well-remodeled scar [9]. It increases the activity of macrophages and monocytes and stimulation of killer T lymphocytes which is done through releasing the interleukin 1 and 6, and TNF- α , INF- β , Aloe Vera gel can also block the production of prostaglandin and thromboxane from arachidonic acid to reduce inflammation in the wound [10]. It can also have inhibitory effect against pathogenic bacteria, causing food poisoning or different diseases in humans [11]. There are about 200 species of Aloe vera in the world. Among all, Aloe vera *Barbadensis* Miller is the best-known because of being the richest in useful materials for healing [12].

Chitosan is a non-toxic cationic biopolymer usually obtained by alkaline deacetylation from chitin, which is the principal component of crustacean exoskeletons [13]. Chitosan presents with biocompatibility, chelating capacity and also antimicrobial effects against a broad range of gram positive and gram-negative bacteria as well as fungi [14,15]. Previous in vitro studies have demonstrated the significant biofilm efficacy of chitosan nanoparticles (CNPs) [16,17].

To the best knowledge of the authors the literature is poor regarding potentiation effects of Aloe vera loaded chitosan nanoparticle biofilm on wound healing in full thickness infected wounds with antibiotic resistant gram positive bacteria. Therefore, the present study aimed to study effects of combination of Aloe vera loaded chitosan nanoparticle biofilm on

wound healing in full thickness infected wounds with methicillin resistant *Staphylococcus aureus*.

Materials and Methods

Animals

The study was approved by the institutional animal research ethics committee and 3R's principle was strictly followed. Thirty adult healthy male Wistar rats weighting 200–250 g were used and housed in individual cages under constant temperature (22°C) and humidity with 12-h light/dark cycle, and had ad libitum access to chow and water throughout the study.

Aloe Vera Gel Preparation

Aloe vera powder was prepared from Aloe vera leaf gel according to the published procedure with slight modifications [18]. Mature, healthy and fresh leaves of Aloe vera having a length of approximately 75 to 90 cm were washed with fresh water. The leaves were cut transversely into pieces. The thick epidermis was selectively removed. The solid gel in the center of the leaf was homogenized. The resulting mucilaginous, thick and straw colored homogenate was lyophilized. Then the lyophilized sample was extracted using 95 % ethanol. The filtrate was collected and evaporated to dryness under reduced pressure in a rotary evaporator. The residue was stored in dry sterilized small containers at 4 °C until further use. An aqueous suspension was prepared by dissolving suitable amount of ethanol free extract of Aloe vera leaf gel to get the concentration of 200 mg/kg.

Preparation of Chitosan Nanoparticle Thin-Film Membranes

The chitosan nanoparticles were prepared based on a procedure described by others [19]. A 2.5 mg/mL chitosan solution was prepared by dissolving low molecular weight or very low molecular weight chitosan in a 0.05% (v/v) acetic acid solution and leaving it under stirring for 24 h. The pH was adjusted to 5.5 with a 0.5 M sodium hydroxide solution and diluted in deionized water to the final desired concentrations. The tripolyphosphate (TPP) was dissolved in deionized water to a final concentration of 0.25 mg/mL. TPP and chitosan solutions were filtered through a 0.45 μ m membrane (Millipore). Then, the TPP solution was added to the chitosan solution drop wise (0.3 mL/min) at different TPP: chitosan ratios under vigorous magnetic stirring at room temperature. The resulting suspension was dissolved in 100 mL of 1% acetic acid and stirred for 24 h at room temperature. The obtained solution was then filtered through G4 sand filter in order to remove the impurities and no dissolved particles. The prepared plain polysulfone (PSf/TiO₂) membrane (100 cm²) was pasted on the glass plate separately using tape with thickness of 1 mm. The stuck membrane was washed with distilled water

and wiped with smooth tissue paper. A thin film of saturated polyvinyl alcohol solution was brush coated on the substrate. Chitosan (30 mL) was slowly poured in the center of the substrate and spread evenly throughout the substrate. Further, the thin film was dried at 60 °C for 4 h in a hot air oven. After drying, the membrane was allowed to reach room temperature, and was then washed with 1% NaOH to remove excess acetic acid. Finally, the membrane was washed with distilled water until the washed water reached neutral pH. The same was repeated for bare PSf membranes [20]. The obtained membranes were used to dress the wounds.

Study Design

The rats were randomly selected and allocated into five groups of six rats each. A power calculation based on earlier studies suggested that 6 animals in each group would be sufficient to detect a statistically significant difference in bacterial count, which was the primary outcome in this study. Group I: Animals with uninfected wounds treated with 0.9% saline solution. Group II: Animals with infected wounds treated with saline. Group III: Animals with infected wounds were dressed with chitosan nanoparticle thin-film membranes. Group IV: Animals with infected wounds were treated topically with Aloe vera and Group V: Animals with infected wounds were treated topically with Aloe vera and dressed with chitosan nanoparticle thin-film membranes.

The Procedures for Wound Creation and Infection

Rats were anesthetized by an intraperitoneal injection of ketamine (70 mg/kg of b. w.) and xylazine (5mg/kg of b. w.), the hair on their back was shaved and the skin cleansed with 70% alcohol solution. Following shaving and aseptic preparation, a circular excision wound was made by cutting away approximately 300 mm² full thickness of predetermined area on the anterior-dorsal side of each rat. Small gauze was placed over each wound and then inoculated with 5×10⁷ CFU of *Staphylococcus aureus* ATCC 43300, The methicillin-resistant *S. aureus* ATCC 43300 strain was commercially available. The pocket was closed by means of 4-0 nylon sutures and this procedure resulted in a local abscess after 24 h. The rats were returned to individual cages and they were examined daily. After 24 h, the wounds were opened, the gauze removed for quantitative bacterial cultures and treatment started. Postoperative pain was controlled using meperidine (Hameln, Germany), 10 mg/kg were injected subcutaneously once daily for three days.

Animal Grouping

In group I, the sterile saline 0.9% solution was added to the uninfected wounds. In group II, the animals with infected wound were only treated with saline solution. In group III, animals with infected wounds were dressed with chitosan nanoparticle

thin-film membranes. In group IV, the animals with infected wounds had topical Aloe vera gel application once daily at a concentration of 200 mg/kg on the created wound. In group V, the animals with infected wounds had topical Aloe vera gel application once daily at a concentration of 200 mg/kg on the created wound and were dressed with chitosan nanoparticle thin-film membranes. All the test formulations were applied for 7 days starting from the day of wounding.

Microbiological Examination

At the end of 6th day of treatment, a sample tissue was taken from each wound, homogenized, weighed and 1:4 wt/vol dilutions were made with sterile 0.9% saline. Quantization of viable bacteria was performed by culturing ten-fold dilutions of each sample. 0.1 ml of the bacterial suspension from each group was put in sterile blood agar flat bottom plates. All plates were incubated at 37°C for 48 h and evaluated for the presence of the *Staphylococcal* strain. The number of colony-forming units/g (CFUs/g) of tissue homogenate was used to express the colonization.

Excision Wound Model and Planimetric Studies

Wound-healing property was evaluated by wound contraction percentage and wound closure time. Photographs were taken immediately after wounding and on days 6, 9, 12, 15, 18 and 21 post-operation by a digital camera while a ruler was placed near the wounds. The wound areas were analyzed by Measuring Tool of Adobe Acrobat 9 Pro Extended software (Adobe Systems Inc, San Jose, CA, USA) and wound contraction percentage was calculated using the following formula: Percentage of wound contraction = $(A_0 - A_t) / A_0 \times 100$

Where A_0 is the original wound area and A_t is the wound area at the time of imaging [30]. The animals were left in separate cages for four days at room conditions for acclimatization. Animal houses were in standard environmental conditions of temperature (22±3°C), humidity (60±5%), and a 12h light/dark cycle. The animals were maintained on standard pellet diet and tap water. All rats were closely observed for any infection and if they showed signs of infection were separated, excluded from the study and replaced.

Determination of Hydroxyproline Levels

On the day 21 after surgery, a piece of skin from the healed wound area was collected and analyzed for hydroxyproline content. As a major part of collagen, hydroxyproline has an essential role in collagen stability. The collagen is the major component of extracellular tissue, which gives support and strength. The hydroxyproline contents were estimated using a method described by others [21]. Briefly, tissues were dried in a hot air oven at 60–70°C to constant weight and were hydrolyzed in 6N HCl at 130°C for 4 h in sealed tubes. The hydrolysate was neutralized to pH 7.0 and was subjected to chloramine-T oxidation for

20 min. The reaction was terminated by addition of 0.4M perchloric acid and color was developed with the help of Ehrlich reagent at 60°C and measured at 557 nm using UV-visible spectrophotometer (CamSpec M330, Cambridge CB2 4BG, UK).

Histological Preparation and Quantitative Morphometric Studies

The tissue samples were taken on 7, 14, 21 days after surgery from periphery of the wound along with normal skin and fixed in 10% buffered formalin, dehydrated and embedded in paraffin wax, sectioned at 5 µm and stained with hematoxylin and eosin (H&E) and Masson's trichrome stains. Photomicrographs were obtained under light microscope to assess the predominant stage of wound healing. Three parallel sections were obtained from each specimen. Cellular infiltration including the number of mononuclear cells, poly morphonuclear cells and fibroblastic aggregation were quantitatively evaluated. Acute hemorrhage, congestion, vascularization, epithelialization, collagen production and density were also evaluated qualitatively. Morphological findings were scored using image analyzing software (Image-Pro Express, version 6.0.0.319, Media Cybernetics, Silver Springs, MD, USA). The histological parameters were classified according to the intensity of occurrence in five levels (- absence; + discrete; ++ moderate; +++ intense; +++++ very intense).

Statistical Analysis

Differences among groups in excisional model, hydroxyproline level test were evaluated by Kruskal–Wallis variance analysis. When the P-value from the Kruskal–Wallis test statistics was statistically significant, multiple comparison tests were used to know differences. Student's t-test was used for evaluation of mechanical test results. Comparison among days was assessed by Mann–Whitney U-test. The Bonferroni correction was applied for all possible multiple comparisons. SPSS 11.5 (SPSS Inc., Chicago, IL, USA) was used for statistical analysis. A *p*-value was set at 0.05.

Results

Microbiological Examination

No animals died due to infection or anesthetics. The

culture at 24 h after wounds inoculation of groups II and IV rats with MRSA showed CFU/g count >1.000. On the 6th day, the uninfected wounds treated with saline had no CFU/g of *S. aureus* count. In animals of group II whose infected wounds were treated with saline, the counts of *S. aureus* cultured in the wound tissues were significantly higher than in the infected wounds of groups IV and V (*p*<0.05). In animals of group V whose infected wounds were treated with both Aloe vera gel and chitosan nanoparticle thin-film membranes, the counts of *S. aureus* cultured in the wound tissues were significantly lower than in the infected wounds of group IV (*p*<0.05) (Table 1).

Table 1. Wound bacterial count in experimental groups.

Groups	Wound bacterial count (CFU ^a /g)
I	0.00±0.00
II	1334.54±216.73
III	212.78±24.15
IV	282.65±37.64
V	176.89±42.19 ^b

^aCFU: Colony-forming units; ^b*p*<0.05 vs other experimental groups

Reduction in Wound Area

Wound contraction percentage in different groups during the course of study is shown in Table 2. The healing rate of wounds in group V was significantly different compared to the control group (*p*<0.05).

Hydroxyproline Content of Wound

Proline is hydroxylated to form hydroxyproline after protein synthesis. Hydroxyproline contents in the groups I to V were found to be 48.77±2.24, 61.58±2.54, 71.37±3.26, 79.65±3.24 and 88.54±3.76 mg g⁻¹, respectively. Hydroxyproline contents were increased significantly in the group V which implies more collagen deposition compared to other experimental groups (*p*<0.05).

Histological and Morphometric Findings

There were significant differences in comparisons of group V and other groups, particularly in terms of cellular infiltration, acute hemorrhage, congestion, edema, collagen production and density, reepithelialisation and neovascularization. During the study period, scores for reepithelialisation and neovascularisation were significantly higher

Table 2. Effect of of Aloe vera and/or chitosan nanoparticle thin-film membranes on circular excision wound contraction area (mm²). Values are given as mean±SEM.

Groups	Wound area in days (mm ²)					
	Day 6	Day 9	Day 12	Day 15	Day 18	Day 21
I	253.75±0.93	103.45±1.58	87.75±0.63	44.76±1.30	23.23±1.19	7.81±0.32
II	254.12±0.64	201.87±1.15	188.12±0.20	145.78±1.92	97.63±1.15	76.11±1.23
III	207.22±1.19	135.54±1.77	107.08±0.09	88.53±0.98	53.19±1.05	24.68±1.37
IV	217.18±1.21	165.45±1.72	123.54±1.34	102.65±0.28	67.11±1.15	31.17±1.30
V	154.52±1.30 ^a	112.29±0.35 ^a	79.45±0.18 ^a	34.73±0.17 ^a	15.32±0.53 ^a	4.76±0.84 ^a

The treated groups are compared by Student t test with other groups. ^a: The mean difference is significant at the 0.05 level vs other experimental groups.

in group V rats than other groups ($p<0.05$). Polymorphonuclear (PMN) and mononuclear (MNC) cell count, fibroblast cell proliferation and also Mean Rank of the qualitative study of acute hemorrhage, edema and collagen production score in group V were significantly higher than those of other experimental groups ($p<0.05$) (Table 3) (Figures 1-4).

Discussion

Inflammation, proliferation and tissue remodeling are three phases of healing process which occur following tissue damages as closely as possible to its natural state. The healing process is activated when platelets come into contact with exposed collagen leading to platelet aggregation and the release of clotting factors resulting in the deposition of a fibrin clot at the site of injury. The fibrin clot serves as a provisional matrix and sets the stage for the subsequent events of healing. Inflammatory cells

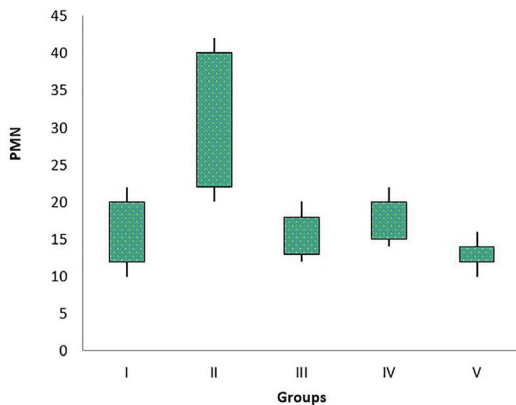


Fig. 1. Box-and-whisker plots of number of polymorphnuclear cells (PMN) in excisional model of the rat's skin in experimental groups. Results were expressed as mean±SEM.

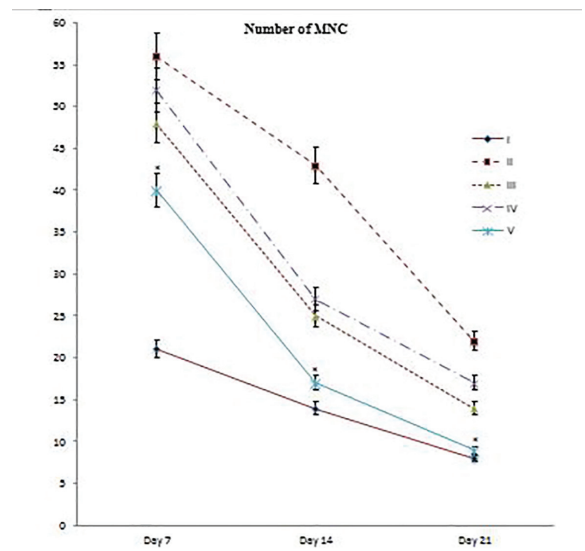


Fig. 2. Line graph indicating number of mononuclear cells (MNC) in excisional model of the rat's skin in experimental groups. Results were expressed as mean±SEM. * $p<0.05$ vs other experimental groups.

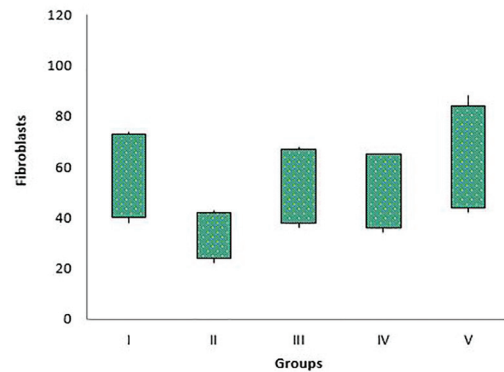


Fig. 3. Box-and-whisker plots of number of fibroblasts in excisional model of the rat's skin in experimental groups. Results were expressed as mean±SEM.

Table 3. Intensity of histological parameters assessed in experimental animals.

Groups	Days	Histological parameters				
		Acute Hemorrhage	Congestion	Vascularization	Epithelialization	Collagen
I	7	+++	++++	+	-	+
	14	++	+	++	+	++
	21	-	-	+++	++	++
II	7	++++	++++	-	-	-
	14	+++	+++	+	+	+
III	7	++	+++	++	+	++
	14	+	-	+++	++	+++
	21	-	-	+++	+++	+++
IV	7	++	++	++	-	+
	14	+	-	+++	+	++
	21	-	-	+++	++	+++
V	7	+ ^a	+ ^a	+++ ^a	++ ^a	++ ^a
	14	-	-	++++ ^a	+++ ^a	+++ ^a
	21	-	-	++++ ^a	++++ ^a	++++ ^a

Classification of histological parameters according to the intensity of occurrence: - absence; + discrete; ++ moderate; +++ intense; ++++ very intense. Histopathological damages were assessed as explained under material and methods on days, 7, 14 and 21 of lesion.

^a $p<0.05$ vs other experimental groups.

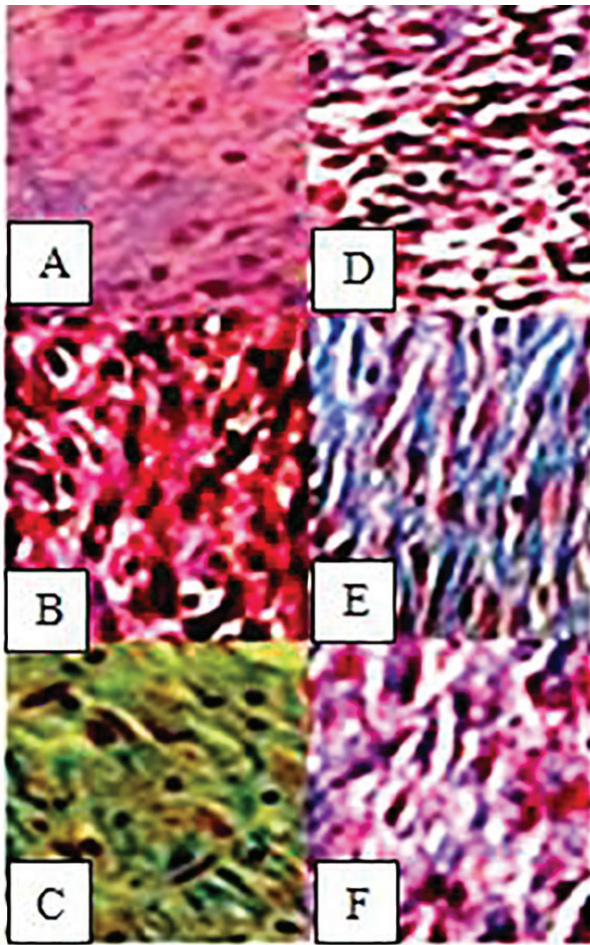


Fig. 4. Histological characteristics of rat skin on the 7th (A-C) and 14th day (D-F) after wound creation in excisional wound model. A and D: III, B and E: IV, C and F: V. Wounds with surrounding skin were prepared for histological microscopic evaluation by Masson trichrome staining. ($\times 400$)

also arrive along with the platelets at the injury site providing key signals known as growth factors. The fibroblast is the connective tissue cell responsible for collagen deposition required to repair the tissue injury. The collagen is the main constituent of extra cellular tissue, which is responsible for support and strength [22].

Nanoparticles have become significant in the regenerative medicine field in the last two decades [23]. Many biological processes happen at through mechanisms that fundamentally act at the nanometer scale. Thus, materials such as NPs can be used as unique tools for drug delivery, imaging, sensing, and probing biological processes [24]. In the context of wound healing, the special properties of NPs like electric conductivity, antimicrobial activity, and high surface to volume ratio, swelling, and contraction make NPs versatile resources.

Several reports have demonstrated that there is a beneficial effect of chitosan as a biologically active dressing in wound management. It has been reported that the application of chitosan to the open wounds in dogs induced exudate, which has a high growth factor activity, and induced infiltration by inflammatory

cells and granulation tissue formation accompanied by angiogenesis [25,26]. Chitosan-membrane-based wound products have been investigated both in laboratory animals and humans, however, are still at the early stages of development. Since 1980, chitosan and its derivatives have been used in skin and wound management products in Japan. Beschitin W, an artificial skin prepared from chitin threads, has been developed for human use and is on the market [27,28]. Chitosan microspheres have been demonstrated to bear robust antimicrobial activity against *S. aureus* [29].

We selected chitosan as a dressing material due to its biocompatibility, biodegradability, haemostatic activity, anti-inflammatory activity and property to accelerate wound healing [30]. The N-acetyl glucosamine (NAG) present in chitin and chitosan is a major component of dermal tissue which is essential for repair of scar tissue. Its positive surface charge enables it to effectively support cell growth and promotes surface induced thrombosis and blood coagulation. Free amino groups which are present on the chitosan membrane surface may form polyelectrolyte complexes with acidic groups of the cellular elements of blood [30]. It has several advantages over other type of disinfectants because it possesses a higher antimicrobial activity, a broader spectrum of activity, a higher killing rate and a lower toxicity toward mammalian cells. However, synthetic polymers are available at a lower price than biopolymer chitosan, substitution of chitosan by these synthetic polymers could reduce the price of chitosan-based films with safe effect on their functionality [30].

Aloe Vera is one of the pharmaceutical herbs belonging to the liliaceae family. It has been used in the treatment of a variety of disorders including infections dermatologic conditions and used as a laxative since ancient times. This plant has long meaty thick leaves with twisted sides which end in thorns [31]. The substance inside the leaf called gel consists of 99% water with long chain polysaccharide, of Acetylated glucoannan kind, and other carbohydrates. It also contains the complex of Amino Acids, salisilic Acid, Ascorbic Acid, Vit A, and Vit E with anti-oxidant properties [32]. This gel prevents skin dryness due to the high volume of water. The high percentage of glucose present in gel prevents bacterial growth due to the high osmotic virtue [33]. Prostaglandin and bradykinin hydrolyzing enzymes in Aloe Vera reduce pain and inflammation. The existence of amylase enzyme in Aloe annihilated the necrosal tissue, aloctin-A, which has a cell division and mitosis effect and causes the acceleration in healing and stimulating macrophage to excrete the dead tissue. Amino Acids present in plant gel are used to produce protein, causing tissue growth and healing. Vitamins including β -carotene, Vit E, Vit C, and B complex, used in cell reaction, are consumed as antioxidants in strengthening the

body immune system [34]. Plant juice, antrakinons with anti-microbial, antiviral, antifungal, and anti-inflammatory properties and the saponins with antiseptic properties are effective in preventing infections [35].

In excisional wound model there was a significant decrease in wound area in aloe vera and/or chitosan treated animals. This indicated improved collagen maturation by increased cross linking. The balance between synthesis and breakdown and so deposition of collagen is important in wound healing and development of wound strength [36]. Hydroxyproline is a major component of the collagen that permits the sharp twisting of the collagen helix. It helps on providing stability to the triple-helical structure of collagen by forming hydrogen bonds. Hydroxyproline is found in few proteins other than collagen. For this reason, hydroxyproline content has been used as an indicator to determine collagen content [37]. Increase in hydroxyproline content in group V indicated increased collagen content, since hydroxyproline is the direct estimate of collagen synthesis. Mechanical testing is sensitive to changes that occur during the progression of wound healing, and can be used as a tool to measure the quality of healing.

Biomaterials derived from natural products can provide materials with greater complexity and composition. In order to mimic the extracellular matrix (ECM) conditions of the wound and to provide a scaffold for the fibroblasts for collagen deposition, ECM-based therapies have gained popularity [38]. A phase I clinical trial using fibroin to enhance wound healing is currently underway. Finally, there have

been numerous marine polysaccharide hydrogels like marine collagen from *Stomolophus nomurai* meleagris, *Oncorhynchus keta*, *Lates calcarifer*, *Stichopus japonicas*, and *Salmo salar*, alginate from *Macrocystis pyrifera*, chitosan from crabs and shrimps, which are bioactive and increase wound healing rates in mice [39].

In the present study, histopathological examination and scoring revealed that there was a significant difference by means of wound healing scores in group V compared to other experimental groups. Aloe vera with chitosan nanoparticle thin-film membranes decreased the maturation time of granulation tissue and wound contraction which means that it enhanced reepithelialisation with significant effect on inflammatory infiltration and number of fibroblasts in time-dependent activity.

Aloe vera with chitosan nanoparticle thin-film membranes resulted in significant improvement of full thickness wound healing. Thus, from this study we concluded that the Aloe vera with chitosan nanoparticle thin-film membranes have a reproducible wound healing potential and hereby justifies its use in practice.

Acknowledgments

We would like to thank from the Clinical Research Developmental Center of Baqiyatallah hospital for their kindly cooperation. This study was financially supported in part by Clinical Research Developmental Center of Baqiyatallah hospital.

Conflicts of Interest: None declared.

References

- Cotran R, Kumar V, Collins T, Robbins SL. Pathologic basis of disease. 6th ed. Philadelphia: Saunders. 1999.
- Rajan S. Skin and soft-tissue infections: classifying and treating a spectrum. *Cleve Clin J Med*. 2012;**79**(1):57-66.
- Zetola N, Francis JS, Nuermberger EL, Bishai WR. Community-acquired methicillin-resistant *Staphylococcus aureus*: an emerging threat. *Lancet Infect Dis*. 2005;**5**(5):275-86.
- Ranjbar R, Takhtfooladi MA. The effects of low level laser therapy on *Staphylococcus aureus* infected third-degree burns in diabetic rats. *Acta Cir Bras*. 2016;**31**(4):250-5.
- Ranjbar R, Takhtfooladi MA. The effects of photobiomodulation therapy on *Staphylococcus aureus* infected surgical wounds in diabetic rats. A microbiological, histopathological, and biomechanical study. *Acta Cir Bras*. 2016;**31**(8):498-504.
- Moghaddasi MS. Aloe vera chemicals and usages. *Advances in Environmental Biology*. 2010:464-9.
- Sharrif Moghaddasi M. Aloe vera their chemicals composition and applications: A review. *Int J Biol Med Res*. 2011;**2**(1):466-71.
- Kumar KS, Debjit B. Aloe vera: a potential herb and its medicinal importance. *Journal of chemical and Pharmaceutical Research*. 2010;**2**(1):21-9.
- Hamid AAA, Soliman MF. Effect of topical aloe vera on the process of healing of full-thickness skin burn: a histological and immunohistochemical study. *Journal of Histology & Histopathology*. 2015;**2**(1):3.
- Kemper KJ, Chiou V. Aloe vera (Aloe vera). Longwood Herbal Task Force. (1999). Available from: <http://www.mcp.edu/herbal/default.htm>.
- Alemdar S, Agaoglu S. Investigation of in vitro antimicrobial activity of Aloe vera juice. *J Anim Vet Adv*. 2009;**8**(1):99-102.
- Hu Y, Xu J, Hu Q. Evaluation of antioxidant potential of aloe vera (*Aloe barbadensis miller*) extracts. *J Agric Food Chem*. 2003;**51**(26):7788-91.
- Sinha VR, Singla AK, Wadhawan S, Kaushik R, Kumria R, Bansal K, et al. Chitosan microspheres as a potential carrier for drugs. *Int J Pharm*. 2004;**274**(1-2):1-33.
- No HK, Park NY, Lee SH, Meyers SP. Antibacterial activity of chitosans and chitosan oligomers with different molecular weights. *Int J Food Microbiol*. 2002;**74**(1-2):65-72.
- Kishen A, Shi Z, Shrestha A, Neoh KG. An investigation on the antibacterial and antibiofilm efficacy of cationic nanoparticulates for root canal disinfection. *J Endod*. 2008;**34**(12):1515-20.
- Silva PV, Guedes DF, Nakadi FV, Pecora JD, Cruz-Filho AM. Chitosan: a new solution for removal of smear layer after root canal instrumentation.

- Int Endod J.* 2013;**46**(4):332-8.
17. Calamari SE, Bojanich MA, Barembaum SR, Berdicevski N, Azcurra AI. Antifungal and post-antifungal effects of chlorhexidine, fluconazole, chitosan and its combinations on *Candida albicans*. *Med Oral Patol Oral Cir Bucal.* 2011;**16**(1):e23-8.
 18. Rajasekaran S, Sivagnanam K, Subramanian S. Antioxidant effect of Aloe vera gel extract in streptozotocin-induced diabetes in rats. *Pharmacol Rep.* 2005;**57**(1):90-6.
 19. Rampino A, Borgogna M, Blasi P, Bellich B, Cesaro A. Chitosan nanoparticles: preparation, size evolution and stability. *Int J Pharm.* 2013;**455**(1-2):219-28.
 20. Nayak V, Jyothi MS, Balakrishna RG, Padaki M, Ismail AF. Preparation and Characterization of Chitosan Thin Films on Mixed-Matrix Membranes for Complete Removal of Chromium. *ChemistryOpen.* 2015;**4**(3):278-87.
 21. Qiu Z, Kwon AH, Kamiyama Y. Effects of plasma fibronectin on the healing of full-thickness skin wounds in streptozotocin-induced diabetic rats. *J Surg Res.* 2007;**138**(1):64-70.
 22. Martin JM, Zenilman JM, Lazarus GS. Molecular microbiology: new dimensions for cutaneous biology and wound healing. *J Invest Dermatol.* 2010;**130**(1):38-48.
 23. McLaughlin S, Podrebarac J, Ruel M, Suuronen EJ, McNeill B, Alarcon EI. Nano-Engineered Biomaterials for Tissue Regeneration: What Has Been Achieved So Far? *Frontiers in Materials.* 2016;**3**:27.
 24. Wang EC, Wang AZ. Nanoparticles and their applications in cell and molecular biology. *Integr Biol (Camb).* 2014;**6**(1):9-26.
 25. Okamoto Y, Shibazaki K, Minami S, Matsuhashi A, Tanioka S, Shigemasa Y. Evaluation of chitin and chitosan on open wound healing in dogs. *J Vet Med Sci.* 1995;**57**(5):851-4.
 26. Mizuno K, Yamamura K, Yano K, Osada T, Saeki S, Takimoto N, et al. Effect of chitosan film containing basic fibroblast growth factor on wound healing in genetically diabetic mice. *J Biomed Mater Res A.* 2003;**64**(1):177-81.
 27. Koji k. Advances in chitin and chitosan. Edited by C. J. Brine, P. A. Sandford and J. P. Zikakis. Elsevier Science Publishers: London; 1992. P. 9-15.
 28. Azad AK, Sermsintham N, Chandkrachang S, Stevens WF. Chitosan membrane as a wound-healing dressing: characterization and clinical application. *J Biomed Mater Res B Appl Biomater.* 2004;**69**(2):216-22.
 29. Seetharaman S, Natesan S, Stowers RS, Mullens C, Baer DG, Suggs LJ, et al. A PEGylated fibrin-based wound dressing with antimicrobial and angiogenic activity. *Acta Biomater.* 2011;**7**(7):2787-96.
 30. Archana D, Dutta J, Dutta PK. Evaluation of chitosan nano dressing for wound healing: characterization, in vitro and in vivo studies. *Int J Biol Macromol.* 2013;**57**:193-203.
 31. Hegggers JP, Pelley RP, Robson MC. Beneficial effects of Aloe in wound healing. *Phytotherapy research.* 1993;**7**(7).
 32. Chithra P, Sajithlal GB, Chandrakasan G. Influence of aloe vera on the healing of dermal wounds in diabetic rats. *J Ethnopharmacol.* 1998;**59**(3):195-201.
 33. Adzick N. Wound healing: biologic and clinical features. Textbook of surgery. The biological basis of modern surgical practice, 15th edn. Saunders: Philadelphia; 1997. P. 207-20.
 34. Vázquez B, Avila G, Segura D, Escalante B. Antiinflammatory activity of extracts from Aloe vera gel. *Journal of ethnopharmacology.* 1996;**55**(1):69-75.
 35. Kumar P, Jagetia GC. Modulation of wound healing in Swiss albino mice by different doses of gamma radiation. *Burns.* 1995;**21**(3):163-5.
 36. Dogan S, Demirer S, Kepenekci I, Erkek B, Kiziltay A, Hasirci N, et al. Epidermal growth factor-containing wound closure enhances wound healing in non-diabetic and diabetic rats. *Int Wound J.* 2009;**6**(2):107-15.
 37. Martin JM, Zenilman JM, Lazarus GS. Molecular microbiology: new dimensions for cutaneous biology and wound healing. *J Invest Dermatol.* 2010;**130**(1):38-48.
 38. Das S, Baker AB. Biomaterials and Nanotherapeutics for Enhancing Skin Wound Healing. *Front Bioeng Biotechnol.* 2016;**4**:82.
 39. Chandika P, Ko SC, Jung WK. Marine-derived biological macromolecule-based biomaterials for wound healing and skin tissue regeneration. *Int J Biol Macromol.* 2015;**77**:24-35.