

Visual Outcomes of Successful versus Failed Big-Bubble Deep Anterior Lamellar Keratoplasty for Keratoconus

Mohammad Ali Javadi¹, MD; Hossein Mohammad-Rabei¹, MD; Sepehr Feizi², MD, MS; Seyed-Hashem Daryabari³, MD

¹Ophthalmic Research Center, Shahid Beheshti University of Medical Sciences, Tehran, Iran

²Ocular Tissue Engineering Research Center, Shahid Beheshti University of Medical Sciences, Tehran, Iran

³Department of Ophthalmology, Baqiyatallah University of Medical Sciences, Tehran, Iran

Abstract

Purpose: To compare the visual outcomes of deep anterior lamellar keratoplasty (DALK) for keratoconus with and without successful big-bubble formation.

Methods: In this retrospective comparative study, a total of 289 consecutive eyes from 257 patients underwent DALK using the big-bubble technique. In cases where the big bubble could not be accomplished, manual stromal dissection down to Descemet membrane (DM) was performed using a crescent knife. Visual acuity and refractive outcomes were compared between the bare DM group (Group 1) and manual dissection group (Group 2).

Results: A bare DM was successfully achieved in 229 (79.2%) eyes and manual dissection was performed in 60 (20.8%) eyes. The study groups were comparable in terms of age ($P = 0.79$), preoperative best-spectacle corrected visual acuity (BSCVA) ($P = 0.15$), and follow-up duration ($P = 0.73$). Postoperative BSCVA was significantly better in Group 1 than in Group 2 throughout follow-up ($P < 0.05$). In Group 2, BSCVA was significantly lower in eyes with advanced keratoconus as compared to those with moderate keratoconus ($P = 0.007$). At final follow-up, BSCVA ≤ 0.30 logarithm of minimum angle of resolution (logMAR) was achieved in 82.1% of eyes in Group 1 versus 54.5% of eyes in Group 2 ($P < 0.001$). Groups 1 and 2 were comparable in terms of postoperative spherical equivalent refractive error ($P = 0.61$) and keratometric astigmatism ($P = 0.39$).

Conclusion: Retention of the posterior corneal stroma which occurs with manual dissection during failed big bubble formation in DALK is associated with lower visual acuity as compared to achieving a bare DM.

Keywords: Big-Bubble Technique; Deep Anterior Lamellar Keratoplasty; Keratoconus; Success Rate; Visual Acuity

J Ophthalmic Vis Res 2016; 11 (1): 32-36.

INTRODUCTION

Deep anterior lamellar keratoplasty (DALK) in keratoconus (KCN) aims to replace the affected corneal

stroma while preserving the healthy host endothelium; this procedure eliminates the risk of endothelial graft rejection and has minimal effect on endothelial cell counts.^[1,2] Different techniques have been described to perform DALK including direct open dissection,^[3] intrastromal air injection,^[4] hydrodelamination^[5] and viscoelastic dissection.^[6]

The big-bubble technique, described by Anwar and Teichmann,^[7] facilitates separation of the corneal stroma from Descemet's membrane (DM) by means of air

Correspondence to:

Mohammad Ali Javadi, MD. Ophthalmic Research Center, Shahid Beheshti University of Medical Sciences, No. 23, Pajouhgar St., Boostan 9 St., Pasdaran Ave., Tehran 16666, Iran.

E-mail: ma_javadi@yahoo.com

Received: 12-05-2015

Accepted: 29-08-2015

Access this article online

Quick Response Code:



Website:

www.jovr.org

DOI:

10.4103/2008-322X.180711

This is an open access article distributed under the terms of the Creative Commons Attribution-NonCommercial-ShareAlike 3.0 License, which allows others to remix, tweak, and build upon the work non-commercially, as long as the author is credited and the new creations are licensed under the identical terms.

For reprints contact: reprints@medknow.com

How to cite this article: Javadi MA, Mohammad-Rabei H, Feizi S, Daryabari SH. Visual outcomes of successful versus failed big-bubble deep anterior lamellar keratoplasty for keratoconus. *J Ophthalmic Vis Res* 2016;11:32-6.

injection into the deep stroma. Although this technique is reproducible and rates of successful big-bubble formation as high as 80%-90% have been reported,^[7-9] it has a steep learning curve and success rates can be much lower for beginning surgeons.^[8-14]

When the big bubble is not obtained firsthand, the procedure can be converted into air-assisted manual dissection, allowing successful completion of the DALK procedure. With this approach, a variable amount of deep stroma is often left behind. Whether the visual outcomes are comparable between these two techniques is an unsettled debate. Several studies have reported that eyes with bare DM have better visual acuity.^[9,11,15-19] On the other hand, some studies reported no significant difference in visual acuity outcomes between eyes with bare DM and those with remaining corneal stroma.^[10,13,14,20,21]

The present study was conducted on a large series of keratoconus patients and compares the outcomes of DALK performed using the big-bubble technique with a bare DM achieved with those where the big bubble was unsuccessful, necessitating manual dissection to complete the procedure.

METHODS

In this retrospective, non-randomized, comparative study, data of consecutive patients undergoing DALK for moderate (mean keratometry, 48-55 D) to advanced (mean keratometry \geq 55 D or immeasurable keratometry) keratoconus between January 2004 and February 2013 were compiled. Ethics committee approval was obtained to use patients' data.

Keratoconus was diagnosed clinically, based on slit lamp findings (stromal thinning, Fleischer ring, and Vogt's striae) and keratometry, and confirmed by elevation topography (Orbscan II system, Bausch and Lomb, Rochester, New York, USA). Preoperatively, there were no concomitant ocular disorders such as cataract, glaucoma and retinal abnormalities in any participant. Additionally, no deep stromal scar or defect in DM indicating previous hydrops was observed. A complete preoperative ocular examination was performed, including determination of uncorrected visual acuity (UCVA) and best-spectacle corrected visual acuity (BSCVA) using the Snellen acuity chart, slit lamp examination, tonometry, dilated fundus examination and manifest refraction (when possible).

All eyes were operated by a single experienced anterior segment surgeon (MAJ) under general anesthesia using the big-bubble technique as described in detail elsewhere.^[10] Trephination size was chosen according to the size of the cone and vertical corneal diameter. After trephination to approximately 80% of peripheral corneal thickness using a Hessburg-

essbur suction trephine (Katena, Denville, NJ, USA), a 27-gauge needle was inserted into the stroma up to the center of the cornea. Air was gently injected into the mid stroma until a big bubble was formed extending to the border of trephination (Group 1). If the big bubble was not formed after the first attempt, the injection was repeated. After big-bubble formation, debulking of the anterior two-thirds of the corneal stroma was performed using a crescent blade (Alcon Laboratories, Fort Worth, TX, USA). Thereafter, a peripheral paracentesis was done to reduce intraocular pressure, and the bubble was punctured with a 15-degree slit knife (Alcon Laboratories, Fort Worth, TX, USA). Viscoelastic material (Coatel; Bausch and Lomb, Waterford, Ireland) was injected to keep DM away from manipulation, and the rest of the corneal stroma was completely excised. The viscoelastic material was then completely washed out before proceeding to graft suturing.

In cases where a big bubble could not be accomplished after several attempts, manual stromal dissection down to DM was progressively performed using a crescent knife (Group 2). It was attempted to remove as much corneal stroma as possible and create a smooth recipient bed with uniform thickness.

In both groups, a donor cornea, oversized by 0.25 mm, devoid of DM and endothelium was punched from the endothelial side using the Barron punch (Katena, Denville, NJ, USA) and sutured to the recipient bed using the combined suturing technique, consisting of a 16-bite single running and an 8 interrupted 10/0 nylon sutures (Sharpoint; Angiotech, Vancouver, Canada). If the procedure was complicated with an extensive tear in the DM, DALK surgery was converted to penetrating keratoplasty (PK).

Postoperatively, BSCVA (expressed in logarithm of minimum angle of resolution [logMAR] notations), manifest refraction and keratometric astigmatism were measured 1, 3, 6 and 12 months after the procedure, 3 months after complete suture removal, and every 6 months thereafter. Selective interrupted suture removal was started 2 months after the operation based on keratometric astigmatism. Suture removal was continued until an acceptable amount of astigmatism was achieved. The rest of the sutures were left in place until they seemed to be ineffective or loose. All sutures had been removed by the time of final examination.

Data were analyzed using SPSS statistical software version 21 (IBM Corp., Armonk, NY, USA). The normal distribution of continuous variables was verified using a Kolmogorov-Smirnov test and a Q-Q plot. Comparisons between the study groups were performed using *t*-test and Mann-Whitney test for normal, and non-normal continuous and ordinal variables, respectively. Nominal variables were compared using the Chi-square or

Fisher's exact test, where appropriate. P values <0.05 were considered as statistically significant. All reported P values are 2-sided.

RESULTS

A total of 290 consecutive (including 153 right) eyes from 257 (consisting of 179 male) patients with keratoconus were operated during the study period. DALK was successfully completed in 289 eyes, but the procedure was converted into PK in one eye due to a large DM tear during corneal trephination. This eye was excluded from data analysis.

Of 289 eyes, a bare DM was successfully achieved in 229 eyes (79.2%; group 1), whereas in the 60 remaining eyes (20.8%; group 2), layer-by-layer manual stromal dissection was performed to reach pre-Descemet level. The study groups were comparable in terms of age (27.8 ± 7.9 versus 27.5 ± 8.5 years in Groups 1 and 2, respectively, $P = 0.79$) and duration of follow-up (38.4 ± 20.4 versus 37.4 ± 19.9 months, in Groups 1 and 2, respectively, $P = 0.73$).

Preoperative BSCVA was 1.28 ± 0.49 (range, 0.18-2.40) logMAR in Group 1 versus 1.31 ± 0.51 (range, 0.18-2.10) logMAR in Group 2 ($P = 0.15$). Groups 1 and 2 were comparable in terms of preoperative spherical equivalent refractive error [-10.23 ± 3.31 (range, -3.75 to -16.75) D vs. -12.18 ± 3.66 (range, -6.0 to -18.13) D, respectively; $P = 0.13$], mean keratometry [56.07 ± 5.88 (range, 46.25-65.0) D vs. 57.52 ± 5.75 (49.25-65.0) D, respectively; $P = 0.16$], and keratometric astigmatism [5.59 ± 2.94 (range, 0.50-13.5) D vs. 4.86 ± 2.63 (0.50-10.50) D, respectively; $P = 0.23$].

Visual acuity and refractive error were measured in all participants (100%) 1, 3, 6, and 12 months postoperatively. In the bare DM group, such measurements were obtained in 162 (70.7%), 148 (64.6%), 119 (52.0%), 79 (34.5%), 53 (23.1%), and 39 (17.0%) eyes at 1.5, 2, 3, 4, 5, and 6 years, respectively. In the manual dissection group, corresponding figures were 45 (75.0%), 33 (55.0%), 24 (40.0%), 30 (50.0%), 15 (25.0%), and 11 (18.3%), respectively. Postoperative BSCVA was significantly better in Group 1 than in Group 2 at all postoperative time points [Figure 1]. As demonstrated in Figure 1, visual acuity stabilized 12 months after surgery in Group 1, while Group 2 had more fluctuations during the follow-up period.

BSCVA ≤ 0.30 logMAR (20/40 or better) was achieved in 84.3%, 84.1%, 89.9%, 84.9%, 86.1%, 79.2%, and 82.1% of eyes in the bare DM group; and in 56.0%, 60.0%, 48.5%, 45.8%, 53.3%, 60.0%, and 54.5% of eyes in the manual dissection group at 1, 1.5, 2, 3, 4, 5, and 6 years, respectively ($P < 0.001$ for all comparisons).

To investigate the effect of keratoconus severity on visual outcomes with each technique of DALK, the study groups were divided into moderate and

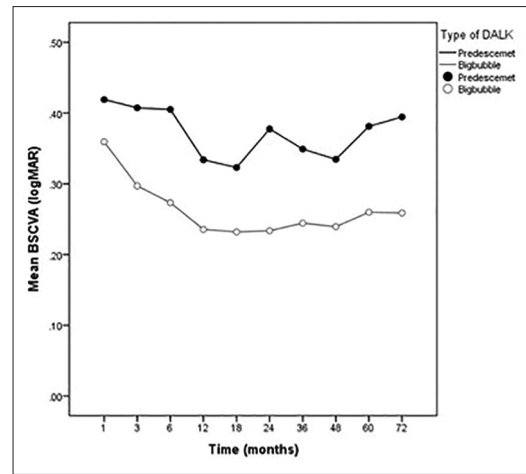


Figure 1. Changes in postoperative best spectacle-corrected visual acuity (BSCVA) over the follow-up period in each group at months 1 ($P = 0.03$), 3 ($P < 0.001$), 6 ($P < 0.001$), 12 ($P < 0.001$), 18 ($P < 0.001$), and years 2 ($P = 0.002$), 3 ($P = 0.001$), 4 ($P = 0.007$), 5 ($P = 0.02$), and 6 ($P = 0.03$).

advanced subgroups according to preoperative mean keratometry [Table 1]. BSCVA was significantly lower in eyes with advanced KCN in the manual dissection group as compared to other subgroups ($P < 0.05$ for all comparisons).

At final follow-up, Groups 1 and 2 were comparable in terms of spherical equivalent refractive error [-4.24 ± 3.35 D (range, -16.0 to + 4.50 D) versus -4.49 ± 3.25 D (range, -12.5 to + 1.50 D), respectively; $P = 0.61$], mean keratometry [46.75 ± 2.62 D (range, 39.25 to 56.5 D) versus 46.87 ± 2.54 D (range, 40.75 to 54.5 D), respectively; $P = 0.75$] and keratometric astigmatism [3.62 ± 1.92 D (range, 0.50 to 6.50 D) versus 3.38 ± 1.71 D (range, 0.50 to 7.50 D), respectively; $P = 0.39$].

In the current case series, DM microperforations leading to double anterior chamber postoperatively occurred in 4 eyes. These included two cases of DM microperforations caused by inadvertent insertion of the needle into the anterior chamber necessitating layer-by-layer manual stromal dissection and two more instances of microperforation during graft suturing after a successful big-bubble. All DM detachments were managed successfully with a single injection of air into the anterior chamber, postoperatively.

DISCUSSION

The purpose of the current study was to evaluate the effect of residual stroma on postoperative visual acuity and refractive status in keratoconic eyes undergoing DALK with the big-bubble technique when a bare DM was not successfully achieved.

The results of our study demonstrate that visual recovery is faster and better after exposure of DM as compared to the manual dissection technique.

Table 1. Comparison of logMAR BSCVA between two subgroups of keratoconus severity with each technique of DALK

	Moderate keratoconus	Severe keratoconus	P
Big-bubble DALK	0.16±0.08	0.18±0.10	0.24
Manual dissection DALK	0.16±0.09	0.29±0.15	0.007
P	0.67	0.01	

logMAR, logarithm of minimum angle of resolution; BSCVA, best-corrected visual acuity; DALK, deep anterior lamellar keratoplasty

Interestingly, BSCVA was significantly lower in a subset of the manual dissection group with advanced keratoconus than other subgroups. This observation can be explained by the fact that the greater surface area of remaining stroma in advanced cases can cause more severe interface haziness. Keratometric astigmatism and refractive results were comparable between the study groups despite a wider range in the manual dissection group. After the outliers were removed from this group, the differences between the two groups remained insignificant (data not shown). Therefore, the lower visual acuity observed in the manual dissection group may be attributable to the quality of the donor-recipient interface.

Our findings are in agreement with the results of studies that report eyes with exposed DM have better visual acuity.^[9,11,15-19] This difference is usually less than one Snellen line of visual acuity on average. Conversely, a number of other studies have found no significant difference in visual acuity improvement between eyes with bare DM exposure and those with retained stroma.^[10,13,14,20,21] This discrepancy can be explained by two facts. First, the thickness of the residual stromal bed in the manual dissection technique varies in different studies, depending on the surgeon's ability to judge how close the lamellar dissection blade can come to DM without puncturing it. We found that a crescent blade is a safe instrument to dissect the recipient stroma down to DM. Additionally, all the procedures were performed by a single experience anterior segment surgeon. Surgeon's experience is also important to create a smooth, uniform, and deep dissection when a bare DM cannot be successfully achieved by air injection. The importance of residual stromal thickness for visual recovery has been previously reported. Ardjomand et al^[22] found that visual acuity was comparable to that observed in PK in DALK eyes with a recipient bed thickness less than 20 mm. Sarnicola et al^[13] used ultrasonic pachymetry to measure central corneal thickness between descemetic and pre-descemetic groups and revealed similar postoperative values for both groups, explaining why there was no difference between the two groups in terms of visual acuity at the end of their 30-month follow-up period. Conversely, Borderie et al^[19] found visual

acuity did not correlate with thickness of the remaining recipient posterior stroma or with its regularity. Fontana et al^[9] reported that final BSCVA was better in patients in whom a big-bubble was achieved than in patients who required layer-by-layer deep stromal dissection despite comparable central pachymetry. It seems likely that lower visual recovery when posterior stroma is retained is related to opacity of the interface or the remaining recipient posterior stroma rather than residual thickness. In the current study, the pre-descemetic group exhibited some fluctuations in BSCVA over the follow-up period. Such a variation in visual acuity observed in this group can be attributable to absorption of fluid or remodeling of the donor-recipient interface and residual stroma.^[23,24]

The second issue which needs to be considered is sample size. The majority of studies reporting comparable visual outcomes between these two DALK techniques contained a small number of patients in the manual dissection group. We previously evaluated visual acuity in 123 keratoconic eyes that underwent DALK and found that postoperative BSCVA was significantly better in the bare DM group ($n = 100$) than in the manual dissection group ($n = 23$) at months 1, 3, 6, and 12.^[21] At the final examination performed 2 years postoperatively, visual acuity tended to be lower in the latter group, although the difference was not statistically significant.^[21] Extending the sample size and the duration of follow-up, we found in the present study that visual acuity was significantly lower in the manual dissection group at all postoperative points. These results indicate that if the number of eyes undergoing manual dissection exceeds a certain number, the differences that are not so obvious due to the small number of patients might become significant. Post-hoc analysis revealed this number to be 46 and 61 eyes in the pre-descemetic group in order to find a significant difference of one Snellen line with study power of 80% and 90%, respectively.

The results of the current study should be interpreted in the context of its limitation. We did not measure the thickness of residual corneal stroma in the manual dissection group. Therefore, it is not possible to conclude whether there is any significant difference in recipient bed thickness between the study groups. Additionally, we cannot investigate the correlation between residual stromal thickness and postoperative visual acuity in order to find a certain level of thickness above which BSCVA begins to decrease. Another limitation is that only BSCVA and refraction were compared between the study groups. Other aspects of visual function such as contrast sensitivity and higher-order aberrations could be affected by the retention of posterior corneal stroma, which were not addressed in the current series.

In summary, when a big bubble is not obtained firsthand during DALK for KCN, the procedure can be converted into air-assisted manual dissection, which

allows successful completion of the DALK procedure. With this approach, a variable thickness of deep stroma is often left behind resulting in inferior visual outcomes. Therefore, if bare DM is not achieved, the surgeon has to choose between greater survival of the corneal graft and lower visual acuity following pre-descemet DALK, versus converting to PK in the hope of better visual quality at the expense of a higher risk of graft rejection.

Financial Support and Sponsorship

Nil.

Conflicts of Interest

There are no conflicts of interest.

REFERENCES

- Terry MA. The evolution of lamellar grafting techniques over twenty-five years. *Cornea* 2000;19:611-616.
- Morris E, Kirwan JF, Sujatha S, Rostron CK. Corneal endothelial specular microscopy following deep lamellar keratoplasty with lyophilised tissue. *Eye (Lond)* 1998;12(Pt 4):619-622.
- Anwar M. Dissection technique in lamellar keratoplasty. *Br J Ophthalmol* 1972;56:711-713.
- Archila EA. Deep lamellar keratoplasty dissection of host tissue with intrastromal air injection. *Cornea* 1984;3:217-218.
- Amayem AF, Anwar M. Fluid lamellar keratoplasty in keratoconus. *Ophthalmology* 2000;107:76-79.
- Melles GR, Lander F, Rietveld FJ, Remeijer L, Beekhuis WH, Binder PS. A new surgical technique for deep stromal, anterior lamellar keratoplasty. *Br J Ophthalmol* 1999;83:327-333.
- Anwar M, Teichmann KD. Big-bubble technique to bare Descemet's membrane in anterior lamellar keratoplasty. *J Cataract Refract Surg* 2002;28:398-403.
- Fogla R, Padmanabhan P. Results of deep lamellar keratoplasty using the big-bubble technique in patients with keratoconus. *Am J Ophthalmol* 2006;141:254-259.
- Fontana L, Parente G, Tassinari G. Clinical outcomes after deep anterior lamellar keratoplasty using the big-bubble technique in patients with keratoconus. *Am J Ophthalmol* 2007;143:117-124.
- Feizi S, Javadi MA, Jamali H, Mirbabaee F. Deep anterior lamellar keratoplasty in patients with keratoconus: Big-bubble technique. *Cornea* 2010;29:177-182.
- Han DC, Mehta JS, Por YM, Htoon HM, Tan DT. Comparison of outcomes of lamellar keratoplasty and penetrating keratoplasty in keratoconus. *Am J Ophthalmol* 2009;148:744-751.e1.
- Unal M, Bilgin B, Yucel I, Akar Y, Apaydin C. Conversion to deep anterior lamellar keratoplasty (DALK): Learning curve with big-bubble technique. *Ophthalmic Surg Lasers Imaging* 2010;41:642-650.
- Sarnicola V, Toro P, Gentile D, Hannush SB. Descemet DALK and pre-descemet DALK: Outcomes in 236 cases of keratoconus. *Cornea* 2010;29:53-59.
- Kubaloglu A, Sari ES, Unal M, Koytak A, Kurnaz E, Cinar Y, et al. Long-term results of deep anterior lamellar keratoplasty for the treatment of keratoconus. *Am J Ophthalmol* 2011;151:760-767.e1.
- Fontana L, Parente G, Sincich A, Tassinari G. Influence of graft-host interface on the quality of vision after deep anterior lamellar keratoplasty in patients with keratoconus. *Cornea* 2011;30:497-502.
- Al-Torbak AA, Al-Motowa S, Al-Assiri A, Al-Kharashi S, Al-Shahwan S, Al-Mezaine H, et al. Deep anterior lamellar keratoplasty for keratoconus. *Cornea* 2006;25:408-412.
- Anwar M, Teichmann KD. Deep lamellar keratoplasty: Surgical techniques for anterior lamellar keratoplasty with and without baring of Descemet's membrane. *Cornea* 2002;21:374-383.
- Tan DT, Anshu A, Parthasarathy A, Htoon HM. Visual acuity outcomes after deep anterior lamellar keratoplasty: A case-control study. *Br J Ophthalmol* 2010;94:1295-1299.
- Borderie VM, Sandali O, Bullet J, Gaujoux T, Touzeau O, Laroche L. Long-term results of deep anterior lamellar versus penetrating keratoplasty. *Ophthalmology* 2012;119:249-255.
- Bhatt UK, Fares U, Rahman I, Said DG, Maharajan SV, Dua HS. Outcomes of deep anterior lamellar keratoplasty following successful and failed 'big bubble'. *Br J Ophthalmol* 2012;96:564-569.
- Feizi S, Javadi MA, Rastegarpour A. Visual acuity and refraction after deep anterior lamellar keratoplasty with and without successful big-bubble formation. *Cornea* 2010;29:1252-1255.
- Ardjomand N, Hau S, McAlister JC, Bunce C, Galaretta D, Tuft SJ, et al. Quality of vision and graft thickness in deep anterior lamellar and penetrating corneal allografts. *Am J Ophthalmol* 2007;143:228-235.
- Marchini G, Mastropasqua L, Pedrotti E, Nubile M, Ciancaglini M, Sbabo A. Deep lamellar keratoplasty by intracorneal dissection: A prospective clinical and confocal microscopic study. *Ophthalmology* 2006;113:1289-1300.
- Borderie VM, Werthel AL, Touzeau O, Allouch C, Boutboul S, Laroche L. Comparison of techniques used for removing the recipient stroma in anterior lamellar keratoplasty. *Arch Ophthalmol* 2008;126:31-37.