



## Giant Ureteral Fibroepithelial Polyp Presenting As a Bladder Mass Resected Ureteroscopically: A Case Report

Ali Momenzadeh<sup>1</sup>, Farhad Sarrafzadeh<sup>2</sup>, Mohammad-Hossein Nourbala<sup>1</sup>, Amin Saburi<sup>3\*</sup>, Zeinab Telkabadi<sup>1</sup>

<sup>1</sup> Nephrology and Urology Research Center, Baqiyatallah University of Medical Sciences, Tehran, IR Iran

<sup>2</sup> Department of Internal Medicine, Faculty of Medicine, Kerman University of Medical Sciences, Kerman, IR Iran

<sup>3</sup> Chemical Injury Research Center, Baqiyatallah University of Medical Sciences, Tehran, IR Iran

\* Corresponding author: Amin Saburi, Chemical Injury Research Center, Baqiyatallah University of Medical Sciences, Mollasadra St, Vanak Sq, Tehran, IR Iran. Tel.: +98-2188600067, Fax: +98-2188600067, E-mail: aminsaburi@yahoo.com

### ABSTRACT

Primary ureteral neoplasms are very rare and its prevalence is less than 1% of all genitourinary neoplasms. We report a symptomatic giant ureteral fibro epithelial polyp in adult women presenting as a bladder mass which was resected ureteroscopically and reported at the first time from Iran. Cystoscopy is growing use in the treatment of urinary tract lesions Cystoscopy can be used in large lesions in centers with experience rather than open surgery.

**Keywords:** Neoplasms, Fibroepithelial; Ureter; Ureteroscopy; Urinary Bladder

Copyright © 2013, Kowsar Corp.; Published by Kowsar Corp.

### 1. Introduction

Primary ureteral neoplasms are very rare in adults and are responsible for less than 1% of all genitourinary neoplasms (1). Only one-fifth of them are benign, and the mesodermal benign tumor such as Ureteral Fibroepithelial polyp (UFP) is more common (2). The UFP is usually located on the proximal portion of the ureter and is covered by a layer of normal urothelium (3, 4). generally speaking, it is not significantly symptomatic unless it makes obstruction (partial or complete) which characterized

by obstructive or irritability symptoms such as suprapubic or flank pain, hematuria (usually microscopic), frequency and dysuria (3). The releasing symptoms depend on polyp size and situation. Imaging diagnostic studies show ambiguous space occupying lesions commonly which was certainly diagnosed and treated by excisional biopsy (endoscopic or surgical) and histopathological report (5). We report a giant ureteral fibroepithelial polyp in adult patients representing a bladder mass which was resected ureteroscopically at the first time from Iran.

►Article type: Case Report; Received: 19 Mar 2012, Revised: 11 Apr 2012, Accepted: 22 Apr 2012; DOI: 10.5812/numonthly.4933

►Implication for health policy/practice/research/medical education:

Cystoscopy is growing use in the treatment of urinary tract lesions such as fibroepithelial polyps and also Cystoscopy can be used in large lesions in centers with experience rather than open surgery. Fibroepithelial polyps can mimic bladder mass if they were located in the lower portion of ureter or extend so enough to reach the bladder.

►Please cite this paper as:

Momenzadeh A, Nourbala MH, Saburi A, Telkabadi Z. Giant Ureteral Fibroepithelial Polyp Presenting As a Bladder Mass Resected Ureteroscopically: A Case Report. *Nephro-Urol Mon.*2013;5(1): 706-708. DOI: 10.5812/numonthly.4933

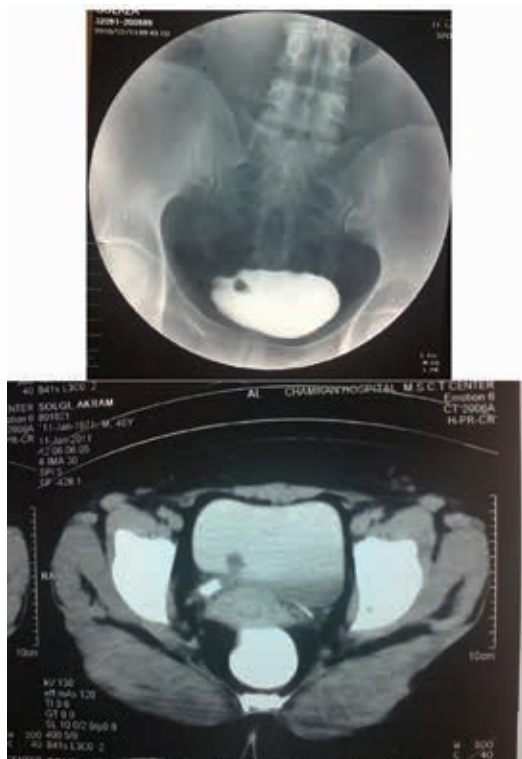►Copyright © 2013, Kowsar Corp.; Published by Kowsar Corp.

This is an Open Access article distributed under the terms of the Creative Commons Attribution License (<http://creativecommons.org/licenses/by/3.0>), which permits unrestricted use, distribution, and reproduction in any medium, provided the original work is properly cited.

## 2. Case Presentation

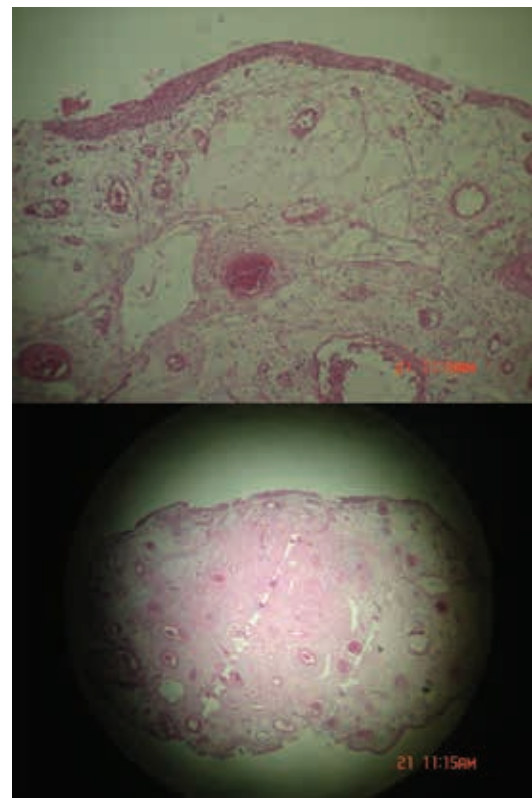
A medical center diagnosed dysuria with obscure lower abdominal pain (during avoiding, specially) in a 44-year old female patient two weeks ago. Microscopic hematuria results from urine and blood sample laboratory analysis. She had no remarkable history of renal stone, urinary tract infections or any urinary stigmas. Physical examination has shown mild tenderness in right post-vertebral angle without any other significant evidence. In hydronephrosis, a small effect has been diagnosed in the urinary bladder (US) which located on the right ureterovesical junction without any evidence of hydronephrosis. Computed tomography (CT) scan and IVP have revealed a small vegetative mass with 50×18 mm diameter situated near to trigon ( *Figure 1* ). Cystoscopy showed a pedunculated polypoid tumor establishing on the right ureterovesical orifice and then the lesion was resected completely. Histopathology report was compatible with polypoid cystitis without malignant components. Forty days later, the patient was admitted in this center due to dysuria and right flank pain. Except microscopic hematuria in urine cytology, another laboratory result consisting

side of the right vesicoureteral orifice. The fragmentally mass resection revealed the base of the tumor (90 mm in length and 10 mm in diameter) situated in the lower portion of ureter. The polyp stalk was coagulated and excised with claspers forceps and then the whole right ureteroscopy was assessed perfectly. Double-J stent was resided to prevent the ureteral stricture and periodically was reexamined by ultrasound or IVP until removal (3 weeks later). Histopathological analysis and retrospectively previous specimen re-assessment have confirmed a ureteral fibroepithelial polyp ( *Figure 2* ). There were no evidences of polyp recurrence or ureteral stenosis in 12 months after the double-J stent discontinuation and the patient was asymptomatic.



**Figure 1.** IVP Findings; A Small Round Shape Mass Near to Trigon Which Was Prolapsed into Bladder

blood biochemical data were in normal ranges and urine cultures were negative. Renal US displayed moderate to severe hydronephrosis. She was undergone Re-Cystoscopy with diagnosis of urinary bladder mass. Cystoscopy showed a mass with a lobulated appearance sticking out-



**Figure 2.** Pathologic Figures

## 3. Discussion

Neoplasms which originated from ureter are rare and commonly malignant. However, UFPs are the most common non-malignant neoplasms; they are still rare clinically and primarily seen in males and on the left side (1). UFPs grossly seem as finger-like projection originating from the sub-mucosa of the ureter which attached to a single base (6). UFPs are composed of vascular and fibrous tissue covered with normal transitional epithelium (7). The clinical presentations are different depending on lesion location in ureter (1). UFP can be lengthened enough prolapsed into the bladder cavity and it can induce sur-

geons' aberrant (8). Management plan has different location and complication (5). Endoscopic plan of large UFPs is an acceptable treatment option with minimal adverse complications and durable treatment outcomes (5, 6, 9). Open resection approved a ureteral polyp originating from the lower ureter elongated into the bladder, which mimicked vesicle mass (7, 8).

We report a case of large UFP presenting a vegetative bladder mass excised ureteroscopically. Reviewing the English literature illustrated multiple reports of UFP, but ureteral fibroepithelial polyp elongated into the bladder cavity was rare which mimicked bladder mass resected ureteroscopically (3, 8-15). UFP was not reported from Iran and it was the first report. The authors recommend further assessment for any mass juxtaposed vesicoureteral junction and also suggest ureteroscopically approach to distal UFPs.

### Acknowledgements

Authors thank the patient and her family for their kind collaboration.

### Authors' Contribution

Momenzadeh, Sarrafzadeh, Nourbala were involved in patient's treatment, Momenzadeh, Saburi and Telkabadi follow the case and gathered the data, Saburi and Telkabadi wrote the initial draft. All authors approved the final manuscript.

### Financial Disclosure

None declared.

### Funding/Support

There is no financial support in this manuscript.

### References

1. Piovesan A, Torricelli F, Borges L, Chambô J, Mesquita J, Srougi M. Ureteral fibroepithelial polyps in a pregnant woman: case report. *Sao Paulo Med J.* 2009;**127**(4):238-40.
2. Tato Rodriguez J, Lema Grille J, Cimadevila Garcia A, Blanco Parra M, Lamas Cedron P, Rios Tallon L, et al. [A fibroepithelial polyp of the ureter. A report of 2 new cases]. *Actas Urol Esp.* 1997;**21**(4):420-5.
3. Baltogiannis D, Kafetsoulis A, Giannakis D, Saito M, Miyagawa I, Sofikitis N. Fibroepithelial polyp of distal ureter with periodic prolapse into bladder. *Urol Int.* 2008;**80**(3):338-40.
4. Ruiz-Lopez MJ, Ramirez-Garrido F, Noguerras-Ocana M, Munoz-Hoyos A, Martin A. Recurrent ureteric fibroepithelial polyp in a child. *Eur J Pediatr.* 2004;**163**(2):124-5.
5. Lam JS, Bingham JB, Gupta M. Endoscopic treatment of fibroepithelial polyps of the renal pelvis and ureter. *Urology.* 2003;**62**(5):810-3.
6. Yagi S, Kawano Y, Gotanda T, Kitagawa T, Kawahara M, Nakagawa M, et al. Endoscopic treatment of a long fibroepithelial ureteral polyp. *Int J Urol.* 2001;**8**(8):467-9.
7. Lai TK, Chung CH, Chin AC, Szeto PS, Wong WC, Chan RY, et al. Magnetic resonance imaging for ureteral fibroepithelial polyp. *Hong Kong Med J.* 2008;**14**(5):408-10.
8. Yeh CC, Lin HC, Che CC, Wu HC. Ureteral fibroepithelial polyp prolapsed into the bladder cavity suspending a bladder stone. *J Urol.* 2001;**165**(5):1627-8.
9. Coloma del Peso A, Bocardo Fajardo G, Teba del Pino F, Fernandez Gonzalez I, Brime Menendez R, Fernandez Borrell A, et al. Endoscopic treatment of a giant fibroepithelial polyp of the ureter. *Arch Esp Urol.* 2010;**63**(4):305-8.
10. Numakura K, Tsuchiya N, Inoue T, Horikawa Y, Kakinuma H, Togashi H, et al. [A case of fibroepithelial polyp of the ureter resected ureteroscopically]. *Hinyokika Kyo.* 2005;**51**(4):277-81.
11. Sano K, Terashima K, Aida N, Ijiri R, Tanaka Y, Nosaka S. [A case of ureteral polyp prolapsing into bladder in a 3-year-old boy]. *Hinyokika Kyo.* 1998;**44**(10):737-8.
12. Macksood MJ, Roth DR, Chang CH, Perlmutter AD. Benign fibroepithelial polyps as a cause of intermittent ureteropelvic junction obstruction in a child: a case report and review of the literature. *J Urol.* 1985;**134**(5):951-2.
13. Luthans F, Avolio BJ, Walumbwa FO, Li W. The psychological capital of Chinese workers: Exploring the relationship with performance. *Manage Organiz Rev.* 2005;**1**(2):249-71.
14. Schiotz HA. Fibroepithelial polyp of the ureter. A case history and discussion. *Acta Obstet Gynecol Scand.* 1990;**69**(3):267-8.
15. Terai A, Terachi T, Yoshida S. Prolapsed benign polyp of ureter associated with giant ureteral calculus. *Hinyokika Kyo.* 1989;**35**(5):871-3.