Percutaneous Nephrostomy for Treatment of Posttransplant Ureteral Obstructions

Seyed Abulghasem Mostafa, Shahin Abbaszadeh, Saeed Taheri, Mohammad Hossein Nourbala

Introduction: We report our experience with percutaneous management of urologic complications following kidney transplantation.

Materials and Methods: Of 1402 consecutive kidney transplant recipients from living donors at our hospital, 21 required percutaneous nephrostomy (PCN) for the treatment of obstructive lymphocele (n = 11), urinary calculus (n = 8), and stricture of the ureterovesical junction anastomosis (n = 2). We had also 11 kidney recipients with urine leakage from the ureter who were treated only by indwelling ureteral catheter. Urinary complications were diagnosed based on the clinical symptoms, elevated serum creatinine levels, ultrasonography and renal scintigraphy. Patients with ureteral obstruction or urine leakage were compared with kidney recipients without urologic complications.

Results: A mean decline of 3.1 ± 3.0 mg/dL (range, 0.1 to 10.7 mg/dL) in serum creatinine level was detected ($P < .001$) after PCN. All of the patients remained symptom free for a mean follow-up period of 34.2 ± 20.1 months (range, 3 to 81 months). Patient and graft survival rates were not different between the patients undergoing PCN and other kidney recipients. The only difference was the history of using antilymphocyte globulin which was significantly more frequent in the patients of the PCN group ($P = .01$).

Conclusion: In our experience, PCN is a safe and effective method for the treatment of ureteral obstructions in kidney allograft recipients. This method provided long-term success with few recurrences and low morbidity and mortality rates.

Keywords: kidney transplantation, obstruction, percutaneous nephrostomy

Urol J. 2008;5:79-83.
www.uj.unrc.ir

Nephrology Research Center, Baqiyatallah University of Medical Sciences, Tehran, Iran

Corresponding Author:
Mohammad Hossein Nourbala, MD
Nephrology Research Center
Department of Kidney Transplantation, Baqiyatallah Hospital, Mullasadra St, Vanak Sq, Tehran, Iran
Tel: +98 21 8126 4154
Fax: +98 21 8126 4157
E-mail: nourbala@gmail.com

Received September 2007
Accepted December 2007

INTRODUCTION

Stricture of the ureterovesical junction (UVJ) anastomosis, with reported incidence rates of 2% to 10%, is the most frequent urologic complication in kidney allograft recipients.[1-3] Significant stricture is a serious complication which can result in kidney failure and permanent damage to the allograft. Open surgery has traditionally been used for correction of the obstruction; however, open procedures are associated with morbidity and delayed convalescence. Development of percutaneous modalities of treatment such as percutaneous nephrostomy (PCN) with low complication rates has altered the approach to ureteral stricture. Percutaneous nephrostomy was first described by Goodwin and colleagues for temporary drainage

in cases of hydronephrosis.[4] Nowadays, this procedure is widely used for the treatment of UVJ obstruction in individuals without renal replacement therapy. However, small series have reported the safety and feasibility of this treatment method in ureteral complications after transplantation.[5] This paper is a report on the experience of an Iranian major transplant center in correcting ureteral obstruction using PCN.

MATERIALS AND METHODS

A total of 1402 kidney transplantation procedures from living donors were performed at our center between 1992 and 2002. Of the allografts, 1305 (93.1%) were provided from living unrelated donors and the remaining 97 (6.9%), from living related donors. In a retrospective review of the clinical and radiological records, we identified 21 recipients (1.5%) who had undergone PCN for the management of obstructive complications of the ureter using the extravesical technique of ureteroneocystostomy (Lich-Gregoir method) with stent placement. Eleven patients with urine leakage were treated by indwelling ureteral catheter for 21 to 60 days without the need for PCN or surgery. Clinical suspicion of urinary complications was based on elevated serum creatinine levels. In all cases, ultrasonography was used to assess the status of the transplanted kidney and the collecting system. Evidence suggestive of ureteral obstruction and urine leakage included ultrasonography findings of hydronephrosis and presence of peritransplant fluid collections, respectively. Renal scintigraphy was also performed in 10 patients. Findings suggestive of an obstruction included hydronephrosis and delayed visualization of the bladder and those suggestive of leakage were detection of radionuclide activity outside the collecting system.

In order to perform PCN, the puncture site was chosen on the basis of the findings of ultrasonography. Antegrade pyelography and ureterography were performed with fluoroscopic guidance. The PCN tube was removed when patency of the ureteral stent was confirmed by antegrade nephrostography and prior clamping. The ureteral stents were removed with cytoscopic guidance and the use of topical anesthesia about 3 months thereafter.

We defined and compared 2 groups of kidney recipients who underwent PCN and those without ureteral complications (control group). Statistical comparisons were performed using the chi-square and the Fisher exact tests for the proportions and the *t* test and paired *t* test for the continuous data. Survival analysis was done by Kaplan-Meier method (death-censored analysis) and differences were assessed using the log-rank test. Data analyses for continuous data were also repeated with the Mann-Whitney test to confirm the results. A *P* value less than .05 was considered significant.

RESULTS

Twenty-one patients underwent PCN, of whom 15 (71.4%) were men and 6 (28.6%) were women. Their mean age at the time of the transplantation was 40.0 ± 12.7 years (range, 18 to 70 years). The mean interval between transplantation and nephrostomy was 74.5 ± 94.0 days (range, 1 to 382 days). The mean serum creatinine values before and after PCN were 5.8 ± 4.2 mg/dL (range, 1.7 to 17.0 mg/dL) and 2.7 ± 1.9 mg/dL (range, 1.0 to 7.5 mg/dL), respectively. The patients experienced a mean decline of 3.1 ± 3.0 mg/dL (range, 0.1 to 10.7 mg/dL) in their serum creatinine values ($P < .001$).

In the PCN group, 11 patients (52.4%) had obstructive lymphocele with hydronephrosis. Percutaneous catheter drainage of the lymphocele for a period of 21 to 70 days relieved hydronephrosis and lymphocele without the need for further procedures. Two patients (9.5%) had ultrasonographic features of UVJ obstruction. Percutaneous nephrostomy relieved the obstruction and serum creatinine values reduced to the stable levels. Balloon dilation of the UVJ obstruction and insertion of a stent in the ureter for 3 months were performed in these 2 patients. Eight patients (38.1%) had calculi and underwent extracorporeal shock wave lithotripsy after PCN, of whom 6 experienced complete clearance of the calculus and 2 needed further interventions.

Percutaneous nephrolithotomy was performed for these 2 patients through the PCN tract using a 12-F Amplatz sheath and a 10-F ureteroscope, which made them stone free.

All of the patients in the PCN group remained symptom free for a mean period of 34.2 ± 20.1 months (range, 3 to 81 months). One patient died 111 months after PCN and 2 experienced kidney failure 6 and 36 months thereafter. The Table outlines demographic and clinical characteristics of the patients in the two groups. The mean follow-up period was 53.1 ± 27.5 months for the kidney recipients in the PCN group and 56.2 ± 38.1 months for the recipients of the control group ($P = .70$). Kaplan-Meier analysis showed no difference between the two groups in 10-year patient and allograft survivals ($P = .40$ and $P = .90$, respectively; Figures 1 and 2). The only difference was the history of using antilymphocyte globulin which was significantly more frequent in the patients of the PCN group ($P = .01$)

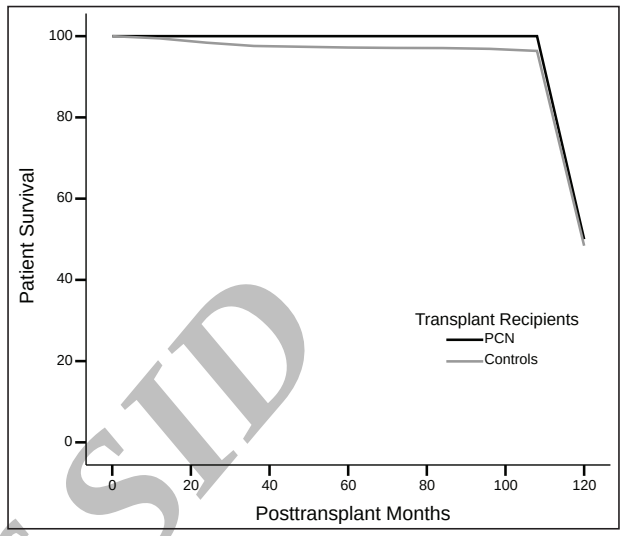

Figure 1. Patient survival curve of kidney allograft recipients with and without percutaneous nephrostomy.

Characteristics of Kidney Allograft Recipients With and Without Percutaneous Nephrostomy (PCN)

Characteristics	Group 1 (PCN)	Group 2 (No PCN)	*P*
Age at transplantation, y	40.0 ± 12.7	42.9 ± 13.6	.56
Sex, %			
Male	71	68.1	
Female	29	31.9	.58
Transplant time, %			
1	100	94	
2	0	5	
3	0	0.3	.77
Transplantation side (right iliac fossa), %	90	89	.88
Warm ischemia time, min	17.2 ± 0.5	17.2 ± 2.7	.89
Cold ischemia time, min	19.1 ± 1.7	20.6 ± 10.5	.46
Ureteral anastomosis technique (Lich-Gregoir), %	95	99	.80
Positive panel reactive antibodies, %	7	7	.90
Positive cytomegalovirus, %			
IgG	40	35	.72
IgM	5	2.5	.53
Positive Epstein-Barr virus, %			
IgG	25	24	.92
IgM	0	1.6	.64
Drugs, %			
Ganciclovir	30	14.5	.10
Antilymphocyte globulin	30	10	.01
Mycophenolate mofetil-based triple therapy	65	55	.70
Living unrelated donor, %	75	81	.65
Donor sex, %			
Male	90	88	
Female	10	12	.84
Donor age	28.1 ± 5.2	27.8 ± 5.2	.54

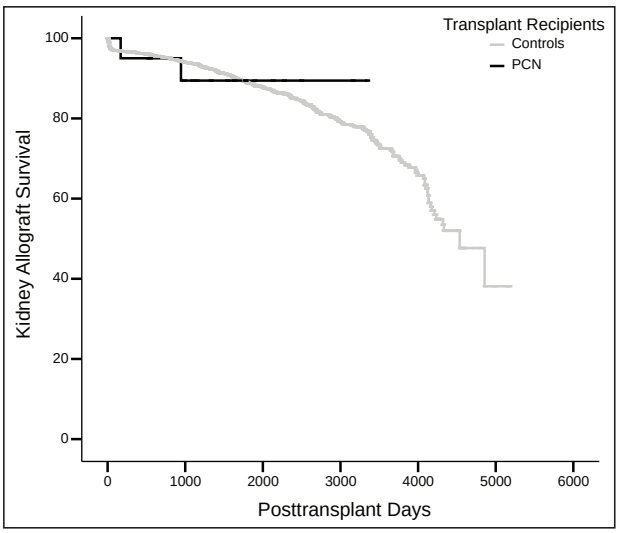

Figure 2. Death-censored graft survival curve of kidney allograft recipients with and without percutaneous nephrostomy.

DISCUSSION

A number of studies have evaluated PCN in the treatment of ureteral obstruction and urine leakage in kidney transplant patients.[6-8] Ureteral obstruction and leakage are the most common urologic complications encountered in kidney transplant recipients.[9-11] Most series indicate that about 70% of the ureteral obstructions occur within 3 months of transplantation and 80% occur at the UVJ site.[2,12,13] Prompt diagnosis and early treatment are critical for preventing loss of the allograft and decreasing morbidity and mortality. Ultrasonography and renal scintigraphy can be used as initial diagnostic techniques for assessing the patency and integrity of the renal collecting system. Diagnosis of the obstruction or leakage can be definitively confirmed using percutaneous antegrade pyelography.

Percutaneous approach should be considered as a method of therapy for ureteral stricture regardless of the severity of obstruction.[6] Obstructions that occur soon after transplantation are thought to be due to mechanical causes including blood clots, calculi, edema, and ischemic necrosis, whereas late obstructions are usually the result of local or generalized fibrosis due to ischemia or rejection.[4,11-15] Fibrosis detected in late obstructions is less likely to resolve with insertion of an intraluminal ureteral stent. We had 2 patients with late UVJ anastomosis obstruction and ureteral stent insertion for 3 months, in whom obstruction did not occur after stent removal during the follow-up period.

As mentioned, PCN is a well-established technique for rapid relief of ureteral obstruction and improvement of the kidney function. However, if this method fails, open surgery will be considered which is associated with higher mortality and morbidity rates. Repeated surgery in the kidney transplant patient can be extremely difficult and may result in graft loss and/or significant blood loss if not performed by an experienced surgeon. None of our patients needed open surgery.

Leakage is usually the result of ureteral necrosis as a consequence of rejection or vascular insufficiency.[14-19] Aside from the 21 patients who underwent PCN in our study population, there were also 11 patients with leakage, all of whom were treated by insertion of an indwelling ureteral catheter for 21 to 60 days without the need for PCN or surgery. The overall incidence of posttransplant leakage and obstruction was 2.3% at our center.

In the present study, we observed that most of the cases with atypical transplant ureteral strictures presented after more than 4 months posttransplant. No case of death or nephrectomy attributable to PCN occurred and the outcomes were comparable to those of the kidney recipients without urologic complications. One patient died after about 9 years and 2 experienced allograft rejection within 6 and 36 months after PCN. All of the patients remained symptom free for a mean duration of 34 months which represents excellent results.

CONCLUSION

In our experience, PCN seems to be a safe and effective method for treatment of ureteral obstruction and leakage in kidney allograft recipients. It provides long-term success with few recurrences and low morbidity and mortality rates. Indwelling stents may also be of use as a measure to control urinary leakage and allow stabilization of the immunocompromised patients who are too ill to undergo the surgery.

CONFLICT OF INTEREST

None declared.

REFERENCES

1. Shoskes DA, Hanbury D, Cranston D, Morris PJ. Urological complications in 1,000 consecutive renal transplant recipients. J Urol. 1995;153:18-21.
2. Jones JW, Hunter DW, Matas AJ. Percutaneous treatment of ureteral strictures after renal transplantation. Transplantation. 1993;55:1193-5.
3. Lieberman SF, Keller FS, Barry JM, Rösch J. Percutaneous antegrade transluminal ureteroplasty for renal allograft ureteral stenosis. J Urol. 1982;128:122-4.
4. Goodwin WE, Casey WC, Woolf W. Percutaneous trocar (needle) nephrostomy in hydronephrosis. J Am Med Assoc. 1955;157:891-4.
5. Reek C, Noster M, Burmeister D, Wolff JM, Seiter H. Urological complications of renal transplantation: a series of 900 cases. Transplant Proc. 2003;35:2106-7.
6. Bhagat VJ, Gordon RL, Osorio RW, et al. Ureteral obstructions and leaks after renal transplantation: outcome of percutaneous antegrade ureteral stent placement in 44 patients. Radiology. 1998;209:159-67.
7. Swierzewski SJ 3rd, Konnak JW, Ellis JH. Treatment of renal transplant ureteral complications by percutaneous techniques. J Urol. 1993;149:986-7.
8. Alcaraz A, Bujons A, Pascual X, et al. Percutaneous management of transplant ureteral fistulae is feasible in selected cases. Transplant Proc. 2005;37:2111-4.
9. Loughlin KR, Tilney NL, Richie JP. Urologic complications in 718 renal transplant patients. Surgery. 1984;95:297-302.
10. Kinnaert P, Hall M, Janssen F, Vereerstraeten P, Toussaint C, Van Geertruyden J. Ureteral stenosis after kidney transplantation: true incidence and long-term follow up after surgical correction. J Urol. 1985;133:17-20.
11. Oosterhof GO, Hoitsma AJ, Witjes JA, Debruyne FM. Diagnosis and treatment of urological complications in kidney transplantation. Urol Int. 1992;49:99-103.
12. Schwartz BF, Chatham JR, Bretan P, Goharderakhshan R, Stoller ML. Treatment of refractory kidney transplant ureteral strictures using balloon cautery endoureterotomy. Urology. 2001;58:536-9.
13. Streem SB, Novick AC, Steinmuller DR, Zelch MG, Risius B, Geisinger MA. Long-term efficacy of ureteral dilation for transplant ureteral stenosis. J Urol. 1988;140:32-5.
14. Lojanapiwat B, Mital D, Fallon L, et al. Management of ureteral stenosis after renal transplantation. J Am Coll Surg. 1994;179:21-4.
15. Thomalla JV, Lingeman JE, Leapman SB, Filo RS. The manifestation and management of late urological complications in renal transplant recipients: use of the urological armamentarium. J Urol. 1985;134:944-8.
16. Kashi SH, Lodge JP, Giles GR, Irving HC. Ureteric complications of renal transplantation. Br J Urol. 1992;70:139-43.