Congenital fusion of the maxilla and mandible: brief case report

Mohammad Ghasem Shams, DMD,[a] Mohammad Hosein Kalantar Motamedi, DDS,[b] and Hassan Lal Dolat Abad, MD,[c] Tehran, Iran
BAQIYATALLAH MEDICAL SCIENCES UNIVERSITY AND AZAD UNIVERSITY OF MEDICAL SCIENCES

Congenital fusion of the mandible and maxilla is a rare anomaly usually seen in association with various syndromes. Reports of isolated cases of bony fusion of the jaws are sparse. Only 10 reported cases were found in the literature search. Maxillomandibular fusion restricts mouth opening, causing feeding problems and difficulties in swallowing, respiration, growth, and development, and thus must be treated early. We report a case of congenital fusion of the mandible and maxilla in a 1-year-old boy and describe the clinical features of this anomaly to add to the existing literature on the subject. This is our second encounter of such a case.
(Oral Surg Oral Med Oral Pathol Oral Radiol Endod 2006;102:e1-e3)

Congenital fusion of the jaws is rare. Although it may present separately, it is often found along with syndromes such as Van der Woude, cleft palate lateral alveolar synechiae syndrome, or other defects and anomalies.[1] The fusion may be unilateral or bilateral and may involve only the soft tissues or both the hard and soft tissues. Restriction of mouth opening affects infant growth and development due to problems in feeding, swallowing, and respiration. Early treatment to mobilize the jaw is essential not only for these problems, but also because in the early stages this condition can be treated more easily. In long-standing cases, temporomandibular joint (TMJ) ankylosis often occurs because of immobility and lack of function, necessitating more complicated surgical treatment.

CASE PRESENTATION

A 1-year-old boy suffering from inability to open the mouth since birth was brought to our clinic for treatment. Upon examination it was evident that the patient's jaws were fused bilaterally in the posterior regions, while in the anterior region there was an 8-mm openbite. Intermaxillary fibrous adhesions 1 cm wide and 4 mm thick were present bilaterally between the alveolar ridges of the maxilla and mandible in the molar areas as well as laterally with the cheeks, extending posteriorly (Fig. 1). Computerized tomography (CT) scanning with 3-dimensional spiral reconstructions revealed a bony fusion only on the right side of the posterior part of the mandible (Fig. 2). Axial CT scans ruled out bony fusion of the TMJs. No significant information was obtained from the family's medical history. The mother had had a healthy gestation period and there was no account of illness, trauma, or drug use in her medical history. The baby was the family's first child, and there was no history of congenital anomalies in close relatives. Obstruction of the left lacrimal duct, however, was of note in the child. Laboratory blood exam values were within normal limits.

TREATMENT

Following general anesthesia, the fibrous adhesions on the left side and bony-fibrocartilage adhesions and synechiae on the right side were excised via electrocauterization. Manual and instrumental manipulation with an expander was then gently employed to attain an interalveolar mouth opening of 30 mm. No complications were encountered in the postoperative period.

DISCUSSION

Synechiae are adhesions between anatomic structures. Such congenital adhesions are rare in the oral cavity.[1,2] Synechiae most commonly arise between the upper and lower alveolar ridges (syngnathism) or between the tongue and margins of the palate or maxilla (glossopalatal ankylosis); synechiae arising from the lower lip, the floor of the mouth, or at the oropharyngeal isthmus have also been described.[2] These adhesions consist of membranes or bands of epithelium supported by various amounts of connective tissue, and

[a]Assistant Professor of Oral and Maxillofacial Surgery, Attending Surgeon, Clinic of Oral and Maxillofacial Surgery, Baqiyatallah Medical Center, Baqiyatallah Medical Sciences University.
[b]Associate Professor of Oral and Maxillofacial Surgery, Attending Surgeon at the Baqiyatallah Medical Center, Baqiyatallah Medical Sciences University, and at the Department of Oral and Maxillofacial Surgery, Azad University of Medical Sciences.
[c]Assistant Professor of Anesthesiology, Department of Anesthesiology, Baqiyatallah Medical Center, Baqiyatallah Medical Sciences University.
Received for publication Sept 5, 2005; returned for revision Sept 30, 2005; accepted for publication Oct 18, 2005.
1079-2104/$ - see front matter
© 2006 Mosby, Inc. All rights reserved.
doi:10.1016/j.tripleo.2005.10.051

Fig. 1. Bilateral intermaxillary fibrous adhesions evident between the alveolar ridges of the maxilla and mandible in the molar area and the cheeks that extend posteriorly.

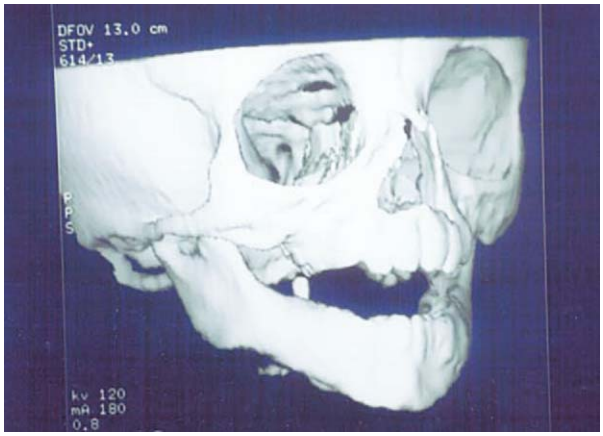

Fig. 2. Computerized tomography scan with 3-dimensional spiral reconstructions revealing a bony fusion on the right side of the posterior part of the mandible.

possibly even muscle or bone.[2] Alveolar synechiae are almost always accompanied by one or more additional congenital defects, such as cleft palate, cleft lip, microglossia, micrognathia, TMJ disorders, or lip anomalies. Cleft palates are the deformities most frequently seen with alveolar synechiae.[1-8] Alveolar synechiae in conjunction with a cleft palate is known as cleft palate lateral alveolar synechiae syndrome.[7,8] Popliteal pterygium syndrome is another possibility. The lack of family history does not preclude this as a potential diagnosis.

Congenital alveolar adhesions are rarely seen in isolation. In a study that reviewed 50 cases of alveolar synechiae reported between 1990 and 1993 (and also submitted 2 additional cases), Gartlan et al.[6] reported that isolated congenital alveolar synechiae without associated anomalies were observed in only 7 cases. In review of the literature, a further 10 cases of congenital alveolar synechiae were found to have been reported. Only 2 of these were isolated congenital alveolar synechiae; the others occurred together with syndromes such as Van der Woude, cleft palate alveolar synechiae, and oromandibular limb hypogenesis syndrome.[7-12]

The etiology of synechiae remains unknown. It is stated that during the seventh to eighth week of embryological development of the alveolar ridges, when the tongue and palatal shelves are in contact with each other, the ensuing palatal closure depends on downward contraction of the tongue. When the tongue protrudes from the mouth as a result of medial movements of the oral cavity walls, it prevents the alveolar ridges from fusing. Genetic, teratogenic, or mechanical insults during this critical period may lead to prolonged, close, quiescent contact between oral structures, thereby predisposing to abnormal fusion.[13] Trauma late in pregnancy, abnormality of the stapedial artery, and teratogenic agents are other reported possible etiologic factors.[14]

Mathis[15] postulated that adhesions were remnants of the buccopharyngeal membrane. Hayward and Avery[16] feel that adhesions develop as a result of contact between the epithelium of the gums or the palatine shelves and the floor of the mouth. Fuhrmann et al.[17] demonstrated a hereditary link and reported that 5 family members had cleft palates and synechiae, one having a cleft palate without synechiae, and another transmitted the gene but did not express it. Sternberg et al.[18] reported a newborn baby with congenital bilateral complete fusion of the gingiva and the TMJs.

Simple surgical division of the adhesions is necessary for normal feeding, to avoid upper airway obstruction, and to allow for normal mandibular function and growth. The sooner treatment is rendered the less the possibility of TMJ ankylosis. It should be of note that although the surgical treatment is short and straightforward, general anesthesia, however, is often difficult in such cases. Fine fiberoptic laryngoscopes are required for endotracheal intubation. Another issue of mention is that the normal-range mouth opening is not obtained immediately after incising the adhesions even after manual manipulation is done to help mobilize the TMJs stiffened due to disuse. Moreover, in view of the soft alveolar ridge in infants and fragile mandibular bone, manipulation is difficult and excessive force may easily lead to jaw fracture. However, patients usually regain normal mouth opening several weeks postoperatively. Our patient obtained normal mouth opening 1 week after surgery.

REFERENCES

1. Tanrikulu R, Erol B, Görgün B, Ilhan O. Congenital alveolar synechiae—a case report. Br Dent J 2005;198:81-8.

2. Miskynyar SA. Congenital mandibulomaxillary fusion. Plast Reconstr Surg 1979;63:120-1.
3. Goodarce TE, Wallace AF. Congenital alveolar fusion. Br J Plast Surg 1990;43:203-9.
4. Agarwal K, Chandra S, Sreekumar NS. Congenital bilateral intermaxillary bony fusion. Ann Plast Surg 1993;30:163-6.
5. Behnia H, Shams MG. Congenital unilateral fusion of the mandible and maxillary alveolar ridges, TMJ, and coronoid process. J Oral Maxillofac Surg 1996;54:773-6.
6. Gartlan MG, Davies J, Smith RJ. Congenital oral synechiae. Ann Otol Rhinol Laryngol 1993;102:186-97.
7. Verdi GD, O'Neal B. Cleft palate and congenital alveolar synechiae syndrome. Plast Reconstr Surg 1984;74:684-6.
8. Dalal M, Davison PM. Cleft palate congenital alveolar synechiae syndrome: case report and review. Br J Surg 2002;55:256-7.
9. Denion E, Capon N, Martinot V, Pellerin P. Neonatal permanent jaw construction because of synechiae and Pierre Robin sequence in a child with van der Woude syndrome. Cleft Palate Craniofac J 2002;39:115-9.
10. Knoll B, Karas D, Persing JA, Shin J. Complete congenital bony syngnathia in a case of oromandibular limb hypogenesis syndrome. J Craniofac Surg 2000;11:398-404.
11. Haramis HT, Apesos J. Cleft palate and congenital lateral alveolar synechiae syndrome: case presentation and literature review. Ann Plast Surg 1995;34:424-30.
12. Ergen C, Sayan NB. Van der Woude syndrome (report of a case). Ankara Üniv Dishek Fak Derg 1985;12:163-9.
13. Haydar SG, Tercan A, Uçkan S, Gürakan B. Congenital gum synechiae as an isolated anomaly: a case report. J Clin Pediatr Dent 2003;28:81-4.
14. Laster Z, Temkin D, Zarfin Y, Kushnir A. A complete bony fusion of the mandible to the zygomatic complex and maxillary tuberosity: case report end review. Int J Oral Maxillofac Surg 2001;30:75-9.
15. Mathis VH. Über einen fall von ernäunng-sschwierigkeit bei connataler syngnathie. Deutsche Zahnäzliche Zeitschrift 1962;17:1167-71.
16. Hayward JR, Avery JK. A variation in cleft palate. J Oral Surg Anesth Hosp Dent Serv 1957;15:320-4.
17. Fhurmann W, Koch F, Scheweckendick W. Autosomol dominante Vererbung von Gaumenspalte and synechien zwischen gaumen und mundboden oder zunge. Humangenetik 1972;14:196-203.
18. Sternberg N, Sagher U, Golan J, Eidelman AI, Ben-Hur N. Congenital fusion of the gums with bilateral fusion of the temporomandibular joints. Plast Reconstr Surg 1983;72:385-7.

Reprint requests:

Mohammad Hosein Kalantar Motamedi, DDS
Africa Expressway, Golestan Street
Giti Boulevard No. 11
Tehran, 19667, Iran
motamedical@lycos.com