ResearchGate

See discussions, stats, and author profiles for this publication at: https://www.researchgate.net/publication/338669805

The impact of Astaxanthin on adverse effects of hyperglycemia induced by STZ in retinal tissue of rat

Article · December 2019

DOI: 10.23751/pn.v21i4.7751

CITATIONS
0

READS
61

1 author:

Farideh Bahrami
Baqiyatallah University of Medical Sciences

35 PUBLICATIONS **110** CITATIONS

SEE PROFILE

All content following this page was uploaded by Farideh Bahrami on 18 January 2020.

The user has requested enhancement of the downloaded file.

Progress in Nutrition 2019; Vol.21, N. 4: 849-857 DOI: 10.23751/pn.v21i4.7751 © Mattioli 1885

Original articles

The impact of astaxanthin on adverse effects of hyperglycemia induced by STZ in retinal tissue of rat

Shahnaz Mojarrab[1,2], Farideh Bahrami[1,2], Ali Khoshbaten[2], Ahmad Shojaei[3], Narsis Daftarian[4], Fatemeh Salem[5], Mohammad Taghi Mohammadi[2]

[1]Neuroscience Research Center, Baqiyatallah University of Medical Sciences, Tehran, Iran; [2]Department of Physiology and Medical physics, School of Medicine, Baqiyatallah University of Medical Sciences, Tehran, Iran - E-Mail: F.Bahrami@bmsu.ac.ir; [3]Department of Ophthalmology, Faculty of Medicine, Baqiyatallah University of Medical Sciences, Tehran, Iran; [4]Ocular Tissue Engineering Research Center, Shahid Beheshti University of Medical Sciences, Tehran, Iran; [5]Department of Pharmacology, School of Pharmacy, Baqiyatallah University of Medical Sciences, Tehran, Iran

Summary. Astaxanthin (ATX) is a powerful natural antioxidant belongs to xanthophylls and the aim of this study is to investigate its protective roles on adverse effects of hyperglycemia in retinal tissue. Sixty rats were randomly divided into Controls, and hyperglycemic groups. ATX (20 mg/kg) was administrated over 47 days. After 47 days the final blood glucose concentration and body weight also the expression of vascular endothelial growth factor (VEGF), tumor necrosis factor α (TNF-α) proteins, antioxidant capacity and vessels dimension in ganglionic cell layer (RGC) layer in retinal tissue were measured as well as immunohistochemistry and histopathological assessments. Hyperglycemia-induced decrement in Catalase (CAT) (0.096 ± 0.026) and Glutathione (GSH) (133.80 ± 65.10) activity in retinal tissue but increase Superoxide dismutase (SOD) (15.52 ± 1.36 mU/mg) and Malondialdehyde (MDA) (2.64 ± 0.12) content. Administration of ATX increased the antioxidant capacity in the treated group ($p<0.05$). An increment in the expression of VEGF and TNF-α and vasodilation were shown in the hyperglycemic groups ($p<0.01$). Immune and histopathological assessments indicated that the ATX treatment could repair vasodilation in RGC layer vessels and also reduce the TNF-α content in retinal tissue ($p<0.05$). ATX could repair vasodilation and inflammation presumably because of removal of oxidizing and inflammatory agents in retinal tissue but during 47- day treatment it could not significantly decrease expression of VEGF in retinal tissue of hyperglycemic group.

Keywords: Astaxanthin; Oxidative stress; Hyperglycemia; Retinal tissue; RGC layer; VEGF

Introduction

Diabetes is a main public health problem. Several factors such as genetic susceptibility, environmental factor, poor control of blood sugar, lifestyles and comorbidities have an impact on the prognosis of diabetes complication (1, 2). Hyperglycemic retinopathy is one of the prevalent complications of diabetes (3). During diabetes, hyperglycemia increases free radicals through different metabolism pathways (4). Oxidative stress is the lack of balance between overproduction and eliminating ROS in the body. During diabetes, the retinal cells and their capillaries experience oxidative stress (4). Research has shown that advanced glycation end products increase vascular endothelial growth factor (VEGF) and inflammatory factors such as tumor necrosis factor α (TNF-α) (5, 6). Inflammation plays an important role in the pathology of hyperglycemic retinopathy (6). Overexpression of VEGF and TNFαinduces the adverse effect on tight junction proteins in vascular endothelial cells in the retina which they cause blood-retinal barrier break down. This event increased vascular permeability and edema in retinal tissue in the hyperglycemic condition (7).

Any organism has enzymatic and non-enzymatic defense mechanisms that remove harmful free radicals.

The enzymatic defense mechanisms include superoxide dismutase (SOD) and catalase(CAT) (8). The non-enzymatic defense mechanisms consist of glutathione, acid ascorbic, vitamin E and etc. Some studies confirm that antioxidant capacity decreases in diabetes and some other demonstrate increment of antioxidant agents in saliva and serum along with the oxidants enhancement in diabetes. Also, it was found that during hyperglycemia vitamin E, C and Beta-carotene have been decreased (9).

Some of the carotenoids are used as a nutritional supplement to prevent oxidative lesions in the retinal tissue. Carotenoids are the phytochemical substance which has hydrocarbon chain with carbon-carbon double bonds, therefore, they can scavenge free radicals and inhibit lipid peroxidation by the unique structure (10). In human one of the significant role of carotenoids are in the macula. Lutein and Zexanthin are the macular pigment carotenoids which exist in the eye in different amounts (11). Research results have shown that during the past two decades the antioxidant action of macular carotenoids, as a filter, is removing optical radiation damage in the retina (11).

Astaxanthin (AXT) is a carotenoid from xanthophylls category that shows pharmaceutical potential (12, 13) and also some of the investigators attribute to it therapeutic role in neurodegeneration (14). The unique feature of AXT is the existence of oxygen with a double bond in the ionic ring at the end of the hydrocarbon chain. This property and the carbon-carbon double bonds contribute to the powerful antioxidant AXT (12).

However, the interaction of this potent antioxidant with other cellular and molecular targets and their exact mechanisms are not clear in the hyperglycemic condition in retinal tissue. The aim of this study is to investigate the effect of AXT on antioxidant capacity, vascular variations and expression of VEGF and TNF ά in retinal tissue in an uncontrolled hyperglycemia condition. In

Methods

Ethics statement

The experimental methods of this study were approved by bioethics committee of the animal house in Baqiyatallah University of Medical Science and have followed the NIH guidelines for use and care of animals(Approval code: IR.bmsu.Rec.1396.620).

Animals

In this study, 48 male Wistar rats weighing 200-225 were used. The rats were kept in standard cages with free access to food and water in temperature of 22 ± 2˚C, humidity of 40% - 60%, and 12 hours light/dark cycle condition.

Diabetes induction

Diabetes was induced by a single tail vein injection of Streptozotocin (Sigma UK) (45 mg/kg) dissolved in 0.1 M citrate buffer. Blood glucose was measured in the first day before streptozotocin (STZ) injection and days 5th and 47th after injection of streptozotocin by Accu-Chek Blood Glucose Meter. Animals with a blood glucose of more than 350 mg/dl were selected as hyperglycemic animals.

Retina Sampling

The animals were euthanized by a lethal dose of Ketamine and Diazepam. The eyeballs were removed and washed with cold PBS (phosphate buffer saline, PH 7.4). The retinas were detached from the retinal pigmented epithelium cell layer and submerged in liquid nitrogen to freeze then stored at -80° C for protein extraction or enzyme assays. For the histopathological and immunohistochemical studies, the whole eye caps were fixed in formalin or paraformaldehyde.

Protocols and Groups of Experiment

Animals in the control group were randomly divided into two groups of (n=12) control and AXT treated rats. Treated- control rats group was fed with AXT (1-800-921-8482 manufactured for Viva Labs Inc, made in the USA), 20 mg/ kg orally once a day by gavages during six weeks. Hyperglycemic animals were randomly divided into two groups (n=12) hyperglycemic and treated-hyperglycemic rats. The treated-hyperglycemic rats group were treated with AXT, 20 mg/kg orally once a day by gavages over six weeks. After six weeks the final blood glucose concentration and body weight were checked.

Enzyme Assays and Protein measurement

Isolated retinas were homogenized and sonicated on ice-cold in PBS solution (pH=7.4) incubated at 4˚C for 30 minutes then centrifuged (15,000 RPM

at 4°C for 30 minutes). The supernatants were used for protein (Bradford method) (15) and enzyme assays. All measures were based on the spectrophotometric assay. The method of Tietz was used to determine the GSH content of retinal tissues (16). Briefly interaction of cell lysate with Na2HPO4 and 5, 5'-dithiobis-(2-nitrobenzoic acid) (DTNB) and the absorbance of DTNB was monitored at 412 nm for 5 minutes. The SOD activity of the retina tissues was measured according to Winterbourne method (17). In this method, potassium phosphate buffer was added to the EDTA solution containing sodium cyanide, NBT and homogenized sample. In presence of the riboflavin, the reaction initiates. The absorbance of samples was measured at 560 nm. For Catalase activity assay the Abei method was used (18). The principle of this method was based on measuring the decrease in absorbance of the test sample by the induced decomposition of H2O2 in the presence of the analytic enzyme at 240 nm wavelength.

MDA content of the retinal tissues was measured by the method of Satoh (19). The homogenized sample was mixed with TCA (Trichloroacetic acid) and centrifuged. MDA content in the supernatant was determined by the interaction of thiobarbituric acid (TBA) and n- Butanol after centrifuging the light absorption of the upper supernatant was monitored at 532 nm. A standard curve of MDA was produced and sensitivity of measurement was determined to be between 1 and 100 μM.

Histological assessment

At the end of the experiment, animals were euthanized by a lethal dose of Ketamine and Diazepam. Eyes were removed and fixed in formalin (10%). After fixation and tissue processing, paraffin- embedded sectioning (each 50 μm intervals) was processed routinely for Hematoxylin and Eosin (H&E) staining (20). The histological changes were observed by a light microscope (Nikon, Japan) connected to the digital camera (CMEX, Holland).

Immunohistochemical (IHC) method

The retina was fixed in paraformaldehyde. Then it was sustained in a sucrose solution and rinsed with acetone at optimal cutting temperature for one night. It was stored at -80° temperature for cutting. Each slide had 10 μm diameters. The slides were defrosted and blocked in a goat serum for one hour. The retinal vasculature and adherent leukocytes were imaged by DPI or VEGF antibody (Santa Cruze) which was diluted in a goat serum 3% incubated overnight in 4°C. Finally, the secondary antibody conjugated to FITC was added. After dehydrating and contrasting, the images were observed under fluorescent microscope. The vascular dimension and area of vessels were measured by Olysia software.

Protein extraction and western blot analysis

Isolated retinas were homogenized and sonicated in a lysis buffer [0.5 M Tris-HCl (pH 7.4), 150 mM NaCl, 0.5% deoxycholic acid, 1% Triton X100, and protease inhibitors(1 tablet/50 ml Tris Buffer (pH 7.2),0.1% SDS] incubated at 4°C for 30 minutes and centrifuged with 14,000 rpm at 4°C for 20 minutes. Protein concentration was determined by the Bradford assay, each sample (50 μg of protein) were mixed 1:1 with sample buffer (60 mM Tris, 10% glycerol, 2% sodium dodecyl sulfate, 5% 2-beta-mercaptoethanol, 0.01% bromophenol blue, pH 6.8) and boiled for 5 minutes. The proteins were separated by electrophoresis in a 12% polyacrylamide gel (for 1.5 hours at 90 V) and were transferred into nitrocellulose membranes via wet blotting protocol (overnight, 15 vol). After washing the nonspecific bindings were blocked by Western blocking solution (free fat milk in Tris Buffer Solution (TBS)) for 5hour at 4°C. The blots were then incubated with the primary rabbit polyclonal IgG VEGF antibodies (1:1000; sc-152), diluted in2.5% milk in TBS overnight at 4°C,or with Rabbit polyclonal beta Actin βactin antibody (1:2000; Abcam Inc., ab8227)or with Rabbit polyclonal Anti-TNF alpha (1:2000 ab66579 Abcam). After washing, the membranes were incubated with horseradish peroxidase-conjugated secondary antibody (1:5000; Abcam Inc., ab8227) for one hour and were visualized by TMB solution (Sigma T0565). The relative expression of proteins was quantified by densitometry scanning of blots with ImageJ software.

Statistical Analysis

In the current study, all values were expressed as mean ± SEM. The analyses of data between groups

were performed using one way ANOVA followed by Tukey post hoc test analysis and in some cases, the nonparametric tests of Kruskal Wallis and Mann-Whitney were applied. In all states, P<0.05 was considered to be statistically significant.

Results

The results indicated that STZ injection (50 mg/kg) induced hyperglycemia in rats and after 6 weeks the blood glucose level reached 509.8 ± 16.18 mg/dl in the Hyperglycemic group. In the Hyperglycemic-treated group that received daily AXT (20mg/kg) over 6 weeks the blood glucose reached 568 ± 15 mg/dl. This result showed that AXT could not prevent the elevation in blood glucose (Figure 1). There was no significant difference in blood glucose levels between the control group (126.4 ± 2 mg/dl) and treated-control group (124.16 ± 2.5 mg/dl) that received AXT. Changes in body weight during the six week study period were compared with the initial weight. There was an increment of approximately 40% in the control group from (198.83 ± 2.2 g) to (272.8 ± 3 g). In the Hyperglycemic group weights did not change from the beginning (221.45 ± 3.7 gr) to the end of study period (225.85 ± 5.35 gr) but in the Hyperglycemic-treated group slightly increase occurred (Figure 2).

The Glutathione contents in the rat›s retina in four groups illustrated the minimum amount of GSH contents in the Hyperglycemic group (29.76 ± 4.91 pMol/mg) which was significantly lower than the control group (212.89 ± 72.75). The amount of GSH increased prominently in the Hyperglycemic treated group (133.8 ± 65.10 pMol/ mg) however, this amount was lower than the control group (± SEM 72.75 pMol/ mg) (Table 1).

The superoxide dismutase (SOD) activities in the retina of four groups showed more significant activities in the Hyperglycemic group (15.52 ± 1.36 mU/

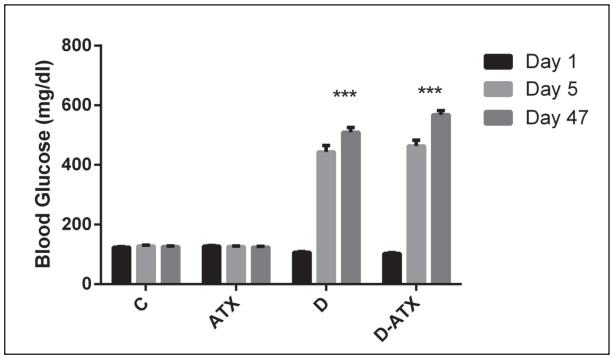

Figure1. Changes in blood glucose
No changes were observed during days 1,5 and 47 in control group and ATX treated group, STZ increased blood glucose up to 506 (mg/dl) in hyperglycemic or D group. ATX treatment could not prevent the glucose elevation (D-ATX). The significant increment was observed 5 days after ingection of STZ. *** represents P<0.0001.

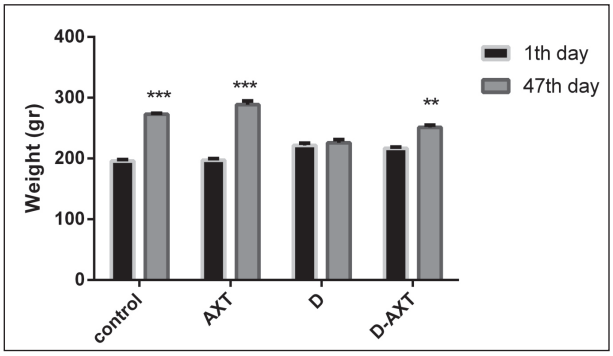

Figure2. Changes in weight
The significant increase were observed in control and ATX treated groups.no increment was seen in hyperglycemic(D) rats during 47 days but ATX treatment could induce weight gain in them (D-ATX). *** P<0.0001, **P<0.001.

Table 1. The amount of CAT, GSH, SOD, and MDA in Different Groups

	CAT (mu/mg)	GSH (pMol/mg)	SOD (mu/mg)	MDA (nMol/mg)
Control	0.06 ± 0.008	212.89 ± 72.75	2.62 ± 0.37	2.38 ± 0.105
ATX	0.2 ± 0.059**	130.65 ± 22.9	11.47 ± 3.21*	2.37 ± 0.106
D	0.036 ± 0.006*	29.76 ± 4.91*	15.52 ± 1.36*	2.86 ± 0.15*
D-ATX	0.096 ± 0.026#	133.80 ± 65.10#	19.17 ± 1.56*	2.64 ± 0.12

The Catalase(CAT), Superoxide dismutase(SOD) activity and Glutathione (GSH), Malondialdehyde (MDA) content in control, control- treated (ATX), ,Hyperglycemic (D) and Hyperglycemic treated (D-ATX) groups.**p<0.01,*p<0.05 compare with control,# p<0.05 compare between D and D-ATX.

mg) compared with the control group (2.62 ± 0.377 mU/mg). However, the activity of SOD in the Hyperglycemic rats that were treated with AXT (19.17 ± 1.562 mU/mg) was higher than the Hyperglycemic group (Table 1).

The measurement of catalase enzyme activity showed that diabetes decreased the activity of catalase in the Hyperglycemic group (0.036 ± 0.006 mU/ mg) compared with control group (0.06 ± 0.008 mU/ mg). Treatment with AXT significantly increased catalase activity in the hyperglycemic-treated group (0.096 ± 0.026 mU/mg). Interestingly, treatment with AXT in control-treated group significantly increased the catalase enzyme activity (0.2 ± 0.059mU/ mg) (Table1).

The Malonaldehyde (MDA) contents in the retinal tissue of rats in the four groups showed that the MDA contents were higher in the Hyperglycemic group (2.86 ± 0.15 nMol/mg) compared with the control group (2.38 ± 0.105 nMol/mg protein) ($P< 0.05$). In spite of the reduction of MDA contents in Hyperglycemic treated group (2.86 ± 0.124 nMol/mg) it was not significant compared with the Hyperglycemic group.

The Histopathological H&E staining showed six layers of retinal tissue respectively: the photoreceptor layer, outer nuclear, outer plexiform, inner nuclear, inner plexiform and ganglionic cell layer in four groups of experiment. Increased permeability and edema were visible in the ganglionic cell layer (RGC) of the retina in the Hyperglycemic group (Figure 3a-f). One case of vitreous humor hemorrhage in the hyperglycemic group is shown in Figure 3f.

The Immunohistochemistry (IHC) assessment showed some dilated vessels in RGC layer of the retinal tissue in the both hyperglycemic and treated Hyperglycemic groups. However, vasodilatations were severe in the hyperglycemic group than the treated hyperglycemic group (Figure 4). Quantitated measuring of vessels area in RGC layer indicated that there were significant increases in the cross-section of the vessels of hyperglycemic rats (4807 ± 731 μm^2) in comparison with control rats (1973.6 ± 200 μm^2) and treatment with Astaxanthin could repair this impairment (2480±437 μm^2) (Figure 5).

The results of Western Blot analysis for the VEGF and TNF-α proteins showed no expression in the con-

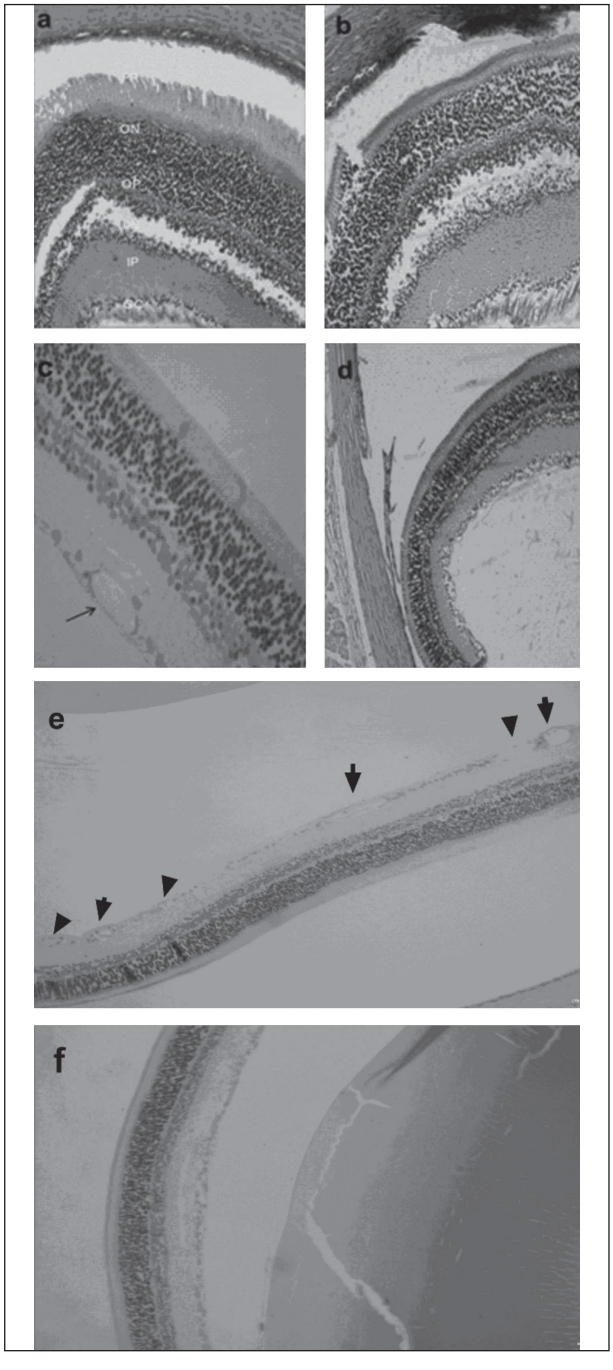

Figure3. Pathological signs
H&E staining revealed the six layers of retina in all groups, a) no specific pathologic sign were observed in control (a) and ATX treated (b) groups. In hyperglycemic group the arrows indicated the inflammation and vasodilation in ganglionic cell layer (c) (e). (f) represented the significant hemorrhage in vitreous of diabetic group. No obvious pathologic signs were observed in hyperglycemic treated with astaxanthin cases (d). Retinal layers: Fotoreceptor cells (FC), outer nuclear (ON), outer plexiform (OP), inner nuclear (IN), inner plexiform (IP) Magnification: a-d 400X and e-f 100X.

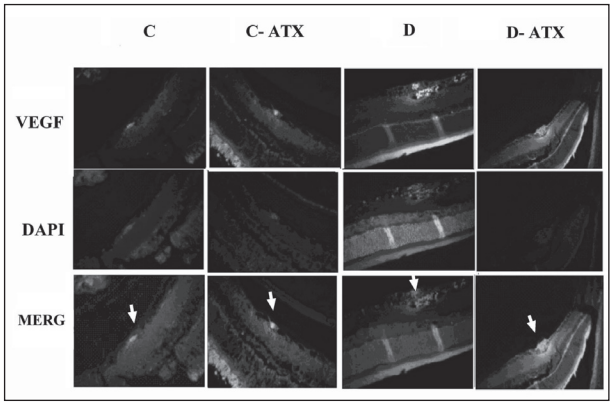

Figure 4. RGC vessels vasodilation
Immunofluorescence staining indicated severe dilation in vessels in RGC layer of hyper glycemic rats (D) (arrows) in upper trace, DAPI staining represent RBC locations in middle trace, merge of tow staining in lower trace. In all images the magnification = 100X.

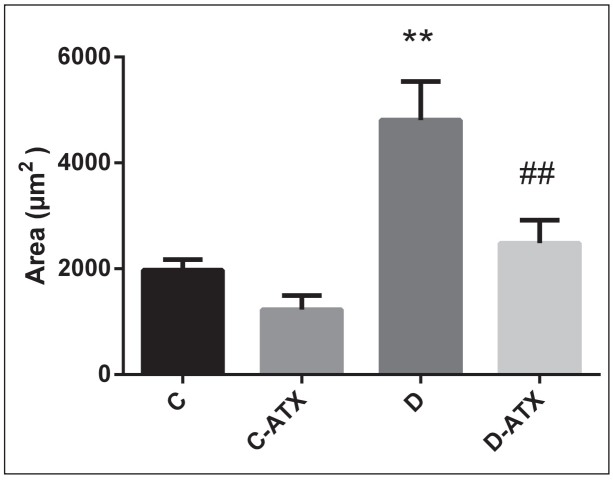

Figure 5. Area measurement of vessels
Counting the RGC vessels area represented increment in their dimension in hyperglycemic(D) rats compare with control and control treated with Astaxanthin (ATX) groups, **p<0.001, treatment with ATX in hyperglycemic rats showed significant reduction of vessels dimension, ## P<0.01.

trol and Astaxanthin treated animals but elevation in the expression of these two proteins in retinal tissue of hyperglycemic groups were prominent. Although Astaxanthin treatment could prevent the elevation of TNF-α in hyperglycemic condition but it could not significantly prevent the expression of VEGF protein in retinal tissue (Figure 6 a, b, c).

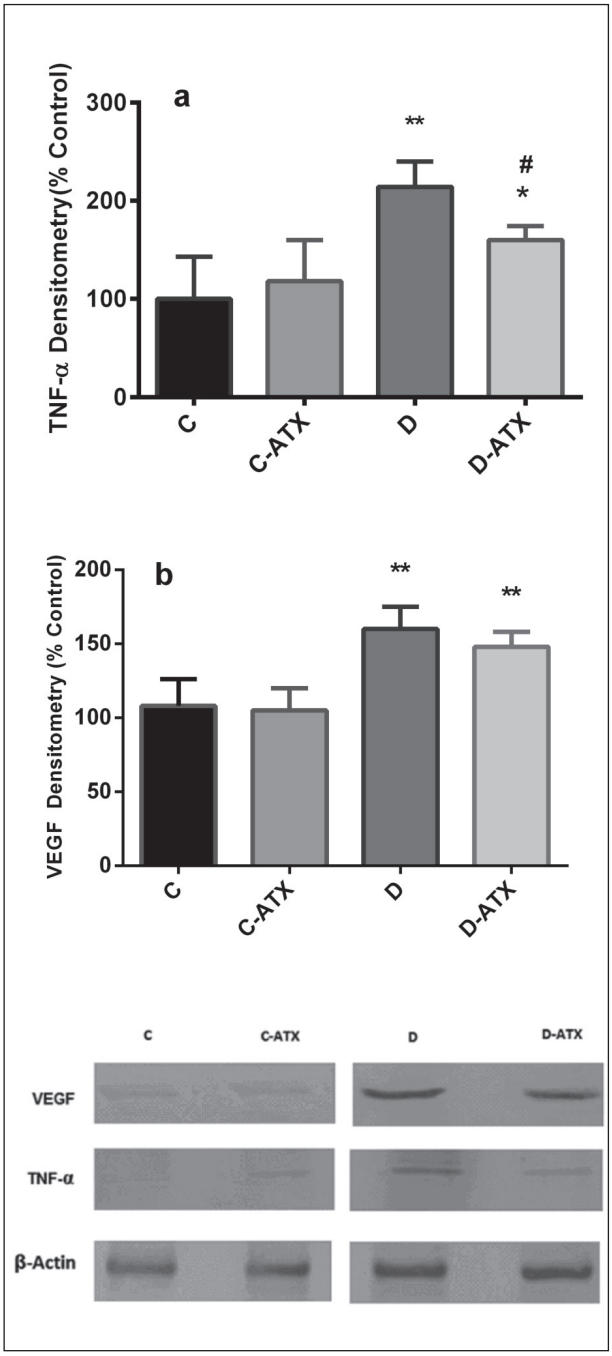

Figure 6. Expression of VEGF and TNF α
(a) Densitometry analysis of VEGF expression indicated significant increase in hyperglycemic group (D) (** p<0.01). The decrease in hyperglycemic treated (D-ATX) group in comparison with hyperglycemic was not significant. (b) The TNF-α as an inflammation marker were increased in hyperglycemic group (** p<0.01 * p<0.05) There was significant decrease with ATX treatment (D-ATX) compare with hyperglycemic group (D) (# p<0.05). The images of western blot membranes were demonstrated in below.

Discussion

In the current study treatment of hyperglycemic rats with Astaxanthin could not prevent the elevation of blood glucose but it could prevent weight loss in diabetic animals. In consistency with other studies, there is no evidence for Astaxanthin as a decreasing blood glucose element. This attributes to the correction of metabolic disorder which is induced by STZ or it aims to the adverse effect of Astaxanthin on insulin resistance which has been mentioned in other studies (21).

According to our results, in hyperglycemic conditions, there were increase in SOD and decrease in CAT and GSH activity or amounts. Previous studies demonstrated that the activity of complex III in mitochondria decreases in hyperglycemic condition. In this condition, the action of electrons transportation in the electron transport chain in mitochondria are reversed and superoxide anions will be produced (22). Overexpression of superoxide dismutase (SOD) in the mitochondria of retinal cells in hyperglycemic condition prevents the harmful effects of superoxide production (23). In diabetes glutathione content decrease and increase in expression of SOD by mitochondria has little effect on the reduction of GSH (23). In normal condition the activities of these three antioxidants are essential in decreasing the harmful effects of free radicals in hyperglycemic conditions.

Xanthophyll carotenoids, AXT and lutein increased the levels of antioxidant enzymes in the ocular tissues of STZ induced hyperglycemic rats (23). Some studies confirm that potency of AXT to remove superoxide radicals is higher than other antioxidants such as vitamin E (24). Related to AXT molecular structure it can eliminate free radicals with three mechanisms which include oxidation, hydrogen abstraction, and electron transfer. However, AXT does not exists in the retinal tissue but crosses easily through the blood-retinal barrier and protects the ganglionic cells from oxidative stress (25). This study demonstrated elevation of malondialdehyde level in hyperglycemic groups. In vitreous fluid, the ROS elevation is concurrent with severity of diabetes (26). It is probable that the increase of ROS causes peroxidation lipid, protein, and carbohydrate in two hyperglycemic groups. Also, NADPH oxidase induces Xanthine oxidase which in turn reduces GSH level and finally antioxidant defense mechanisms are disturbed (27).

At the hyperglycemic condition, ROS reacts to the double bond of free fatty acids and accordingly MDA is produced (19) it attacks to biological substances then advanced lipid peroxidation end products appear in the cells. All these events led to the creation of pseudo hypoxia in retinal tissue. Hypoxia is the strong operating of VEGF expression (28). It is an important factor to vasodilatation and increases permeability in the vasculature network within the inner retina (29). In addition, the ROS stimulates inflammatory response (30). It is demonstrated that TNF-α has a role in hyperglycemic vascular outflow and in the complication of hyperglycemic retinopathy and the AXT inhibits pre inflammatory cytokine via inhibition NF-βB expression (31). Also, it has been shown the suppressive effect of AXT in ocular hypertension (32). Other studies demonstrated that TNF-α and VEGF increased in two weeks after the beginning of diabetes and the inhibition of TNF-α decreased blood retinal breakdown in retinal tissue (33). Our study demonstrated the same increase of VEGF and TNF-α after six weeks of the beginning of Hyperglycemia. Although treatment with AXT could prevent the expression of TNF- α in the hyperglycemic group but the decrement of VEGF was not significant in this group. As the study of Hashimato H. et al in 2016 in spite of positive correlation between total hydroperoxide and VEGF in aqueous humor in diabetic patients but AXT treatment did not induce significant changes in VEGF level in aqueous humor (33).

Conclusion

In this study we revealed that, during hyperglycemia (47 days) the antioxidant capacity in retinal tissue decreased and vasodilation and inflammation in RGC layer were induced. The VEGF expression was also increased in this tissue. Treatment with the Astaxanthin during experience some deal could prevent antioxidant deficiency and helped to repair of vasodilation. This may be due to its first antioxidant and anti-inflammatory effects and not directly through reduction in VEGF expression. The unaffected expres-

sion of VEGF with Astaxanthin treatment may be related to insufficiency of treatment time or to the stage of pathologic condition and also related to a specific sampling site.

References

1. Organization WH. Global report on diabetes: World Health Organization; 2016.
2. Kowluru RA, Kowluru A, Mishra M, Kumar B. Oxidative stress and epigenetic modifications in the pathogenesis of diabetic retinopathy. Prog Retin Eye Res. 2015;48:40-61.
3. Yau JW, Rogers SL, Kawasaki R, Lamoureux EL, Kowalski JW, Bek T, et al. Global prevalence and major risk factors of diabetic retinopathy. Diabetes Care. 2012;35(3):556-64.
4. Kowluru RA, Kanwar M. Oxidative stress and the development of diabetic retinopathy: contributory role of matrix metalloproteinase-2. Free Radical Biology and Medicine. 2009;46(12):1677-85.
5. Yamagishi S, Amano S, Inagaki Y, Okamoto T, Koga K, Sasaki N, et al. Advanced glycation end products-induced apoptosis and overexpression of vascular endothelial growth factor in bovine retinal pericytes. Biochem Biophys Res Commun. 2002;290(3):973-8.
6. Rangasamy S, McGuire PG, Das A. Diabetic retinopathy and inflammation: novel therapeutic targets. Middle East Afr J Ophthalmol. 2012;19(1):52-9.
7. Joussen AM, Murata T, Tsujikawa A, Kirchhof B, Bursell SE, Adamis AP. Leukocyte-mediated endothelial cell injury and death in the diabetic retina. Am J Pathol. 2001;158(1):147-52.
8. Njie-Mbye YF, Kulkarni-Chitnis M, Opere CA, Barrett A, Ohia SE. Lipid peroxidation: pathophysiological and pharmacological implications in the eye. Front Physiol. 2013;4:366.
9. Naziroglu M, Butterworth PJ. Protective effects of moderate exercise with dietary vitamin C and E on blood antioxidative defense mechanism in rats with streptozotocin-induced diabetes. Can J Appl Physiol. 2005;30(2):172-85.
10. Cerezo J, Zuniga J, Bastida A, Requena A, Ceron-Carrasco JP. Conformational changes of beta-carotene and zeaxanthin immersed in a model membrane through atomistic molecular dynamics simulations. Phys Chem Chem Phys. 2013;15(17):6527-38.
11. Bernstein PS, Li B, Vachali PP, Gorusupudi A, Shyam R, Henriksen BS, et al. Lutein, zeaxanthin, and meso-zeaxanthin: The basic and clinical science underlying carotenoid-based nutritional interventions against ocular disease. Prog Retin Eye Res. 2016;50:34-66.
12. Hussein G, Sankawa U, Goto H, Matsumoto K, Watanabe H. Astaxanthin, a carotenoid with potential in human health and nutrition. J Nat Prod. 2006;69(3):443-9.
13. Farasat M, Khavari-Nejad RA, Nabavi SM, Namjooyan F. Antioxidant Activity, Total Phenolics and Flavonoid Contents of some Edible Green Seaweeds from Northern Coasts of the Persian Gulf. Iran J Pharm Res. 2014;13(1):163-70.
14. Grimmig B, Kim SH, Nash K, Bickford PC, Douglas Shytle R. Neuroprotective mechanisms of astaxanthin: a potential therapeutic role in preserving cognitive function in age and neurodegeneration. Geroscience. 2017;39(1):19-32.
15. Bradford MM. A rapid and sensitive method for the quantitation of microgram quantities of protein utilizing the principle of protein-dye binding. Anal Biochem. 1976;72:248-54.
16. Tietze F. Enzymic method for quantitative determination of nanogram amounts of total and oxidized glutathione: applications to mammalian blood and other tissues. Anal Biochem. 1969;27(3):502-22.
17. Winterbourn CC, Hawkins RE, Brian M, Carrell R. The estimation of red cell superoxide dismutase activity. The Journal of laboratory and clinical medicine. 1975;85(2):337-41.
18. HugoAebi B. Isolation, purification, characterization, and assay of antioxygenic enzymes ,Catalase in vitro Methods in Enzymology. 1984;105:121-6.
19. Satoh K. Serum lipid peroxide in cerebrovascular disorders determined by a new colorimetric method. Clin Chim Acta. 1978;90(1):37-43.
20. Puchtler H, Meloan SN, Waldrop FS. Application of current chemical concepts to metal-hematein and -brazilein stains. Histochemistry. 1986;85(5):353-64.
21. Ni Y, Nagashimada M, Zhuge F, Zhan L, Nagata N, Tsutsui A, et al. Astaxanthin prevents and reverses diet-induced insulin resistance and steatohepatitis in mice: A comparison with vitamin E. Sci Rep. 2015;5:17192.
22. Kanwar M, Chan PS, Kern TS, Kowluru RA. Oxidative damage in the retinal mitochondria of diabetic mice: possible protection by superoxide dismutase. Invest Ophthalmol Vis Sci. 2007;48(8):3805-11.
23. Yeh PT, Huang HW, Yang CM, Yang WS, Yang CH. Astaxanthin Inhibits Expression of Retinal Oxidative Stress and Inflammatory Mediators in Streptozotocin-Induced Diabetic Rats. PLoS One. 2016;11(1):e0146438.
24. Pashkow FJ, Watumull DG, Campbell CL. Astaxanthin: a novel potential treatment for oxidative stress and inflammation in cardiovascular disease. Am J Cardiol. 2008;101(10A):58D-68D.
25. Nakajima Y, Inokuchi Y, Shimazawa M, Otsubo K, Ishibashi T, Hara H. Astaxanthin, a dietary carotenoid, protects retinal cells against oxidative stress in-vitro and in mice in-vivo. J Pharm Pharmacol. 2008;60(10):1365-74.
26. Yeh PT, Yang CM, Huang JS, Chien CT, Yang CH, Chiang YH, et al. Vitreous levels of reactive oxygen species in proliferative diabetic retinopathy. Ophthalmology. 2008;115(4):734-7 e1.
27. Kowluru RA, Chan P-S. Oxidative stress and diabetic retinopathy. Experimental diabetes research. 2007;2007.
28. Ferrara N. Vascular endothelial growth factor: basic science and clinical progress. Endocrine reviews. 2004;25(4):581-611.
29. Simo R, Hernandez C, European Consortium for the Early

Treatment of Diabetic R. Neurodegeneration in the diabetic eye: new insights and therapeutic perspectives. Trends Endocrinol Metab. 2014;25(1):23-33.
30. Xue J, Thippegowda PB, Hu G, Bachmaier K, Christman JW, Malik AB, et al. NF-kappaB regulates thrombin-induced ICAM-1 gene expression in cooperation with NFAT by binding to the intronic NF-kappaB site in the ICAM-1 gene. Physiol Genomics. 2009;38(1):42-53.
31. Zhang SX, Wang JJ, Gao G, Shao C, Mott R, Ma JX. Pigment epithelium-derived factor (PEDF) is an endogenous antiinflammatory factor. FASEB J. 2006;20(2):323-5.
32. Cort A, Ozturk N, Akpinar D, Unal M, Yucel G, Ciftcioglu A, et al. Suppressive effect of astaxanthin on retinal injury induced by elevated intraocular pressure. Regul Toxicol Pharmacol. 2010;58(1):121-30.
33. Speranza L, Pesce M, Patruno A, Franceschelli S, de Lutiis MA, Grilli A, et al. Astaxanthin treatment reduced oxidative induced pro-inflammatory cytokines secretion in U937: SHP-1 as a novel biological target. Mar Drugs. 2012;10(4):890-9.

Correspondence:
Farideh Bahrami
Assistant professor, Department of Physiology and Medical physics, Faculty of Medicine, Baqiyatallah University of Medical Sciences
Tehran, Iran
Fax: 0098 21 88620843
Tel: 0098 21 82483420
E-mail: F.Bahrami@bmsu.ac.ir

View publication stats