



Available online at www.sciencedirect.com

ScienceDirect

journal homepage: www.elsevier.com/locate/ajur



Original Article

Minimally invasive open dismembered pyeloplasty technique: Miniature incision, muscle-splitting dissection, and nopelvis reduction in children

Farzaneh Sharifiaghdas^a, Mahboubeh Mirzaei^{b,*},
Azar Daneshpajoo^b, Shahin Abbaszadeh^c

^a Urology-Nephrology Research Center, Labbafinejad Hospital, Shahid Beheshti University of Medical Sciences, Tehran, Iran

^b Department of Urology, Shahid Bahonar Hospital, Kerman University of Medical Sciences, Kerman, Iran

^c Urology-Nephrology Research Center, Baqiyatallah University of Medical Sciences, Tehran, Iran

Received 5 March 2017; received in revised form 18 April 2017; accepted 27 September 2017

Available online 11 August 2018

KEYWORDS

Ureteropelvic junction obstruction;
Open dismembered pyeloplasty;
Miniature incision;
Children

Abstract *Objective:* To report the outcomes and complications of open dismembered Anderson-Hynes pyeloplasty with miniature incision in treating children's ureteropelvic junction obstruction.

Methods: Between March 2007 and April 2011, 109 children with a mean age of 2 years and 8 months old with ureteropelvic junction obstruction underwent open dismembered pyeloplasty. Clinical manifestations, radiographic assessments, incision size, surgery time, hospital stay, and complication rate were recorded. All patients had a documented ureteropelvic junction obstruction (having T1/2 more than 20 min in diethylenetriaminepentaacetic acid [DTPA] scan) with symptomatic stenosis or decreased kidney function (differential function <40%). Pyeloplasty was done by a retroperitoneal flank approach with miniature incision without pelvis reduction. One surgeon did all the surgeries. Success rate and complications were assessed in a 3-year follow-up.

Results: Mean surgery time was 52 min (47–60 min). Incision size was 18–28 mm. Mean hospital stay was 3 days (2–8 days). The surgery was successful in 98.2% of patients with a mean follow-up time of 36 months (success was defined as disappearance of symptoms, if present, with improved ultrasound imaging results or Reno graphic parameters). The complication rate was 7.33%, including urinary leakage, double-J urethral stent dislocation and infection.

* Corresponding author.

E-mail address: mirzaeimahboubeh@yahoo.com (M. Mirzaei).

Peer review under responsibility of Second Military Medical University.

<https://doi.org/10.1016/j.ajur.2018.08.001>

2214-3882/© 2019 Editorial Office of Asian Journal of Urology. Production and hosting by Elsevier B.V. This is an open access article under the CC BY-NC-ND license (<http://creativecommons.org/licenses/by-nc-nd/4.0/>).

Conclusion: Open dismembered pyeloplasty is a safe, technically feasible and effective therapy in treatment of children's ureteropelvic junction obstruction. It takes a short time to do, requires a small incision and has few complications and a short recovery period.

© 2019 Editorial Office of Asian Journal of Urology. Production and hosting by Elsevier B.V. This is an open access article under the CC BY-NC-ND license (<http://creativecommons.org/licenses/by-nc-nd/4.0/>).

1. Introduction

Ureteropelvic junction obstruction is a common anomaly of the ureter which disrupts the transfer of urine from the kidney pelvis into the ureter. Depending on the patient's age at diagnosis time, clinical manifestations are different. They range from having no symptoms to recurrent pyelonephritis and severe pain, particularly after drinking liquids and kidney failure.

Ureteropelvic junction obstruction is corrected in patients with symptomatic stenosis or decreased kidney function. Open dismembered pyeloplasty is the standard treatment which was introduced by Anderson and Hynes in 1949 [1].

Because of post-surgery pain and morbidity due to the great muscle incision, a large number of minimally invasive procedures were studied for ureteropelvic junction obstruction in the last 2 decades. Some studies had compared open surgery with minimally invasive techniques, such as laparoscopic pyeloplasty and endopyelotomy [2,3]. But these minimally invasive techniques have some limiting factors, such as lower success rate and higher risk of bleeding in endopyelotomy [4], more difficult techniques, longer learning curve, and the need for expensive equipment in laparoscopic pyeloplasty [5,6].

This retrospective study has analyzed the results of doing open dismembered pyeloplasty on 109 children with a 3-year follow-up. We did pyeloplasty with a very small incision in the flank and only muscle dissection.

2. Patients and methods

Between March 2007 and April 2011, a total of 109 children who had ureteropelvic junction obstruction underwent open dismembered pyeloplasty with miniature incision and without pelvic reduction in our centre in Kerman city, Iran. All the surgeries had been done after obtaining the approval of ethics committee of Kerman University of Medical Sciences, Kerman, Iran. All parents of the participating children signed an informed consent before their child entered the study. Inclusion criteria were: 1) Being younger than 14 years old, 2) having body mass index less than 30 kg/m², 3) having documented ureteropelvic junction obstruction (T1/2 more than 20 min in diethylene-triaminepentaacetic acid [DTPA] scan) with symptomatic stenosis or decreased kidney function (differential kidney function <40%). The exclusion criteria were having a differential kidney function less than 10% and a history of failed pyeloplasty.

All pre-surgery data including sex, age, symptoms, X-ray reports, plus post-surgery complications, and re-

admissions because of complications were recorded. One pediatric urologist did all the surgeries through the 12th rib tip miniature incision without cutting the muscles and only dissecting them. The stenosis was removed and after ureter spatulation, anastomosis was done by 5-0 vicryl simple suture.

Anderson–Hynes dismembered pyeloplasty was done with an extraperitoneal approach. Double-J stent was placed and an extra-kidney drain was inserted in the miniature incision (Fig. 1). The drain was removed when its output was less than 30 mL per day. Double-J stent was removed after 4 weeks under intravenous sedation. Two weeks after double-J stent removal, ultrasound imaging was done. Three to 6 months after surgery, DTPA scan was done. Then the patients underwent ultrasound imaging annually and nuclear scan was done if severity of hydronephrosis had risen in their ultrasound. Society of Fetal Ultrasound's system was used for hydronephrosis grading, which included mild (grades 1 and 2), moderate (grade 3), and severe (grade 4).

3. Results

There were 81 boys (74.3%) and 28 girls (25.7%). Their mean age was 2 years and 8 months old (2 months–14 years old). The most common clinical manifestations were antenatal hydronephrosis (69.0%, 75/109), flank pain (12.8%, 14/109), urinary tract infection (11.0%, 12/109), hematuria (including 3.7% [4/109] of microscopic and 1.8% [2/109] of macroscopic hematuria), lack of weight gain (0.9%, 1/109), and difficult voiding (0.9%, 1/109). Of them 5.5% (6/109) were asymptomatic and were detected accidentally in the post-natal ultrasound imaging.

They were followed up if hydronephrosis was seen on ultrasound imaging after birth. Among the studied children, 94.5% (103/109) had severe hydronephrosis on pre-surgery ultrasound imaging. In 38.5% (42/109) of cases it was associated with a reduced parenchyma thickness. The rest had mild-to-moderate degrees of hydronephrosis. Pre-surgery intravenous pyelography's showed severe hydronephrosis in 82 children (75.2%) with no drain on 3 and 6 h delay graphs. Others had milder degrees of hydronephrosis with delayed discharge. Pyelography was not performed in 10 children and they only received pre-surgery DTPA scan.

In the kidney scan, all patients had obstruction (T1/2 > 20 min) with reduced kidney function to less than 40%. Mean surgery time was 52 min (47–60 min). Incision size was 18–28 mm. Aberrant vessel was observed in eight patients and transposed during Anderson–Hynes dismembered pyeloplasty. Mild side effects included temporary urinary tract

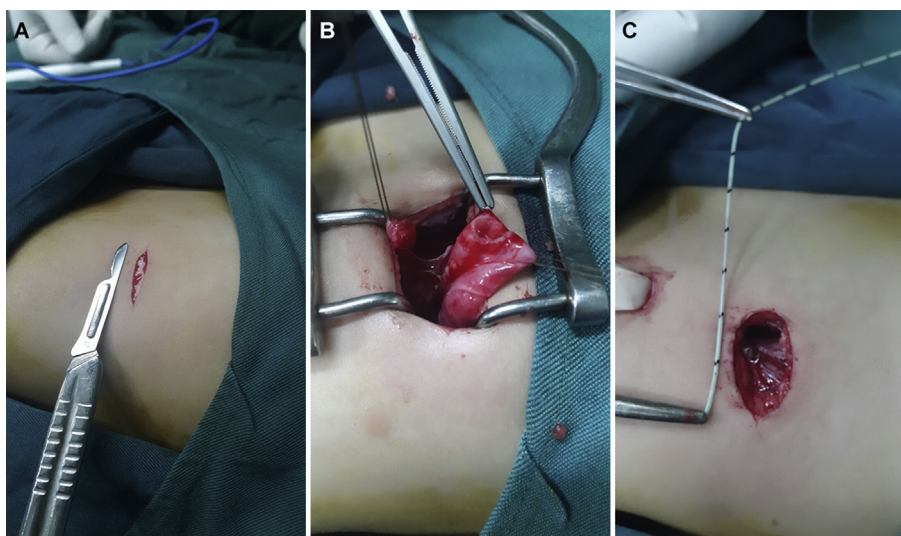


Figure 1 Open dismembered Anderson–Hynes pyeloplasty with miniature incision. (A) Miniature incision without cutting the muscles through the 12th rib tip; (B) The stenosis was removed and anastomosis was done after ureter spatulation; (C) Incision size was 18–28 mm.

infection (2.8%, 3/109), urinary leakage (1.8%, 2/109), and double-J ureteral stent dislocation (2.8%, 3/109).

Major complications were not observed. Mean hospital stay was 3 days (up to 8 days because of drain output). Double-J stent was dislocated in three patients. In two of them distal end of double-J was in the ureter. It did not reach the bladder and did not need any more work but we were forced to do distal ureteroscopy to remove the stent. In one girl double-J completely came out 1 day after surgery and because of her persistent fever and high drain output, another double-J stent was replaced. In two children, because of persistent urine leakage (drain output was >30 mL per day), hospital stay was longer (up to 8 days) and drain was taken out after 8 days.

The surgery was successful in 98.2% (107/109) of patients with a mean follow-up of 36 months (success was defined as disappearance of symptoms, if present, with improved ultrasound imaging results or Reno graphic parameters). The obstruction was observed only in two patients and they required redoing the pyeloplasty. They had been operated first time when they were younger than 3 months old and one of them had a low birth weight. Of all the patients 63.3% (69/109) were asymptomatic and had normal ultrasound imaging results (no hydronephrosis). The rest had residual non-obstructive hydronephrosis in ultrasound. The main issue with no pelvic reduction was the residual post-surgery (non-obstructive) hydronephrosis.

4. Discussion

Depending on the patient's age at diagnosis time, clinical manifestations of ureteral pelvic junction obstruction are different and vary from having no symptom to severe pain, particularly after drinking liquids, recurrent pyelonephritis and kidney failure. Prenatal ultrasound imaging can diagnose many of its cases before birth. After birth, pain and vomiting are the most common symptoms. However, hematuria and urinary tract infection might be seen. Rarely, some patients

have complications such as stones, enlarged kidney trauma, hypertension or abdominal mass. Correction of ureteropelvic junction obstruction has been done in patients with symptomatic stenosis or reduced kidney function. Open dismembered pyeloplasty is its standard treatment [1].

Because of muscle cutting complications in a flank incision, a large number of minimally invasive procedures have been studied in the past 2 decades for ureteropelvic junction obstruction such as endopyelotomy, balloon dilation, laparoscopy, retroperitoneoscopy, robotic approaches and one-trocar assisted pyeloplasty [3,7–9]. Endopyelotomy has higher complications and lower success rate compared to open and minimally invasive pyeloplasty and crossing vessels should be excluded before doing endopyelotomy [10].

In 1995, Peters and colleagues [11] reported the first pediatric laparoscopic pyeloplasty. According to Anderson and Hynes [1] and Troxel and colleagues [12] pyeloplasty is still the standard surgery for ureteropelvic junction obstruction with high long-term success rate of over 95%.

In 2014, a study on 6006 children younger than 18 years old in different hospitals compared minimally invasive procedures with open pyeloplasty. High-volume hospitals that did open pyeloplasty had the best outcomes. However, high-volume hospitals that did minimally invasive procedures had better results compared to low-volume hospitals that did open pyeloplasty [13].

In three studies that compared laparoscopic and open pyeloplasty in children, surgery time was higher but hospital stay and postoperative analgesic consumption were lower in laparoscopic pyeloplasty [14–16]. Of course, in a randomized clinical trial by Sorensen et al. [17], these two variables, including hospital stay and postoperative analgesic consumption, were equal in laparoscopic and open pyeloplasty.

According to Valla et al. [18] laparoscopic pyeloplasty is as effective and safe as open pyeloplasty but its benefits are more obvious in children older than 4 years old. This technique is difficult to do and teach. In a study in Toronto in 2013 about costs of pyeloplasty, laparoscopic pyeloplasty

was more expensive than open pyeloplasty because of longer surgery duration [19].

According to a review article in 2015, regardless of the low invasiveness, generally the ideal approach of pyeloplasty in children and adults is the one which has higher success, lower complication rates, and is easier to learn. Because of the lack of evidence-based randomized trials and bias of many important results, it seems that laparoscopic pyeloplasty can be a good alternative to open surgery in adults. But it has no significant benefits compared to open surgery in children [20].

If open dismembered pyeloplasty is done with a miniature incision and without cutting the flank muscle in children, it can be regarded as a minimally invasive procedure with high success in terms of incision size, hospital stay and recovery period.

5. Conclusion

Minimally invasive open dismembered pyeloplasty is a safe, technically feasible and effective therapy in treating children's ureteropelvic junction obstruction. It is done in short duration with small incision, few complications, and short convalescence.

Author contributions

Study concept and design: Frazaneh Sharifiaghdas, Mahboubeh Mirzaei.

Data acquisition: Mahboubeh Mirzaei, Azar Daneshpajouh.

Drafting of manuscript: Shahin Abbaszadeh, Mahboubeh Mirzaei.

Critical revision of the manuscript: Frazaneh Sharifiaghdas, Mahboubeh Mirzaei.

Conflicts of interest

The authors declare no conflict of interest.

Acknowledgement

The authors would like to thank Muhammed Hussein Mousavinasab for his sincere cooperation in editing this text. They also thank Nasrin Borumandnia for analyzing the data.

References

- [1] Anderson JC, Hynes W. Retrocaval ureter; a case diagnosed pre-operatively and treated successfully by a plastic operation. *Br J Urol* 1949;21:209–14.
- [2] Cantone N, Destro F, Ruggeri G, Lima M. One-trocar-assisted pyeloplasty (OTAP). In: Lima M, Manzoni G, editors. *Pediatric urology*. Milano: Springer-Verlag; 2015. p.103–7.
- [3] Monn MF, Bahler CD, Schneider EB, Whittam BM, Misseri R, Rink RC, et al. Trends in robot-assisted laparoscopic pyeloplasty in pediatric patients. *Urology* 2013;81:1336–41.
- [4] Baldwin DD, Dunbar JA, Wells N, McDougall EM. Single-center comparison of laparoscopic pyeloplasty, acucise endopyelotomy, and open pyeloplasty. *J Endourol* 2003;17:155–60.
- [5] Hemal AK, Goel R, Goel A. Cost-effective laparoscopic pyeloplasty: single center experience. *Int J Urol* 2003;10:563–8.
- [6] Singh V, Garg M, Sharma P, Sinha RJ, Kumar M. Mini incision open pyeloplasty—Improvement in patient outcome. *Int Braz J Urol* 2015;41:927–34.
- [7] Wang X, Zhang Z, Peng N, Liu C. Retroperitoneal laparoscopic versus open dismembered pyeloplasty for ureteropelvic junction obstruction. *J X Ray Sci Technol* 2013;21:429–39.
- [8] Gao ZL, Shi L, Yang MS, Wang L, Yang DD, Sun DK, et al. Combination of laparoscopic and open procedure in dismembered pyeloplasty: report of 51 cases. *Chin Med J (Engl)* 2006;119:840–4.
- [9] Gao ZL, Wu JT, Yang DD, Shi L, Men CP, Wang L. Retroperitoneoscopic right living donor nephrectomy. *Chin Med J (Engl)* 2007;120:1270–3.
- [10] Corbett HJ, Mullassery D. Outcomes of endopyelotomy for pelviureteric junction obstruction in the paediatric population: a systematic review. *J Pediatr Urol* 2015;11:328–36.
- [11] Peters CA, Schluskel RN, Retik AB. Pediatric laparoscopic dismembered pyeloplasty. *J Urol* 1995;153:1962–5.
- [12] Troxel S, Das S, Helfer E, Nugyen M. Laparoscopy versus dorsal lumbotomy for ureteropelvic junction obstruction repair. *J Urol* 2006;176:1073–6.
- [13] Sukumar S, Djahangirian O, Sood A, Sammon JD, Varda B, Janosek-Albright K, et al. Minimally invasive vs. open pyeloplasty in children: the differential effect of procedure volume on operative outcomes. *Urology* 2014;84:180–4.
- [14] Bonnard A, Fouquet V, Carricaburu E, Aigrain Y, El-Ghoneimi A. Retroperitoneal laparoscopic versus open pyeloplasty in children. *J Urol* 2005;173:1710–3.
- [15] Penn HA, Gatti JM, Hoestje SM, DeMarco RT, Snyder CL, Murphy JP. Laparoscopic versus open pyeloplasty in children: preliminary report of a prospective randomized trial. *J Urol* 2010;184:690–5.
- [16] Huang Y, Wu Y, Shan W, Zeng L, Huang L. An updated meta-analysis of laparoscopic versus open pyeloplasty for ureteropelvic junction obstruction in children. *Int J Clin Exp Med* 2015;8:4922.
- [17] Sorensen MD, Delostrinos C, Johnson MH, Grady RW, Lendvay TS. Comparison of the learning curve and outcomes of robotic assisted pediatric pyeloplasty. *J Urol* 2011;185:2517–22.
- [18] Valla JS, Breaud J, Griffin SJ, Sautot-Vial N, Beretta F, Guana R. Retroperitoneoscopic vs. open dismembered pyeloplasty for ureteropelvic junction obstruction in children. *J Pediatr Urol* 2009;5:368–73.
- [19] Moore K, Lorenzo AJ, Turner S, Bägli DJ, Pippi Salle JL, Farhat WA. Prospective cost analysis of laparoscopic vs. open pyeloplasty in children: single centre contemporary evaluation comparing two procedures over a 1-year period. *Can Urol Assoc J* 2013;7:94–8.
- [20] Ekin RG, Celik O, Ilbey YO. An up-to-date overview of minimally invasive treatment methods in ureteropelvic junction obstruction. *Cent Eur J Urol* 2015;68:245–51.