

Case report

Choroidal neovascularization following photorefractive keratectomy

Hamidreza Torabi*, Seyed-Hashem Daryabari

Department of Ophthalmology, Baqiyatallah University of Medical Sciences, Tehran, Iran

Received 4 August 2016; revised 22 August 2016; accepted 24 August 2016

Available online 9 September 2016

Abstract

Purpose: To describe a case of choroidal neovascularization (CNV) following photorefractive keratectomy (PRK) to correct myopia.

Methods: We performed PRK in both eyes of a 20-year-old girl to correct myopia. Refractive error was $-4.75 -2.25 \times 5$ in the right eye and $-5.00 -1.25 \times 180$ in the left eye.

Metamorphopsia was noticed by the patient in the right eye one month after the surgical procedure. The patient was referred 3 months later when visual loss happened.

Results: Fluorescein angiography and Optical Coherence Tomography (OCT) were performed which were compatible with CNV.

After three monthly intravitreal bevacizumab injections, sub-retinal hemorrhage and intraretinal fluid resolved, but subretinal scar remained without any visual acuity improvement.

Conclusions: It seems that CNV may occur after PRK in myopic eyes. Also, refractive surgeons should consider CNV development in cases with visual compliant or metamorphopsia following PRK.

Copyright © 2017, Iranian Society of Ophthalmology. Production and hosting by Elsevier B.V. This is an open access article under the CC BY-NC-ND license (<http://creativecommons.org/licenses/by-nc-nd/4.0/>).

Keywords: Photorefractive keratectomy; Choroidal neovascularization; Myopia; Bevacizumab

Introduction

Photorefractive keratectomy (PRK) is a widely used method to treat myopia.¹ Most complications of this technique involve the anterior segment. The possible effects of PRK on the posterior segment are not well recognized. Choroidal neovascularization (CNV) development following excimer laser refractive surgery is rare. There are some reports of CNV after laser in situ keratomileusis (LASIK) surgery, but to our knowledge, only one case of CNV following PRK has been reported.²

Here we report a case of CNV formation following PRK in a patient with myopia.

* Corresponding author. Department of Ophthalmology, Baqiyatallah University of Medical Sciences, Mollasadra Street, Vanak Square, Tehran, Iran.

E-mail address: Dr_Hamidrezatorabi@yahoo.com (H. Torabi).

Peer review under responsibility of the Iranian Society of Ophthalmology.

Case report

PRK was performed in both eyes of a 20-year-old girl to correct myopia. The procedure was performed at refractive surgery center of Baqiyatallah Hospital, Tehran, Iran. A pre-operative examination including refraction and best corrected visual acuity (BCVA) measurements, slit-lamp examination, intraocular pressure (IOP) measurement, and funduscopy with dilated pupil was performed by the surgeon and reported as normal. Preoperative refractive error was $-4.75 -2.25 \times 5$ and $-5.00 -1.25 \times 180$ in the right and left eye, respectively. BCVA was 20/20 in both eyes.

PRK surgery was performed by a Bausch & Lomb Technolas 217z excimer laser. Alcohol-assisted corneal epithelium debridement was done, and mitomycin C was used at the end of the procedure.

One month after surgical procedure, metamorphopsia developed in the right eye, and visual acuity reduction happened

3 months later. There was no history of preoperative or post-operative ocular trauma. The patient was referred to Retina clinic of the Baqiyatallah Hospital, Tehran, Iran 4 months after PRK. The BCVA was 20/400 in the right eye and 20/20 in the left eye. On fundus examination there was an area of subretinal hemorrhage in the para foveal area associated with macular edema of the right eye. Fluorescein angiography showed para foveal leakage (Fig. 1), and Optical Coherence Tomography (OCT) revealed a hyper-reflective sub-retinal material associated with intraretinal fluid and pigment epithelial detachment (Fig. 2A–C) compatible with CNV.

Although the effect of intravitreal anti vascular endothelial growth factor (anti-VEGFs) in the cases of CNV following excimer laser refractive surgery has not been completely understood, we used 1.25 mg intravitreal bevacizumab (Avastin; Genetech Inc, South San Francisco, California, USA) for treatment. After 3 monthly intravitreal injections, sub-retinal hemorrhage resolved and intraretinal fluid improved, but sub-retinal scar developed (Fig. 3A and B).

One month after the 3rd intravitreal injection, the BCVA was 20/400, and no visual acuity improvement was observed.

Discussion

High myopia has been reported as a major cause of CNV formation (62%) in young patients.³ In the present report, CNV happened in a patient with myopia following PRK. There are multiple reports of CNV following LASIK surgery in myopic eyes. Neo et al reported 3 cases of unilateral CNV after LASIK for high myopia.⁴ Among their patients, the mean spherical equivalent was -11.42 D (range from -6.75 to -20.00 D). They used a combination of intravitreal ranibizumab and photodynamic therapy (PDT) with verteporfin for the treatment. The mean BCVA was 0.44 logMAR and 0.17 logMAR at presentation and after treatment, respectively.

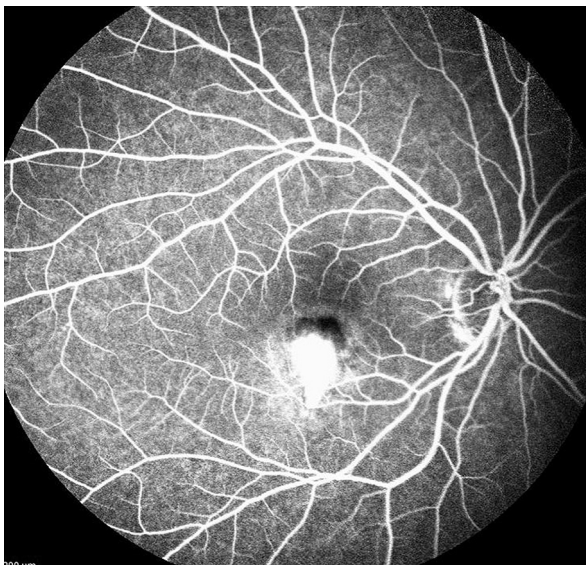


Fig. 1. Fluorescein angiogram 4 months after photorefractive keratectomy (PRK) showed a para foveal Choroidal neovascularization (CNV).

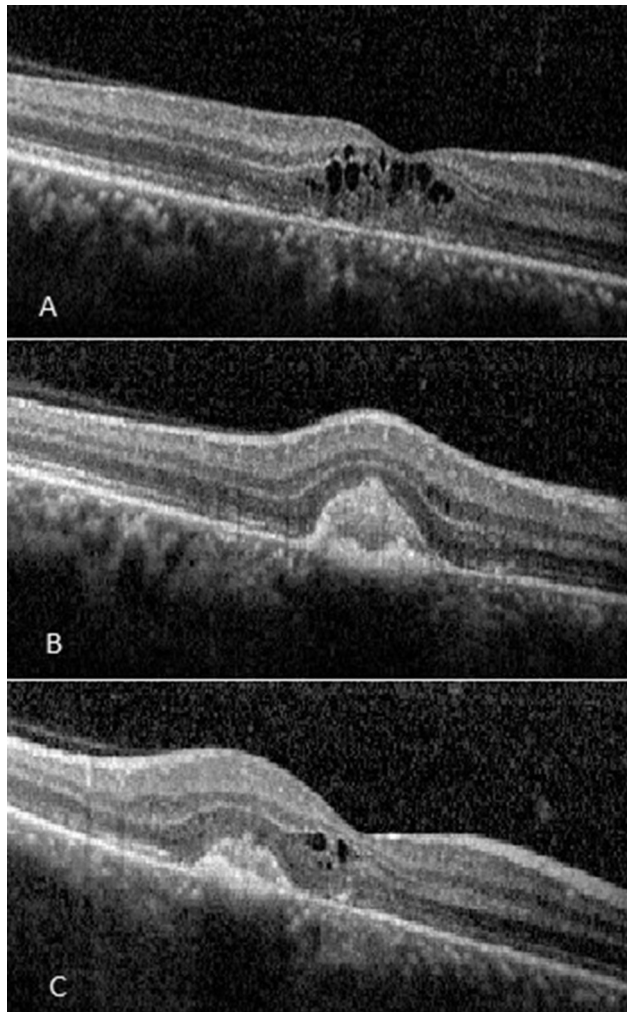


Fig. 2. Pre-treatment Optical Coherence Tomography (OCT) images: OCT section of the macular center showed macular edema (A), and hyper-reflective material in the parafoveal area (B). Oblique OCT section from the lesion (C).

Saeed et al described a case of CNV after LASIK for correction of low myopia.⁵ The refractive error in their patient was -2.75 D in both eyes, and CNV developed in one eye 3 months after surgery.

Although Loewenstein et al described macular hemorrhage in three patients with high myopia (-13.00 to -20 D) after PRK,⁶ to date, there has only been one report of CNV after PRK.² Ruiz-Mareno and colleagues evaluated the incidence of CNV in 5963 eyes undergoing PRK for the correction of myopia. CNV developed in one eye after correction of -12.00 D of myopia 26 months after PRK. They used laser photocoagulation for treatment of CNV.² In another study, the same researchers reported one case of CNV after the same number of PRK surgeries. Therefore, this may represent the same case for both studies.⁷

Progressive elongation of the axial length and degenerative changes of the choroid in highly myopic eyes may cause the linear breaks in Bruch's membrane which are called Lacquer cracks.⁸ Lacquer cracks may be related to development of CNV.^{9,10} Myopic changes and Lacquer cracks were not observed in the fundus examination of our case.

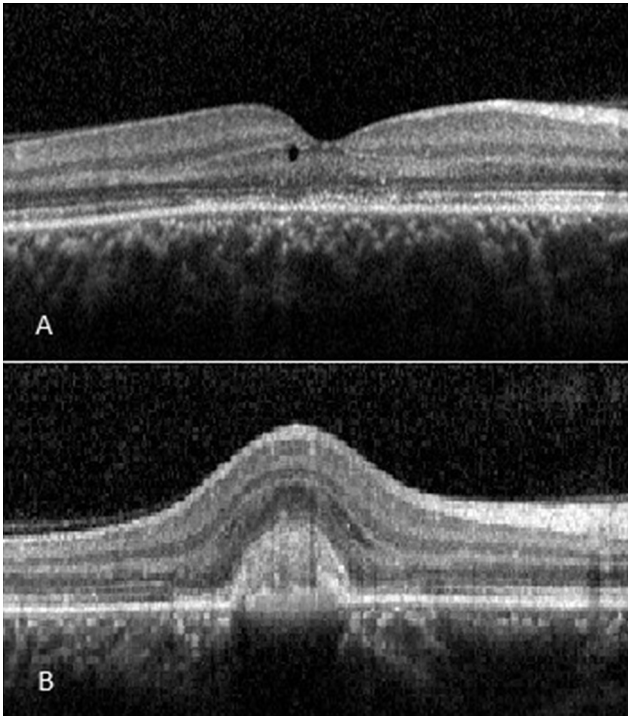


Fig. 3. Optical Coherence Tomography (OCT) after 3 intravitreal bevacizumab injection; (A): through macular center and (B): parafoveal area.

IOP elevation induced during LASIK surgery may result in posterior segment pathologies and may be a factor for CNV formation.¹¹ IOP elevation does not happen during PRK, and this may be the cause of lower reports of CNV formation following PRK compared with LASIK.

Acoustic shock waves produced by the excimer laser are another factor proposed to play a role in the CNV formation after both PRK and LASIK.⁴

CNV is not common in a 20-year-old patient without obvious myopic chorioretinal changes and Lacquer cracks.

Also, our patients' visual symptoms developed only 1 month after PRK surgery. Therefore, PRK may play a role in the development of CNV in our case. Since idiopathic and myopic CNV cannot be ruled out in our case, the cause-and-effect relationship between the surgical procedure and CNV formation is not established.

In conclusion, it seems that CNV may occur after PRK in myopic eyes. Patients should be informed of this potential sight-threatening complication. Also, refractive surgeons should consider CNV development in cases with visual compliant or metamorphopsia following PRK.

References

1. Thompson KP. Photorefractive keratectomy. *Ophthalmol Clin N Am.* 1992;5(4):745–751.
2. Ruiz-Moreno JM, Artola A, Ayala MJ, Claramonte P, Alió JL. Choroidal neovascularization in myopic eyes after photorefractive keratectomy. *J Cataract Refract Surg.* 2000;26(10):1492–1495.
3. Cohen SY, Laroche A, Leguen Y, et al. Etiology of choroidal neovascularization in young patients. *Ophthalmology.* 1996;103:1241–1244.
4. Neo HY, Neelam K, Yip CC, Quah HM, Au Eong KG. Choroidal neovascularization following laser in situ keratomileusis for high myopia: a case series. *Int Ophthalmol.* 2013;33(1):27–34.
5. Saeed M, Poon W, Goyal S, McHugh D, Lee N. Choroidal neovascularization after laser in situ keratomileusis in a patient with low myopia. *J Cataract Refract Surg.* 2004;30(12):2632–2635.
6. Loewenstein A, Lipshitz I, Varssano D, Lazar M. Macular hemorrhage after excimer laser photorefractive keratectomy. *J Cataract Refract Surg.* 1997;23(5):808–810.
7. Ruiz-Moreno JM, Alió JL. Incidence of retinal disease following refractive surgery in 9,239 eyes. *J Refract Surg.* 2003;19(5):534–547.
8. Hotchkiss ML, Fine SL. Pathologic myopia and choroidal neovascularization. *Am J Ophthalmol.* 1981;91:177–183.
9. Curtin BJ. The posterior staphyloma of pathologic myopia. *Trans Am Ophthalmol Soc.* 1977;75:67–86.
10. Curtin BJ. Myopia. In: Yannuzzi LA, Gitter KA, Schatz H, eds. *The Macula; a Comprehensive Text and Atlas.* Baltimore, MD: Williams & Wilkins; 1979:232–242.
11. Maturi RK, Kitchens JW, Spitzberg DH, Yu M. Choroidal neovascularization after LASIK. *J Refract Surg.* 2003;19(4):463–464.