

# Success Rate and Complications of Comminuted Intra-Articular Distal Radius Fracture Treatment via Closed Reduction and Use of a Mini-External Fixator

Mohammad Hossein Karimi Nasab,<sup>1</sup> Masoud Shayesteh Azar,<sup>1\*</sup> Samira Fazel Moghaddam,<sup>2</sup> and Mehrdad Taghipour<sup>3</sup>

<sup>1</sup>Department of Orthopedics, orthopedic research center, Mazandaran University of Medical Sciences, Sari, IR Iran

<sup>2</sup>Faculty of Medicine, Mazandaran University of Medical Sciences, Sari, IR Iran

<sup>3</sup>Nephrology and Urology Research Center, Baqiyatallah University of Medical Sciences, Tehran, IR Iran

\*Corresponding author: Masoud Shayesteh Azar, Department of Orthopedics, Mazandaran University of Medical Sciences, Sari, IR Iran. Tel: +98-9111515654, Fax: +98-113377169, E-mail: mshayestehazar@yahoo.com

Received 2014 March 15; Revised 2014 May 4; Accepted 2014 June 3.

## Abstract

**Background:** Intra-articular fracture of the distal radius is extremely common; however, the management of this fracture is controversial.

**Objectives:** With regard to the importance of intra-articular fracture of the distal radius and the best treatment method for the fracture, we sought to assess the success rate following the treatment of comminuted intra-articular fractures of the distal radius via closed reduction and use of a mini-external fixator.

**Patients and Methods:** This longitudinal retrospective study was undertaken at our department of orthopedics via assessment of radiographs and patient files of those referred from 2006 to 2013. Radiographic criteria included the degree of angulation and shortening of the radius. Data were analyzed using SPSS 18 software and were presented as mean  $\pm$  standard deviation (SD). The significance level was set at  $P \leq 0.05$ .

**Results:** Overall,  $\geq 2$  mm shortening of the radius was seen in 28% of the patients, 53% had 2-5 mm radial shortening and 19% of the patients had more than 5 mm shortening of the radius. Most of the participants had acceptable outcomes. The mean angulation was  $6.28 \pm 2.85$  degrees and the mean shortening was  $3.92 \pm 2.22$ . Thirty-nine percent of the patients had an angulation of less than 5 mm, 56% and 5% had an angulation of 5-10 mm and more than 10 mm, respectively.

**Conclusions:** The results of our study showed that the mini-external fixator is a good and effective treatment option for obtaining radial length, angulation and bony union in intra-articular fractures of the distal radius.

**Keywords:** Closed reduction, Comminuted, Distal Radius, Mini-External Fixator

## 1. Background

Distal radial fracture is the most common fracture of the forearm and comprises approximately 16% of all fractures treated by orthopedic surgeons (1). This fracture was clinically diagnosed in 1814 by Colles, who described this entity in a paper published in Edinburgh (2). The standard series of posterior-anterior (PA), lateral and oblique radiographic views are useful to visualize suspected fractures of the distal radius. In 1993, Fernandez proposed a mechanism-based classification system that addressed the potential for ligamentous injury and treatment recommendations (type I-V) (3, 4). Intra-articular distal radius fractures represent high-energy, complex, unstable injuries - the optimal treatment of which remains a topic of controversy. Many different treatment methods have been advocated, including external fixation, open reduction and internal fixation with K-wires, dorsal plating and palmar plating or both. The goal of

treatment of these fractures is a wrist that provides sufficient pain-free motion and stability to permit vocational and avocational activities for all age groups without the propensity for future degenerative changes in the young (5-8). There have been many recent advances both in surgical techniques and in hardware design (9). Several leading investigators have advocated the use of mini external fixators in the treatment of comminuted intra-articular fracture of the distal radius with different and somewhat contradictory success rates (10).

## 2. Objectives

Despite the importance and prevalence of distal radius fractures, there are insufficient studies and contradictory results, therefore we decided to assess the success rate of comminuted intra-articular fractures of distal radius

treated via closed reduction and mini-external fixator fixation and evaluate complications and outcomes.

### 3. Patients and Methods

This longitudinal retrospective study was conducted assessing radiographic results and charts of patients with comminuted intra-articular fracture of distal radius treated via closed reduction and a mini-external fixator from 2006 to 2013. The subjects were patients with comminuted intra-articular fractures of the distal radius treated via closed reduction and mini-external fixators. Exclusion criteria included extra-articular fractures or pathologic fractures due to causes other than trauma, tumors, diseases etc. We selected subjects based on the Poisson model 43 subjects were assessed. Schanz pins were placed in metacarpals second and third metacarpal bone Schanz pins were placed in the radius. External fixation was then done. Radiographic criteria were assessed and recorded by the same radiologist. These criteria included: degree of angulation (decreased size from the normal radius angle in degrees), shortening of the radius bone (decreased size from the normal radius length in millimeters) and dorsal/palmar tilt. Patients were followed for at least six months depending on their clinical conditions. The success rate of the treatment was determined based upon the length of the radius after treatment as: good (shortening  $\leq 2$  mm), acceptable (2 - 5 mm) and bad (shortening  $> 5$  mm). In addition, the success rate of treatment was determined in accordance with the degree of angulation as: good (angulation  $< 5$  degree), acceptable (5-10 degrees) and bad (angulation  $> 10$  degree).

#### 3.1. Statistical Analysis

The data was assessed via the SPSS version 18 software. Descriptive analysis of quantitative and qualitative data was performed and the results were presented as mean  $\pm$  standard deviation (SD) and frequency, respectively. Also proportional and binomial tests were used to compare radiographic outcomes of treatment. Logistic regression was used to control confounding variables. Significance level was set at  $P < 0.05$ .

### 4. Results

Out of 43 patients, 25 (58.1%) were males and 18 (41.9%) were females. The mean age of the patients was 44.02 years with a range of 14-80  $\pm$  15.94 years. The only underlying disease was DM, which was found in five (11.6%) patients. Based on the Fernandez classification of the distal radius fractures, 14 (32%) of the subjects had type II fracture, 15 (35%) had type III, 11 (26%) had type IV and three (7%) had type V fractures. It was observed that 12 (27.9%) of the patients had an open fracture and 31 (72.1%) of them had a closed fracture. Furthermore, 12 (28%) of the patients had shortening of the radius  $\geq 2$  mm, 23 (53%) had 2-5 mm radial shortening and eight (19%) of the patients had more than 5 mm shortening of the radius.

The minimum angulation was one degree and the maximum was eleven degrees; the mean was 6.28 degrees. As shown in Figure 1, 39% of patients had an angulation of less than 5 mm, 56% and 5% of the patients had an angulation of 5 to 10 mm and more than 10 mm, respectively. It could be said that the treatment was acceptable overall. The radial shortening in patients with type II fractures was  $3.24 \pm 2.31$  mm. The Patients with type III fractures had radial shortening with a mean of  $3.81 \pm 1.47$ . Those with type IV fractures had a mean of  $4.37 \pm 2.52$  mm and the others with type V fractures had shortening of  $4.50 \pm 2.56$  mm. The mean radial shortening in the patients was  $3.95 \pm 2.22$  mm (Table 1).

Patients with type II fracture had a mean radial angulation of  $4.56 \pm 1.87$  degrees while those with type III had a mean angulation of  $6.63 \pm 2.77$  degrees. Those with type IV fracture had a mean of  $7.32 \pm 2.86$  degrees and the subjects with fracture type V had a mean angulation of  $8.63 \pm 3.12$  degrees. The mean angulation of the radius for the entire group was  $6.28 \pm 2.85$  degrees (Table 2).

The mean angulation for patients with open fractures was  $7.08 \pm 2.17$  degrees and for those with closed fractures, this was  $5.93 \pm 2.63$  degrees. The mean radius shortening for patients with open and closed fractures was  $5.33 \pm 3.05$  mm and  $3.42 \pm 1.56$  mm, respectively. No statistically significant differences were observed in these results (Table 3).

Complications of treatment included malunion, pin tract infection, nonunion and Sudeck's atrophy, which were observed in six (14%), two (4.7%), one (2.3%) and two (4.7%) patients, respectively (Figure 1).

**Table 1.** Shortening of the Radius Based on Fracture Type

Fracture type	Number of Patients <sup>a</sup>	Values <sup>b</sup>
II	14 (32)	$3.24 \pm 2.31$
III	15 (35)	$3.81 \pm 1.47$
IV	11 (26)	$4.37 \pm 2.56$
V	3 (7)	$4.50 \pm 2.56$
<b>Total</b>	43	$3.95 \pm 2.22$

<sup>a</sup>Data are presented as mean  $\pm$  SD.

<sup>b</sup>Data are presented as No. (%).

**Table 2.** Angulation of the Radius in Degrees Based on Fracture Type

Fracture type	Number of Patients <sup>a</sup>	Values <sup>b</sup>
II	14 (32)	$4.56 \pm 1.87$
III	15 (35)	$6.63 \pm 2.77$
IV	11 (26)	$7.32 \pm 2.86$
V	3 (7)	$8.63 \pm 3.12$
<b>Total</b>	43	$6.28 \pm 2.85$

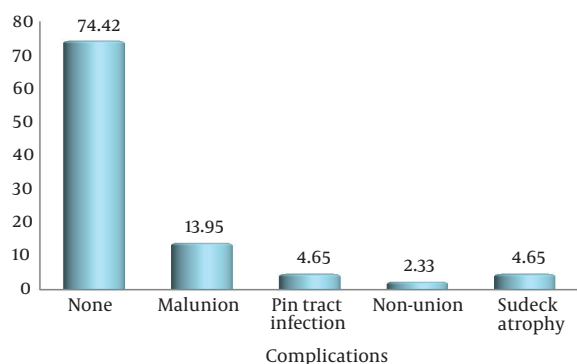
<sup>a</sup>Data are presented as mean  $\pm$  SD.

<sup>b</sup>Data are presented as No. (%).

There were no complications in 32 (74.4%) of the subjects. Furthermore, one patient (6.66%) with fracture type III had malunion, one (6.66%) had pin tract infection and one (6.66%) had Sudeck's atrophy. The rest had no complications. Four (36.36%) of the patients with type IV fracture had malunion, one (9.09%) had pin tract infection and one (9.09%) had Sudeck's atrophy. The others had no complications. The results indicated one (33.33%) out of three patients with type V fracture had malunion and one (33.33%) had nonunion (Table 4).

**Table 3.** Radiographic Criteria and Complications Based Upon Open or Closed Fractures

Open or Closed Fracture	Open Fracture	Closed Fracture	P Value
Radial angulation	7.08 ± 2.17	5.93 ± 2.63	0.95
Radial shortening	5.33 ± 3.05	3.42 ± 1.56	0.001
<b>Complications</b>			0.07
Malunion	2 (16.7%)	4 (12.9%)	
PT infection	0	2 (6.5%)	
Nonunion	1 (8.3%)	0	
Sudeck's atrophy	1 (8.3%)	2 (3.2%)	



**Figure 1.** Occurrence of Complications in the Patients

**Table 4.** Occurrence of Complications Based on Fracture Type in Patients

Complications	Fracture Type Based on Fernandez Classification a,b			
	Type II	Type III	Type IV	Type V
None	14 (100)	12 (80)	5 (45.45)	1 (33.33)
Malunion	0 (0)	1 (6.66)	4 (36.36)	1 (33.33)
Pin tract infection	0 (0)	1 (6.66)	1 (9.09)	0 (0)
Nonunion	0 (0)	0 (0)	0 (0)	1 (33.33)
Sudeck's atrophy	0 (0)	1 (6.66)	1 (9.09)	0 (0)
<b>Total</b>	14 (100)	15 (100)	11 (100)	3 (100)

<sup>a</sup>P Value = 0.76.

<sup>b</sup>Data are presented as No. (%).

These findings showed no significant via the chi-square test (P-value of 0.76). To verify the association between open or closed fractures and the occurrence of complications, we analyzed these variables via the chi-square test. However, statistically considerable differences were not observed (P = 0.07).

### 5. Discussion

Intra-articular distal radius fractures represent high-energy, complex and unstable injuries; the optimal treatment of which remains a topic of controversy. Many different treatment methods have been suggested including, external fixation, open reduction and internal fixation with K-wires, dorsal plating and palmar plating (6). There have been many recent advances both in surgical techniques and in instrument design. Several leading investigators have supported the use of mini-external fixators in the treatment of comminuted intra-articular fractures of the distal radius (11). Most of the fractures in young cases were caused by road traffic accidents (12). Distal radius fracture is one of the most common injuries, and as time has gone by, more and more classifications have emerged with the emergence of more novel and effective treatment options that include a cast, external fixator, percutaneous pinning, or K-wire fixation and bone grafting. It can be said that, all these modalities aim to obtain optimum radial length and maintenance of radial inclination confirmed by taking pre and post-operative radiographs (13-15). Like many other studies, in our study most of the participants were males; the male/female ratio was 1.38:1. In this study, mean radial shortening was 3.95 ± 2.22 mm, which was similar to that reported by Arshad et al. (16) (3.35 ± 1.18). The mean radial angle in our study was 6.28 ± 2.85 mm while Arshad et al. (16) reported a radial angle of 12.52 ± 2.59 mm. Therefore, it seems that deviation from a normal angle in our study was less. In the study of Jenkins et al. (17), radial angulation after treatment in patients with Colles fracture in the forearm plaster and external fixator group were 6.5 ± 5.2 and 0.7 ± 3.9 degrees, respectively. The findings indicated that radial shortening was 3.7 ± 2.8 mm in patients with forearm plaster and 0.3 ± 1.8 mm for those with external fixators. Our results were higher than what was achieved by Jenkins et al. (17) via external fixators. This also applied to results of radial angulation. This difference may arise from fracture differences. Colles fracture is not an intra-articular fracture and is milder than fractures treated in this study. Also pin tract infection was observed in several patients similar to our study. Sudeck's atrophy was not seen. Melone et al. (18) studied the application of external fixator use in the treatment of intra-articular fracture of the distal radius and reported 3.2 mm radial shortening, which is similar to our findings. Type IV (34.78%) fracture was the most frequent type, in the study of Jakim et al. (19) Regarding severity, however, in the current study, the most common fracture was type III (35%). In the study of Jakim et al. (19), 36.65% of patients had type I and II frac-

ture; we did not have type I fracture in our study. Clearly, as severity increases, achieving better treatment becomes more difficult. Jakim et al. (19) reported that radial length and radial angle were fully restored in most patients in their study. Krishnan (20) in his study compared a non-bridging external fixator with a bridging external fixator system for the treatment of intra-articular fractures of the distal radius. Radial angulation was 3.5 and 0 degrees for the non-bridging external fixator and bridging external fixator, respectively. These results were better in comparison to the results of our study. Radial shortening was 2.5 mm for the non-bridging external fixator and 3 mm for the bridging external fixator. This difference could be due to the severity of fractures and the instrument that they utilized. The radial lengths were also better in the mentioned study. The difference in the results of Krishnan (20) and the present study may be due to the inclusion of comminuted fractures in the current study. The presence of patients with complex comminuted fractures in this study is also reflected in the worse results of radial angle and radial length. In that study, almost one-third of patients developed pin tract infections despite the use of prophylactic antibiotics. The rate of infection was lower in our study. This reflects our high threshold for treating pin site problems and may be due to higher than usual consumption of antibiotics in our centers. Comminuted intra-articular distal radius fractures represent a difficult problem for orthopedic surgeons (21). We feel the treatment utilized in this study was successful. Also, in accordance with the mean angulation of 6.28 degrees and mean radial shortening of 3.95 mm and less complications in the current study, treatment via closed reduction and mini external fixation was acceptable. However, it is associated with some complications that require careful pin site management and proper patient selection.

## Footnotes

**Authors' Contribution:** Mohammad Hossein Karimi Nasab: designing and planning of the study. Masoud Shayesteh Azar: screening of the patients. Samira Fazel Moghaddam: data collection. Mehrdad Taghipour: writing and editing of the manuscript.

**Funding/Support:** This study was supported by Mazandaran University of Medical Sciences.

## References

1. Abramo A, Kopylov P, Geijer M, Tagil M. Open reduction and internal fixation compared to closed reduction and external fixation in distal radial fractures: a randomized study of 50 patients. *Acta Orthop*. 2009;**80**(4):478-85. doi: 10.3109/17453670903171875. [PubMed: 19857180]
2. Colles A. On the fracture of the carpal extremity of the radius. *Edinb Med Surg J*. 1814;**10**:181. *Clin Orthop Relat Res*. 2006;**445**:5-7. doi: 10.1097/01.BLO.000020589575491.a8. [PubMed: 16601406]
3. Fernandez DL. Fractures of the distal radius: operative treatment. *Instr Course Lect*. 1993;**42**:73-88. [PubMed: 8463706]
4. Adams BD. Effects of radial deformity on distal radioulnar joint mechanics. *J Hand Surg*. 1993;**18**(3):492-8. doi: 10.1016/0363-5023(93)90098-n.
5. Al-Rashid M, Theivendran K, Craigen MA. Delayed ruptures of the extensor tendon secondary to the use of volar locking compression plates for distal radial fractures. *J Bone Joint Surg Br*. 2006;**88**(12):1610-2. doi: 10.1302/0301-620X.88B12.17696. [PubMed: 17159173]
6. Arora R, Lutz M, Hennerbichler A, Krappinger D, Espen D, Gabl M. Complications following internal fixation of unstable distal radius fracture with a palmar locking-plate. *J Orthop Trauma*. 2007;**21**(5):316-22. doi: 10.1097/BOT.0b013e318059b993. [PubMed: 17485996]
7. Apergis E, Darmanis S, Theodoratos G, Maris J. Beware of the ulno-palmar distal radial fragment. *J Hand Surg Br*. 2002;**27**(2):139-45. doi: 10.1054/jhsb.2001.0712. [PubMed: 12027487]
8. Arora R, Lutz M, Fritz D, Zimmermann R, Oberladstatter J, Gabl M. Palmar locking plate for treatment of unstable dorsal dislocated distal radius fractures. *Arch Orthop Trauma Surg*. 2005;**125**(6):399-404. doi: 10.1007/s00402-005-0820-8. [PubMed: 15891921]
9. Arslan H, Subasi M, Kesemenli C, Kapukaya A, Necmioglu S. Distraction osteotomy for malunion of the distal end of the radius with radial shortening. *Acta Orthop Belg*. 2003;**69**(1):23-8. [PubMed: 12666287]
10. Atroshi I, Brogren E, Larsson GU, Kloov J, Hofer M, Berggren AM. Wrist-bridging versus non-bridging external fixation for displaced distal radius fractures: a randomized assessor-blind clinical trial of 38 patients followed for 1 year. *Acta Orthop*. 2006;**77**(3):445-53. doi: 10.1080/17453670610046389. [PubMed: 16819684]
11. Augé WK, Velázquez PA. The application of indirect reduction techniques in the distal radius. *Arthroscopy J Arthroscop Relat Surg*. 2000;**16**(8):830-5. doi: 10.1053/jars.2000.17717.
12. Azzopardi T, Ehrendorfer S, Coulton T, Abela M. Unstable extra-articular fractures of the distal radius: a prospective, randomised study of immobilisation in a cast versus supplementary percutaneous pinning. *J Bone Joint Surg Br*. 2005;**87**(6):837-40. doi: 10.1302/0301-620X.87B6.15608. [PubMed: 15911669]
13. Bednar DA, Al-Harran H. Nonbridging external fixation for fractures of the distal radius. *Can J Surg*. 2004;**47**(6):426-30. [PubMed: 15646441]
14. Benson EC, DeCarvalho A, Mikola EA, Veitch JM, Moneim MS. Two potential causes of EPL rupture after distal radius volar plate fixation. *Clin Orthop Relat Res*. 2006;**451**:218-22. doi: 10.1097/01.blo.0000223998.02765.od. [PubMed: 16770281]
15. Mansouri M, Siyavoshi B. Comparison of close reduction and percutaneous pin fixation as treatments for distal metaphyseal radius fractures. *Yafteh*. 2006;**8**(3):23-30.
16. Arshad AJ, Mahmood K. Radial length and radial angle in closed reduction plaster Cast immobilization versus external fixation in comminuted Intra articular fracture of distal radius. *J Pak Orthop Assoc*. 2013;**25**(1):14-7.
17. Jenkins NH, Jones DG, Johnson SR, Mintowt-Czyz WJ. External fixation of Colles' fractures. An anatomical study. *J Bone Joint Surg Br*. 1987;**69**(2):207-11. [PubMed: 3818750]
18. Melone CJ. Distal radius fractures: patterns of articular fragmentation. *Orthop Clin North Am*. 1993;**24**(2):239-53. [PubMed: 8479722]
19. Jakim I, Pieterse HS, Sweet MB. External fixation for intra-articular fractures of the distal radius. *J Bone Joint Surg Br*. 1991;**73**(2):302-6. [PubMed: 2005161]
20. Krishnan J. Intra-articular fractures of the distal radius: a prospective randomised controlled trial comparing static bridging and dynamic non-bridging external fixation. *J Hand Surg J Br Soc Surg Hand*. 2003;**28**(5):417-21. doi: 10.1016/S0266-7681(03)00083-4.
21. Bong MR, Egol KA, Leibman M, Koval KJ. A comparison of immediate postreduction splinting constructs for controlling initial displacement of fractures of the distal radius: a prospective randomized study of long-arm versus short-arm splinting. *J Hand Surg Am*. 2006;**31**(5):766-70. doi: 10.1016/j.jhsa.2006.01.016. [PubMed: 16713840]