

Evaluation of Hydroalcoholic Extract of Cinnamon Effect on Testicular Tissue and Fertility of Busulfan-Induced Oligo-Spermic Model Rats

P. Soleimani (BSc)¹, R. Chegini (MSc)¹, M. Sadeghi (PhD)², F. Yonesi (MD)¹, F. Zafari (PhD)^{*3}

1.Student Research Committee, Faculty of Medicine, Qazvin University of Medical Sciences, Qazvin, I.R.Iran

2.Genetics Research Center, Baqiyatallah University of Medical Sciences, Tehran, I.R.Iran

3.Cellular and Molecular Research Center, Qazvin University of Medical Sciences, Qazvin, I.R.Iran

J Babol Univ Med Sci; 21; 2019; PP: 196-200

Received: Oct 16th 2018, Revised: Mar 4th 2019, Accepted: Apr 16th 2019.

ABSTRACT

BACKGROUND AND OBJECTIVE: Busulfan is one of the cancer treatment drugs that cause infertility of the patient. In traditional medicine, one of the important properties of cinnamon is enhancement of fertility. The aim of this study was to investigate the effect of cinnamon on the physiological structure of testes and fertility rate of busulfan-treated rats.

METHODS: In this experimental study, 24 adult male rats were divided into 3 groups of 8 subjects, Sham: healthy rats without intervention. Control group: Busulfan-sterilized rats (15 mg/kg) intraperitoneal injection, Cinnamon group: Busulfan-treated rats + cinnamon extract (200 mg/kg) for fourteen days. The testicles length, width and weight parameters as well as the formation of germinal cells were analyzed by H & E staining and optical microscopy.

FINDINGS: The number of spermatogonia cells, primary spermatocytes and spermatid in the cinnamon group was 72.25 ± 12.63 , 61.71 ± 11.47 , and 79.1 ± 10.02 , and in the control group was 51.83 ± 23.37 , 31.67 ± 5.27 and 38.67 ± 15.7 respectively, and the increase in cinnamon group was significant ($p < 0.005$). The testicles length, width and weight parameters in the cinnamon group were increased compared to the control group (busulfan). The thickness of germinal epithelium in the cinnamon and control group was 53.46 ± 16.44 and 30.4 ± 10.21 respectively, which was significantly higher in the cinnamon group ($p < 0.001$).

CONCLUSION: According to the findings of this study, cinnamon extract has positive therapeutic and protective effects on testicular tissue and increases sperm production in busulfan-treated rats.

Key words: *Busulfan, Cinnamon, Spermatozoa, Testis, Fertility.*

Please cite this article as follows:

Soleimani P, Chegini R, Sadeghi M, Yonesi F, Zafari F. Evaluation of Hydroalcoholic Extract of Cinnamon Effect on Testicular Tissue and Fertility of Busulfan-Induced Oligo-Spermic Model Rats. J Babol Univ Med Sci. 2019;21:196-200.

*Corresponding Author: F. Zafari (PhD)

Address: Cellular and Molecular Research Center, Qazvin University of Medical Sciences, Qazvin, I.R.Iran

Tel: +98 28 33336001-5

Email: f.zafari@qums.ac.ir

Introduction

Infertility is one of the most common and growing problems in industrial societies that has many psychological and social consequences for the individual. Disruption of sperm production and sperm function and damage to spermatogenesis are among the most common causes of male infertility (1, 2). One of the common side effects of anticancer drugs is disruption of spermatogenesis which in many cases can lead to infertility. Busulfan (BSF, 1 and 4-butane diol D-methane sulfonate) is one of the chemotherapy drugs used to treat melanoma before bone marrow transplantation (3).

It has been observed that daily administration of 15 mg/kg busulfan to mice destroys the tissue of the epididymis of testis and severe azoospermia (4), and administration of busulfan to male patients with malignant cancer can lead to permanent or temporary infertility (5). Spermatogenesis disorder appears to be due to its alkylating properties after treatment with busulfan, which is why busulfan exerts its greatest effect on spermatogonial cells (6, 7). The highest cytotoxic effect of busulfan has been reported in cells within the G1 phase of the cell cycle, and other cells in the G2 phase will be killed by busulfan alkylation (8). Cinnamon is one of the indigenous aromatic herbs of India that has been recommended in traditional medicine for the enhancement of sexual potency. In terms of chemical constituents, the most important cinnamon compounds are cinnamon aldehyde, terpenes, cinnamyl alcohol, flandrene and safrol, most of which have antioxidant and anti-inflammatory properties (9,10). Evidence from in vitro studies confirms the fact that cinnamon extract has been effective in improving the performance and overall strengthening of the reproductive system in rats (9,11).

According to research, it is predicted that the use of this extract alone or in combination can be effective in reducing the damage to testosterone producing cells and sex cells (12,13). Previous studies have shown that cinnamon extract is effective in wound healing in diabetic mice. It has also been shown to be effective in the treatment of nausea and diarrhea due to the presence of antioxidant compounds in this plant (9,10,14). Although the effect of busulfan on testicular tissue depletion and reduced sperm production has been proven, few studies have investigated the ways to eliminate or reduce the sterility effects of busulfan in animals. Given the importance of infertility in cancer patients treated with busulfan and the presence of

numerous antioxidant and phenolic compounds in cinnamon and the positive effects of cinnamon on reproductive system enhancement, this study aimed to investigate the effect of cinnamon hydroalcoholic extract on testes tissue and the rate of fertility in sterilized rats by busulfan.

Methods

Animal Preparation and Sterility Modeling: This experimental study was conducted with the code of ethics IR.QUMS.REC.1394.831 at Qazvin University of Medical Sciences. The study was performed on 24 adult male rats weighing 180-200 g prepared from Razi Institute of Karaj. The rats were divided into three groups of healthy (Sham), busulfan treated (control) and busulfan treated and cinnamon (cinnamon) groups. Sterility pattern was induced in rats of control and cinnamon groups by intraperitoneal injection of busulfan at a dose of 15 mg/kg daily (15).

Cinnamon Extract: Extracts were performed by pharmacologists at the Iranian Institute of Pharmaceutical Sciences according to the following steps: 10 g of fresh cinnamon peel powder was added to 1L of ethanol and extracted for 2 h by ultrasonic extraction device (15 min extraction, 15 minutes' rest, 2 hours total). After 2 hours of initial ultrasound, the extract was transferred to a balloon with filter paper. The balloons were then incubated in the dark at room temperature (25 °C) for 24 h. Subsequently, the extracts and fractions were filtered through a rotary filter (vacuum distillation) concentrated at below 50 °C and finally the concentrated extracts and fractions were stored at -18 °C until use.

Grouping and Experiments: Animals were divided into three equal groups: Sham group: healthy animals without any intervention, control group: animals treated with busulfan at two doses of 15 mg / kg for 14 days, Cinnamon group: Animals treated with busulfan received intraperitoneal administration of cinnamon extract at a dose of 200 mg / kg for 14 days. Four weeks after treatment (due to 4 weeks' spermatogenesis in rats), animals were sampled.

Hematoxylin staining H&E: Hematoxylin staining was used to observe and evaluate the repair status of germinal epithelium tubes and to observe the types of germ cells forming; obtained slides were examined by light microscopy (yw2309, Australian made) and Image-J software.

Statistical analysis: Statistical analysis was performed using SPSS version 11 and ANOVA and Tukey post-hoc tests were used to evaluate the significant differences between groups and $p \leq 0.05$ was considered significant.

Results

Comparison of testicular weight and length and width changes in the studied groups: At the end of the fourth week, testicular weight in the cinnamon and control groups was 1.42 ± 0.33 and 1.25 ± 0.89 g, respectively, that was not significant. The testicular length in the cinnamon and control groups was 2.35 ± 0.27 cm and 2.17 ± 0.18 cm respectively. Also, the testicular width at the end of the 14th day was 1.4 ± 0.1 and 1.36 ± 0.19 in the cinnamon and control groups, respectively and although the length and width of the cinnamon group increased, these changes were not significant (Table 1).

Table1. Comparison of mean weight (g) and testicular length and width (cm) in studied groups on day 14

| Group | Sham | Control | Cinnamon |
|----------|-------------------|-------------------|-------------------|
| Variable | Mean±SD | Mean±SD | Mean±SD |
| length | 2.5 ± 0.25 a | 2.17 ± 0.18 a | 2.35 ± 0.27 a |
| width | 1.48 ± 0.38 a | 1.36 ± 0.19 a | 1.49 ± 0.1 a |
| weight | 1.47 ± 0.16 a | 1.25 ± 0.89 a | 1.43 ± 0.33 a |

The dissimilar letters indicate a significant difference; the data being compared in a row. **Quantitative evaluation of germinal epithelium tubes:** Measurement of germinal epithelium thickness at the end of the fourth week showed that the thickness of germinal epithelium in cinnamon and control group (busulfan) was 53.26 ± 16.44 and 30.4 ± 21.1 , respectively and there was a significant increase in the cinnamon group. The diameter of tubes in the cinnamon and control groups (busulfan) was 178.48 ± 17.51 and 126.24 ± 24.81 μ m respectively, which was significant in the cinnamon group ($p < 0.001$) (Table 2) (Fig 1).

The dissimilar letters indicate a significant difference; the data being compared in a row. The number of spermatogonial cells of primary spermatocytes and spermatids: In the study of spermatogonia cells in studied groups, the average number of spermatogonia in the cinnamon and control groups was 72.25 ± 12.63 and 51.83 ± 23.37 , respectively, which increased spermatogonia was observed in the cinnamon group and its decrease in the control group

(busulfan) in comparison to the sham group, the number of primary spermatocytes in cinnamon and control (busulfan) were 61.71 ± 11.47 and 31.67 ± 5.27 , respectively that increment in cinnamon group was significant in comparison to the control group ($p < 0.001$) (Table 3). The number of spermatids in the cinnamon and control groups was 79.10 ± 10.02 and 38.67 ± 15.7 , respectively, which was significantly higher in the cinnamon group ($p < 0.001$) (Fig. 2)

Table2. Comparison of the mean thickness and diameter of the epithelium and the number of germ cells formed in the studied groups on day 14

| Group | Sham | Control | Cinnamon |
|------------|----------------------|----------------------|----------------------|
| Epithelium | Mean±SD | Mean±SD | Mean±SD |
| thickness | 52.6 ± 7.08 a | 30.4 ± 10.21 b | 53.26 ± 16.44 a |
| diameter | 175.75 ± 41.03 a | 126.24 ± 24.81 b | 178.48 ± 17.51 a |

The dissimilar letters indicate a significant difference; the data being compared in a row

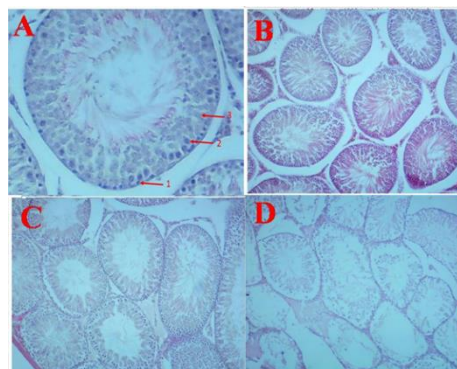


Figure1. Image of Seminal tubes sections in the studied groups by H&E staining at 100X magnification

A: Cinnamon group (A1: spermatogonia, A2: primary spermatocytes, A3: spermatids). B: Sham group C: Cinnamon group D: Control group. Tissue repair and membrane repair are also evident in the cinnamon receiving group

Table3. Comparison of mean number of formed germ cells in studied groups on day 14

| Group | Sham | Control | Cinnamon |
|-----------------------|---------------------|---------------------|---------------------|
| Variable | mean±SD | mean±SD | mean±SD |
| Spermatogonia | 69.17 ± 12.28 a | 51.83 ± 23.37 b | 72.25 ± 12.63 a |
| Primary spermatocytes | 76.5 ± 16.67 a | 31.67 ± 5.27 b | 71.17 ± 11.47 a |
| Spermatids | 85 ± 13.9 a | 38.67 ± 15.7 b | 79 ± 10.02 a |

The dissimilar letters indicate a significant difference; the data being compared in a row.

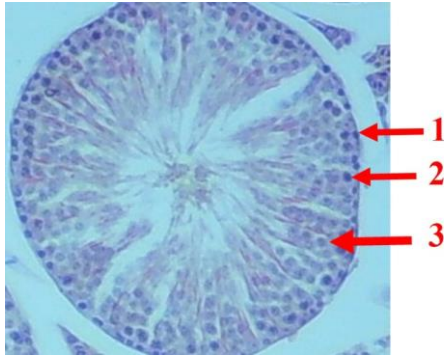


Figure 2. Clear image of H&E staining at 100x magnification of germ cell formation in the cinnamon-treated group (1: spermatogonia, 2: primary spermatocytes, 3: spermatids).

Discussion

In this study, spermatogonia production was significantly increased in sterilized rats by busulfan in cinnamon treated group (at dose of 200 mg/kg) compared to control group. In line with studies, Khaki et al reported that cinnamon significantly increased sperm motility and viability and improved testicular parameters and increased overall testosterone levels in diabetic rats (16). In another study, AL-Khamas et al reported that cinnamon extract increased testosterone levels in diabetic rats, thereby enhancing sperm motility and spermatogenesis (17). In the study of testicular tissue repair in the present study, administration of cinnamon extract (200 mg / kg) for 14 days significantly increased the thickness and diameter of the damaged epithelium tubes due to busulfan treatment, Pirami et al. reported that cinnamon extract (75 mg/kg) has significant effects on tissue repair of testicular epithelium in rats exposed to stress and increases

reproductive potential of these rats due to the effects of cinnamon-boosting testosterone (18), which these findings confirms the findings of the present study. Free radicals (ROS) with sperm membrane peroxidation and sperm DNA damage are one of the main causes of reduced sperm production and sperm inefficiency, cinnamon consumption increases levels of SOD and glutathione peroxidase (GPX) enzymes. These enzymes neutralize free radicals and thereby increase sperm count and function (19,20). Yuce et al reported that cinnamon oil increased testicular and epididymal weight in rats, and a decrease in lipid peroxidation (LPO) and sperm apoptosis index were attributed to this effect of cinnamon (13), in the present study, cinnamon supplementation increased testicular weight and diameter compared to the control group, which confirms the findings of previous studies (13,18). The findings of this study suggest that intraperitoneal injections of cinnamon extract with busulfan can greatly reduce the sterile effects of busulfan and help repair testicular tissue and increase the production of germ cells, and these results may be useful in the future to prevent sterility in patients undergoing treatment with Busulfan. According to the latest study, the findings of the present study are the first to investigate the effect of cinnamon on testicular activity and structure in busulfan-treated rats.

Acknowledgment

Here by we would thank the Cellular and Molecular Research Center of Qazvin University of Medical Sciences for providing the facilities needed for this study.

References

- 1.Nojumi M, Ashrafi M, Kouhpayehzadeh Esfahani J. Study of couples infertility in the west of Tehran, in the year of 2000. *J Iran Univ Med Sci.* 2002; 8 (27):633-41.
- 2.Shalaby MA, Mouneir SM. Effect of zingiber officinale roots and cinnamon zeylanicum bark on fertility of male diabetic rats. *Glob Veter.* 2010; 5(6):341-7.
- 3.Qu N, Kuramasu M, Hirayanagi Y, Nagahori K, Hayashi Sh, Ogawa Y, et al. Gosha-Jinki-Gan Recovers Spermatogenesis in Mice with Busulfan-Induced Aspermatogenesis. *Int. J. Mol. Sci.* 2018, 19, 2606.
- 4.Ploemacher RE, Johnson KW, Rombouts EJ, Etienne K, Westerhof GR, Baumgart J, et al. Addition of treosulfan to a nonmyeloablative conditioning regimen results in enhanced chimerism and immunologic tolerance in an experimental allogeneic bone marrow transplant model. *Biol Blood Marrow Transplant.* 2004, 10(4), 236-45.
- 5.Bucci LR, Meistrich ML. Effects of busulfan on murine spermatogenesis: cytotoxicity, sterility, sperm abnormalities, and dominant lethal mutations. *Mutat Res.* 1987; 176(2):259-68.
- 6.Schrader M, Müller M, Straub B, Miller K. The impact of chemotherapy on male fertility: a survey of the biologic basis and clinical aspects. *Reprod Toxicol.* 2001; 15(6):611-7.
- 7.Anjamrooz SH, Movahedin M, Mowla SJ, Pour Bairanvand S. Assessment of morphological and functional changes in the mouse testis and epididymal sperms following busulfan treatment. *Irani Biomed J.* 2007; 11(1):15-22.
- 8.Payehdar A, Hosseini E, Mehrabani D, Forouzanfar M. Busulfan treatment effects on testicular tissue and serum levels of anti-mullerian hormone and testosterone in adult mice. *Indones Biomed J.* 2017; 9(2):106-12.
- 9.Kamath JV, Rana AC, Chowdhury AR. Pro-healing effect of cinnamomum zeylanicum bark. *Phytother Res.* 2003; 17(8):970-2.
- 10.Skidmore-Roth, L. *Mosby's Handbook of Herbs and Natural Supplements.* 2nd Ed. St. Louis: Mosby; 2004.
- 11.Ruberto G, Baratta MT, Deans SG, Dorman HD. Antioxidant and antimicrobial activity of *Foeniculum vulgare* and *Crithmum maritimum* essential oils. *Planta Med.* 2000; 66(8):687-93.
- 12.Hafez DA. Effect of extracts of ginger roots and cinnamon bark on fertility of male diabetic rats. *J Am Sci.* 2009; 6:940-7
- 13.Yüce A, Türk G, Çeribaşı S, Güvenç M, Çiftçi M, Sönmez M, et al. Effectiveness of cinnamon (*Cinnamomum zeylanicum*) bark oil in the prevention of carbon tetrachloride-induced damages on the male reproductive system. *Andrologia.* 2014; 46(3):263-72.
- 14.Nir Y, Potasman I, Stermer E, Tabak M, Neeman I. Controlled trial of the effect of cinnamon extract on *Helicobacter pylori*. *Helicobacter.* 2000; 5(2): 94-7.
- 15.Azizollahi S, Aflatoonian R, Sedigi-Gilani MA, Asghari Jafarabadi M, Behnam B, Azizollahi G, et al. Recruiting Testicular Torsion Introduces an Azoospermic Mouse Model for Spermatogonial Stem Cell Transplantation. *Urol J.* 2014; 11(3):1648-55.
- 16.Khaki A. Effect of *Cinnamomum zeylanicum* on Spermatogenesis. *Iran Red Crescent Med J.* 2015; 17(2): e18668.
- 17.AL-Khamas A. Effect of cinnamon zeylanicum bark water extract on male diabetic albino rats fertility. *Basrah J Vet Res.* 2018; 17(1):123-35.
- 18.Pirami H, Khavanin A, Mazaheri Z, Nadri F. The Protective Effect of Cinnamon Hydroalcoholic Extract on Testicular Tissue changes and Fertility Capacity in Male Rats Exposed to Noise Stress. *J Birjand Univ Med Sci.* 2018; 25(1):21-30. [In Persian]
- 19.Khaki A, Fathiazad F, Nouri M, Khaki A, Maleki NA, Khamnei HJ, et al. Beneficial effects of quercetin on sperm parameters in streptozotocin-induced diabetic male rats. *Phytother Res.* 2010;24(9):1285-91.
- 20.Jedlinska-Krakowska M, Bomba G, Jakubowski K, Rotkiewicz T, Jana B, Penkowski A. Impact of oxidative stress and supplementation with vitamins E and C on testes morphology in rats. *J Reprod Dev.* 2006;52(2):203-9.