

Experience With Surgical Management of Cholesteatomas

Mohammad Ajalloueyan, MD

Objective: To evaluate long-term results after at least 10 years of follow-up for a common method of ear surgery for managing cholesteatomas.

Methods: This retrospective study was performed by assessing the medical records of adult patients who underwent canal-wall-down mastoidectomy for management of cholesteatomas.

Results: From January 1, 1989, through December 31, 1995, 148 patients underwent surgery for cholesteatoma. Of these, 72 (48%) were treated by using the canal-wall-down method. During follow-up (10-16 years), 5 (7%) patients underwent at least 1 revision operation. Ten

years after primary surgery, 69 (96%) of the ears were dry and 55 (76%) had intact tympanic membranes with fair hearing in 30 (42%). One patient who was deaf was seen in this group of 72 patients. The recurrence rate was 7%, independent of the size of the cholesteatoma, mastoid status, or labyrinth or footplate erosion. The major predisposing factor for recurrence was retraction, especially in the posterior superior quadrant.

Conclusion: Our results showed that the surgical technique could be improved by using endoscopes to lower the recurrence rate and improve hearing results.

Arch Otolaryngol Head Neck Surg. 2006;132:931-933

CHRONIC OTITIS MEDIA IS A disease that is known worldwide and that is more common in developing countries. One of the major causes of chronic otitis media is acquired cholesteatoma or dermoid cyst. Cholesteatoma is a benign disease histologically; however, its behavior may be aggressive locally, and its invasive properties are associated with significant morbidity and occasionally mortality.¹ Cholesteatoma is suspected via direct otoscopy in the office, during operation, at conventional radiography, or upon evaluating the computed tomogram. Cholesteatoma may lead to subsequent bone destruction and other complications such as meningitis, brain abscess, labyrinthitis, and facial nerve paralysis.² The recurrence rates reported after surgery have been between 7.6% and 57.0% and are related to the length of follow-up.³ The only way to eradicate this cyst is via surgery, the aims of which are to achieve a dry self-cleansing ear and completely eradicate the disease. Literature reviews are replete with surgical treatment techniques, although much controversy exists concerning the optimal technique for managing cholesteatomas.⁴

The results of a sufficiently long-term follow-up play a major role in comparison and judgment among the numerous techniques, although there are few prolonged follow-up studies in the current literature.⁵⁻⁹ The objective of this study was to evaluate follow-up results of the canal-wall-down (CWD) mastoidectomy technique for eradicating cholesteatoma, assessing ear dryness, and improving hearing and the recurrence rate.¹⁰

METHODS

PATIENTS

As a primary operation, 148 patients with cholesteatoma and chronic otitis media underwent ear surgery between January 1, 1989, and December 31, 1995. All patients were candidates for 1-stage surgery. The canal-wall-up (CWU) technique was used for small confined cholesteatomas not beyond the aditus ad antrum, and the CWD technique was used for large or hidden cysts. Of these patients, 72 underwent CWD mastoidectomy with at least 10 years of follow-up and were enrolled in the study. The final evaluation was performed by an independent otologist. We excluded patients younger than 14 years because of current differences of opinions of surgeons con-

Author Affiliation: Department of Otolaryngology and Head and Neck Surgery, Baqiyatallah University of Medical Sciences, Tehran, Iran.

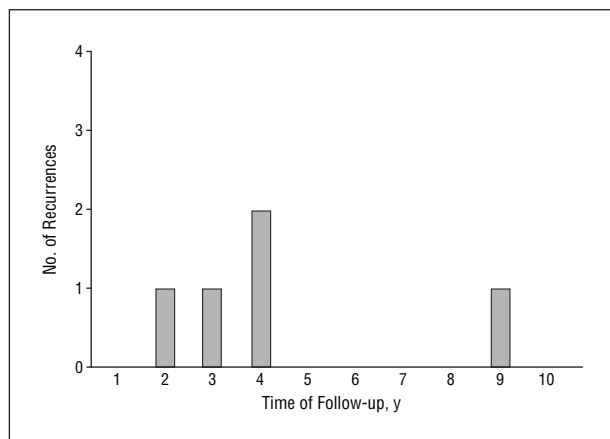


Figure. Number of cholesteatoma recurrences after 10 years of follow-up.

cerning ear surgery protocols for pediatric patients.¹¹ As a rule, all patients with supratubal, sinus tympani, perifacial nerve, footplate, and labyrinthine cholesteatomas underwent CWD mastoidectomy and tympanoplasty. Patients who had cholesteatomas less than 5 mm in diameter or confined to the middle ear or attic underwent a CWU procedure. Tympanoplasty and ossiculoplasty were performed with autologous fascia, cartilage, or cortical bone. In these ears, we used Silastic sheeting to prevent adhesion. Temporal bone axial computed tomographic scans were obtained and evaluated as normal, sclerotic, cloudy, or suggestive of possible cholesteatomas. Furthermore, air and bone conduction thresholds were determined by using a clinical audiometer calibrated according to the method of Richter and Fedtke.¹² Hearing levels were defined as the mean air conduction thresholds at 0.5, 1, 2, and 4 kHz.

The patients were followed up for at least 10 years (range, 10-16 years; mean, 12.3 years); patients visited monthly during the first year, every 4 months during the second year, and then annually. Cholesteatoma recurrence was caused by residual remains, disease recurrence, and retraction pockets containing keratin. In this study of patients who were operated on for CWD mastoidectomy, only the first operated-on ear is included.

SURGICAL TECHNIQUE

The techniques for CWD and CWU mastoidectomy and tympanoplasty were published previously.⁴ For the CWD technique, the surgeon removes the remnants of the posterior canal wall, and for the CWU technique the wall is saved or reconstructed. For the CWD technique, we remove the tip of the mastoid process and examine the hypotympanum, supratubal area, and sinus tympani. After profuse irrigation with lactated Ringer solution or isotonic sodium chloride solution, the widened mastoid bowl is obliterated by using 4 periosteal flaps based superiorly, inferiorly, anteriorly, and posteriorly. The routine procedure was exploration of the tegmen, sinus, and vertical facial nerve with close intraoperative nerve monitoring. Continuous suction irrigation was used to remove bone debris and prevent thermal damage to the cochlea, vestibule, and facial nerve. When the bone tip was removed, the cavity was beveled shallow and smaller, and bone chips were not necessary.¹³ Myringoplasty was performed by using autologous temporalis muscle fascia.

STATISTICAL ANALYSIS

The data evaluation of categorical items was presented as mean \pm standard deviation. For univariate analysis, the χ^2 test was

used, and $P < .05$ was considered significant. Variables with significant difference at univariate analysis were analyzed by using multivariate logistic regression analysis for determining independent variables.

RESULTS

From among 72 patients (age range, 16-72 years; mean age, 34 years) who underwent CWD mastoidectomy for cholesteatoma, the findings were as follows: the male-female ratio was 43:29, 50 (69%) had otorrhea, 54 (75%) had hearing loss above 50 dB, and 1 (1%) had facial paralysis. The prevalence of cholesteatoma was significantly higher in men ($P < .05$). At the time of surgery, 22 (31%) patients had dry ears. All patients had perforated tympanic membranes or attic retraction pockets. Tympanic membrane perforations were marginal in 63 (88%) and central in 9 (12%) patients. Attic cholesteatomas were found in 23 (32%) patients, and the remaining cholesteatomas originated from the mesotympanum in 49 (68%) patients. Cholesteatoma is found to be limited to the tympanic cavity and/or attic in 31 (43%) ears, extending into the antrum in 36 (50%) ears, and filling the entire mastoid bowl in 5 (7%) ears.

Major complications caused by the disease included 1 case of brain abscess, 1 case of deafness, 2 cases of facial nerve paralysis, 2 cases of labyrinthine fistula, and 4 cases of meningitis. Cholesteatoma recurrence was noticed in 5 (7%) patients; as shown in the **Figure**, 4 (80%) occurred between 2 and 7 years postoperatively. Ten years after surgery, 69 (96%) of the ears were dry. The tympanic membrane was intact in 56 (78%) patients. Five patients (7%) underwent revision operations for residual cholesteatoma; the most common sites of recurrence were in the sinus tympani in 2 cases, the supratubal region in 1 case, the footplate in 1 case, and the hypotympanum in 1 case. The major predisposing factor for recurrence was retraction, especially in the posterior superior quadrant.

Overall, hearing was better than 40 dB in 30 (42%) patients and between 40 and 60 dB in 39 (54%), and 3 (4%) patients had poor hearing (>60 dB) or were deaf.

COMMENT

This study was designed to evaluate the long-term prognosis of one of the common treatments of cholesteatoma of the ear—the CWD mastoidectomy. According to results from a previous study in which 90 patients who underwent CWU mastoidectomy for cholesteatoma were evaluated, a recurrence rate of 25% was reported after a mean follow-up of 9.2 years.⁹ Other investigators reported a recurrence rate of 6.3% in patients with attic cholesteatomas after a mean follow-up of 11 years.¹³ Investigators in another recent study reported results of a staged combined approach tympanoplasty in a series of 151 patients with cholesteatomas after a mean follow-up of 14.5 years.⁷ They detected 26.5% failures (recurrence), 47.5% of which were due to attic retraction pockets, and 10% of which were due to large residual cholesteatomas. The cholesteatoma recurrence rate in their patients with less

than 10 years of follow-up was 8.8%, significantly lower than the rate in patients with more than 10 years of follow-up. Our study results showed that 96% of ears were dry 10 years after operation, and the tympanic membrane was intact in 77%. Furthermore, 42% of the patients in our study had a useful hearing level (better than 40 dB), which is comparable with findings in other studies.^{7,8}

The ideal treatment for cholesteatoma remains a 1-stage procedure to eradicate the disease and avoid recurrence.¹⁴ This study revealed a lower recurrence rate after CWD mastoidectomy in comparison with other trends. This finding is confirmed by results of previous studies,^{15,16} although some studies show different results.¹³ Our treatment policy has been to use CWD mastoidectomy for all large cholesteatomas, whereas CWU procedures were used only in patients with small cholesteatomas. The recurrence rate of 7% with the CWD technique is an acceptable result and compares well with previous study results.¹⁷ Some studies showed better results in hearing level after CWU mastoidectomy compared with results after CWD mastoidectomy.^{17,18} Our results showed 30 (42%) patients who underwent CWD mastoidectomy had a hearing level of 40 dB or better, and 39 (54%) had a hearing level of 60 dB or better.

The higher recurrence rate in those who underwent CWU mastoidectomy may raise the hypothesis that posterior canal wall removal in some patients could be essential for total eradication of cholesteatoma. In fact, it can denote the importance of disease removal in the surgical procedure. Obviously, it is possible to improve the surgical technique with new technologies. Hence, techniques in which side-viewing rigid endoscopes are used for better viewing of the less visible corners of the cavity¹⁷ and computed tomographic evaluation before mastoid surgery and during yearly follow-ups¹⁹ are highly recommended.

Submitted for Publication: November 20, 2005; final revision received March 4, 2006; accepted April 4, 2006.

Correspondence: Mohammad Ajalloueyan, MD, Department of Otolaryngology and Head and Neck Surgery, Baqiyatallah University of Medical Sciences, Tehran, Iran (ajall2001@yahoo.com).

Financial Disclosure: None reported.

Acknowledgment: I thank the invaluable nonfinancial assistance of the medical records division of Baqiyatallah Hospital, Mohammad Hosein Kalantar Motamedi, DMD, for assistance in preparation of this manuscript, and Javadi Ali, MD, for the postoperative care of the patients.

REFERENCES

1. Uchida Y, Ueda H, Nakashima T. Bezold's abscess arising with recurrent cholesteatoma 20 years after the first surgery: with a review of the 18 cases published in Japan since 1960. *Auris Nasus Larynx*. 2002;29:375-378.
2. Atlas MD, Paramasvaran S. Cholesteatoma—a dangerous condition. *Aust J Otolaryngol*. 1996;7:394-397.
3. Tos M, Lau T. Attic cholesteatoma: recurrence rate related to observation time. *Am J Otol*. 1988;9:456-464.
4. Quaranta A, Cassano P, Carbonara G. Cholesteatoma surgery: open vs closed tympanoplasty. *Am J Otol*. 1988;9:229-231.
5. Sayed RH. One-stage reconstruction in management of extensive cholesteatoma. *IFOS Int Congr Suppl*. 2003;1240:121-131.
6. Vartiainen E, Nuutinen J. Long-term results of surgical treatment in different cholesteatoma types. *Am J Otol*. 1993;14:507-511.
7. Kapur TR, Jayaramchandran S. Management of acquired cholesteatoma of the middle ear and mastoid by combined approach tympanoplasty: a long-term view. *Clin Otolaryngol*. 1997;22:57-61.
8. Cody DT, McDonald TJ. Mastoidectomy for acquired cholesteatoma: follow-up to 20 years. *Laryngoscope*. 1984;94:1027-1030.
9. Kinney SE. Intact canal wall tympanoplasty with mastoidectomy for cholesteatoma: long-term follow-up. *Laryngoscope*. 1988;98:1190-1194.
10. Ajalloueyan M. Modified radical mastoidectomy: techniques to decrease failure. *Med J Islam Repub Iran*. 1999;9:179-183.
11. Rosenfeld RM, Moura RL, Bluestone CD. Predictors of residual-recurrent cholesteatoma in children. *Arch Otolaryngol Head Neck Surg*. 1992;118:384-391.
12. Richter U, Fedtke T. Reference zero for the calibration of audiometric equipment using "clicks" as test signals. *Int J Audiol*. 2005;44:213-230.
13. Lau T, Tos M. Treatment of sinus cholesteatoma: long-term results and recurrence rate. *Arch Otolaryngol Head Neck Surg*. 1988;114:1428-1434.
14. Hirsch BE, Kamerer DB, Doshi S. Single-stage management of cholesteatoma. *Otolaryngol Head Neck Surg*. 1992;106:351-354.
15. Toner JG, Smyth GD. Surgical treatment of cholesteatoma: a comparison of three techniques. *Am J Otol*. 1990;11:247-249.
16. Silvola J, Palva T. Long-term results of pediatric primary one-stage cholesteatoma surgery. *Int J Pediatr Otorhinolaryngol*. 1999;48:101-107.
17. El-Meselaty K, Badr-El-Dine M, Mandour M, Mourad M, Darweesh R. Endoscope affects decision making in cholesteatoma surgery. *Otolaryngol Head Neck Surg*. 2003;129:490-496.
18. Roger G, Denoyelle F, Chauvin P, Schlegel-Stuhl N, Garabedian EN. Predictive risk factors of residual cholesteatoma in children: a study of 256 cases. *Am J Otol*. 1997;18:550-558.
19. Williams MT, Ayache D. Imaging of the postoperative middle ear. *Eur Radiol*. 2004;14:482-495.