Tracheobronchial Stenosis Following Sulfur Mustard Inhalation

Article *in* Inhalation Toxicology · December 2004

DOI: 10.1080/08958370490506682 · Source: PubMed

4 authors, including:

Mostafa Ghanei
Baqiyatallah University of Medical Sciences

Shahram Akhlaghpoor
Pardis Noor Medical Imaging Center

Jafar Aslani
Baqiyatallah University of Medical Sciences

Inhalation Toxicology, 16:845–849, 2004

ISSN: 0895-8378 print / 1091-7691 online
DOI: 10.1080/08958370490506682

Taylor & Francis
healthsciences

Tracheobronchial Stenosis Following Sulfur Mustard Inhalation

Mostafa Ghanei
Baqiyatallah Medical Sciences University, Research Center of Chemical Injuries, Tehran, Iran

Shahram Akhlaghpoor
Tehran Medical Sciences University, Tehran, Iran

Mehdi Mir Moahammad, Jafar Aslani
Baqiyatallah Medical Sciences University, Research Center of Chemical Injuries, Tehran, Iran

Sulfur mustard inhalation leads to different respiratory complications. In this article, we describe late stenotic effects of mustard gas inhalation on major airways. About 15 yr after exposure, suspect cases suffering from severe respiratory disorders underwent complete workup for central airway stenosis. Patients were evaluated with bronchoscopy and tracheal computerized tomography scan. The mean age of patients was 43 ± 8 yr. The mean exposure time was 16 ± 0.7 yr. The mean time between injury and diagnosis of tracheobronchial stenosis was 11.7 ± 4.8 yr. Among the 33 referred cases with no other risk factor of stenosis, 8 cases had significant stenosis in their major airways, confirmed by tracheal computerized tomography scan and bronchoscopy. We conclude that direct toxic effects of sulfur mustard can lead to tracheobronchial stenosis with different degrees of involvement ranging from diffuse tracheal stenosis to stenosis of the isolated left main bronchus or glottic and subglottic stenosis.

It is documented that thousands of Iranian people have been exposed to chemical warfare agents (CWA) during the Iran–Iraq war from 1983 to 1988 (Security Council of the United Nations, 1986). Among CWA, sulfur mustard (HD) was used widely against both military and civilian population by Iraqi forces in the Iran–Iraq war (Security Council of the United Nations, 1986). HD is stored as a liquid and is not likely to change into a vapor immediately if it is released at ordinary temperatures. As a liquid, it is colorless when pure and it is brown when mixed with other chemicals. It is odorless when pure, but can have a slight garlic smell when mixed with other chemicals. It dissolves easily in fats, oils, alcohol, and gasoline. HD dissolves slowly in unstirred water, but within minutes in stirred water. When it does dissolve, it reacts with water and turns into different chemicals (Rosemond et al., 2003). HD primarily affects the eyes, skin, and respiratory tract. Symptom onset ranges from 1 to 12 h after exposure (Sohrabpour, 1987). Effects on the skin range from erythema and edema to necrosis and vesicles. Although blisters generally are formed by 16–24 h after exposure, they can form as late as 7–12 days. Tracheobronchitis usually results several hours after exposure. Other respiratory manifestations can range from bronchospasm and bronchial obstruction to hemorrhagic pulmonary edema. Eye symptoms include erythema, edema, lachrymation, and discomfort, with more severe exposures resulting in severe pain, blepharospasm, iritis, and blindness (either temporary or permanent) (Bismuth et al., 2004).

Late pulmonary complications of HD, ranging from 6 mo to years after the exposure, include airway hyperreactivity (Calvet et al., 1994) and chronic bronchitis, manifesting with chronic cough and sputum production (Emad & Rezaian, 1997; Case & Lea, 1955).

Structural damages of the respiratory tract have been described since the very beginning of the investigations on the HD-exposed victims (Winternitz & Finney, 1920). According to one study (Freitag et al., 1991), secondary complications including chronic infections, suppurative bronchitis, and extensive stenotic process of the entire tracheobronchial tree with life-threatening sequelae have been detected in HD-exposed

Received 21 June 2004; accepted 7 July 2004.
This work was done at Baqiyatallah Medical Sciences University, Research Center of Chemical Injuries, Tehran, Iran.
Address correspondence to Dr. Mostafa Ghanei, MD, Professor of Medicine, Pulmonologist, Baqiyatallah Medical Sciences University, Research Center of Chemical Injuries, Mollasadra Street, PO Box 19945-546, Tehran, Iran. E-mail: m.ghanei@bmsu.ac.ir

cases. After a delay of up to 15 mo, scars, ulcers, and strictures develop in the central airways (Freitag et al., 1991). In this study, we describe late stenotic effects of mustard gas inhalation on major airways.

METHODS AND MATERIALS

According to the reports, approximately 34,000 Iranian people, both civilian and military, have been exposed to CWA during the Iran–Iraq war from 1983 to 1988 (Khateri et al., 2003). A governmental association responsible for supporting the war victims and veterans' affairs has gathered filed records of almost all the known victims, who have regular biannual referrals to special clinics held by that association. About 15 yr after exposure, in September 2002, the association called on all provinces to refer all suspect cases suffering from severe respiratory disorder for a complete checkup and for management arranged for treatment of central airway stenosis. As the first step, history taking and physical examination, chest x-ray, and pulmonary function test (PFT) were performed by physicians in local hospitals. Based on the findings of the first-step evaluations, the suspected cases of central airway stenosis were referred for further investigation and management to Baqiyatallah Hospital (our center), where radiological studies and bronchoscopy were performed for all of them (described later). The suspect cases with the following criteria were included in the present study.

Inclusion criteria.

1. Exposure to chemical warfare documented by military health services. Exposure in this study is defined as a single, high-dose exposure to a chemical agent that causes transient or permanent disability in exposed people.
2. The medical records of the patents documenting the cares received for chemical exposure. According to their records, all injured victims were transferred to local military hospitals, where based on signs and symptoms the types of chemical agents were determined. The physicians treated the patients using standard protocols determined by military health services.
3. Inspiratory steroids and/or unilateral wheezing in physical examination.
4. Decrease of unilateral lung volume and/or signs of localized bronchiectasis in chest x-ray.
5. Flow limitation on maximal inspiratory and expiratory flow volume curves in PFT.

Exclusion criteria.

1. Previously diagnosed patients with lung cancer, tuberculosis (TB), and burn injury.
2. History of intubation, intensive care unit (ICU) admission, or upper airway surgery.

Radiologic Study

Spiral CT scans were obtained with a Somatom Plus 4 CT scanner (Siemens Medical Systems, Germany) at 120 kVp and 200–250 mA with 3 mm collimation and 1.5 pitch and subsecond 360° rotation (0.75 s). Length of the scanned volume was 6–12 cm and acquisition time was 10–20 s so that acquisition could be completed during a single breath-hold after hyperventilation for 1 min. Intravenous contrast material was not administered. Axial images were reconstructed using the kernel 50 algorithm. The CT examinations were performed at full inspiration.

Overlapping images were retrospectively reconstructed at 1.5-mm intervals with a 180° linear interpolation algorithm (a standard algorithm) and a narrowed 20-cm field of view was prepared, which included the proximal airways. Forty to 80 images were generated with 512 by 512 matrix. The CT data were transferred to a Tiani workstation (Tiani, Austria) and three-dimensional (3D) color volume renderings of the major airways were generated. The CT scans were reviewed by a radiologist in a blind manner.

Bronchoscopy

All procedures were performed by a bronchoscopist assisted by an experienced procedure nurse, after applying topical anesthesia (Lidocaine, aerosolized) to the patient's nasopharynx and larynx. Approximately 5 ml of 1% lignocaine jelly was instilled into each nostril. The patient was sedated with small incremental doses of iv midazolam until judged to be lightly asleep. During the procedure, the patients were provided with supplemental oxygen at a rate of 3 L/min through nasal prongs directed into the mouth and monitored for oxygen saturation, pulse rate, and possible arrhythmias. Alarms were set to go off if the saturation fell below 90% or if the pulse was below 55 or above 130. Supplemental oxygen was continued until the patient was awake following the procedure. The Flexible Fiberoptic Bronchoscopy (FFB) was performed using the transnasal route. Routine administration of sedatives or anxiolytics was avoided. However, in order to improve patient comfort and tolerance, iv midazolam was administered during FFB if deemed necessary by the bronchoscopist. In our institution, most bronchoscopies are performed without premedication other than topical anesthesia.

RESULTS

The total number of the suspect cases of tracheobronchial stenosis (TBS) who were referred for evaluation and met our criteria was 33. The mean age was 43 ± 8 yr, the mean time from exposure was 16 ± 0.7 yr, and the mean interval between injury and TBS diagnosis was 11.7 ± 4.8 yr. Medical history of all patients revealed the presence of long-term chronic productive cough, dyspnea, and bloody streak hemoptysis. As described in the methods, there was no history of tuberculosis, which was confirmed by negative bronchial lavage smear and culture for mycobacterium tuberculosis in all patients, and none had burn injury due to direct effects of explosion in their head and neck. Chest CT and bronchoscopy confirmed the existence of

TABLE 1
Summary of the clinical data of patients with tracheobronchial strictures due to sulfur mustard

Patient	Age (yr)	Site of stenosis	Year of injury	Time of diagnosis	Method of diagnosis
1	38	All part of trachea and left main bronchus	1985	1990	CT and bronchoscopy
2	40	First part of trachea and left main bronchus	1986	1991	CT and bronchoscopy
3	63	Distal trachea and left main bronchus	1985	1995	CT and bronchoscopy
4	48	Left main bronchus	1986	1997	CT and bronchoscopy
5	39	Posterior part of vocal cords and first part of trachea	1986	2001	Bronchoscopy
6	40	Left lower lobe bronchus	1985	2002	Bronchoscopy
7	38	Superior segment lumen of left lower lobe bronchus	1986	2002	Bronchoscopy
8	38	First part of trachea	1987	2002	Bronchoscopy

TBS in 8 of the 33 suspect cases. The demographic data, year of injury, time of diagnosis, method of diagnosis, and sites of stenosis are shown in Table 1. The tracheobronchial CT and bronchoscopic images of four cases are illustrated in Figures 1 to 4. Note that we did not observe any cases with right main bronchus involvement, while the left main bronchus (LMB) was commonly involved.

DISCUSSION

The results of this study indicate that TBS can be considered as a late complication of HD exposure in cases with no other known risk. Structural lung damages such as instability of major airways occur in tracheomalacia, bronchomalacia, and chronic obstructive pulmonary diseases (Shepard, 1995; Dunn et al., 1995), while cartilage destruction and airway stenosis usually occur after infection, intubation, surgery, and lung transplantation (Quint et al., 1995; Kauczor et al., 1996). Tracheal or bronchial stenosis has not yet been reported as late complications of chronic bronchitis. Thus the observed stenosis in HD-exposed patients with no other known risk factors could not be secondary to chronic bronchitis, which is the most common chronic respiratory disease detected following HD exposure (Emad & Rezaian, 1997; Case & Lea, 1955).

The upper airway mucosa is an appropriate heat exchanger. It is believed that this mechanism is due to the natural cooling capacity of the upper airway, which absorbs the heat of gases before reaching trachea. Thus, the thermal injury of HD per se can hardly damage the tracheobronchial mucosa. Taken

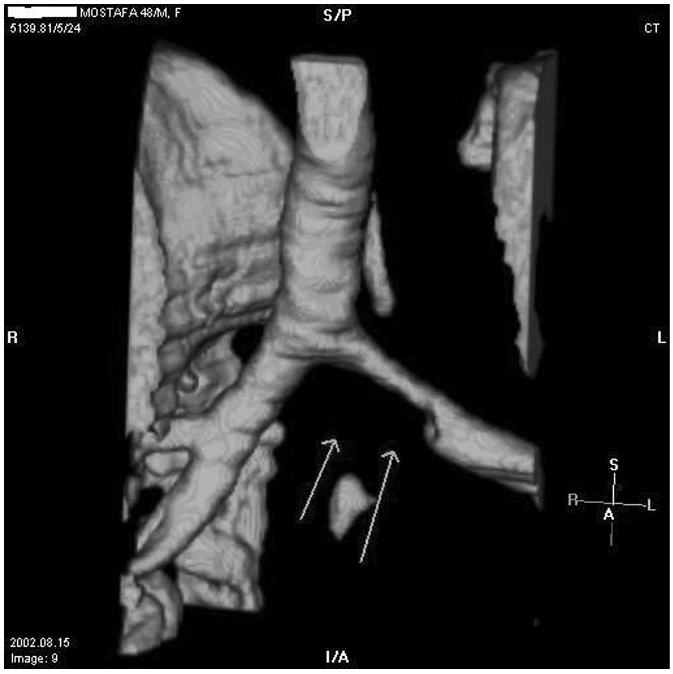

FIG. 1. Three-dimensional reconstruction of thoracic CT scan showing severe left main stem bronchial stenosis.

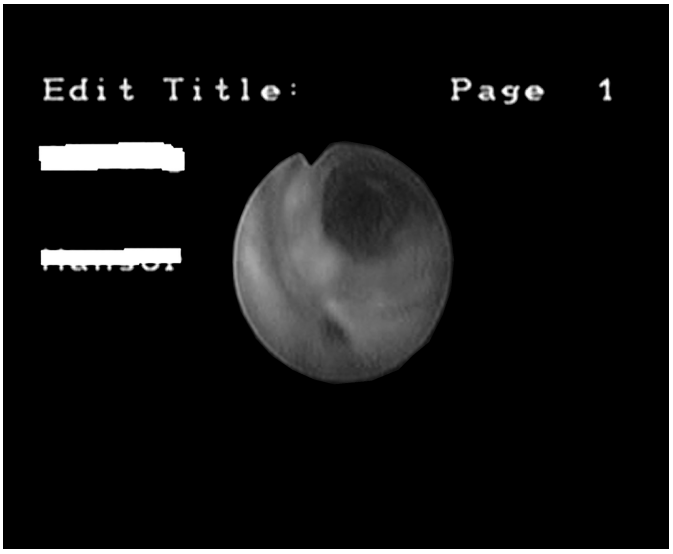

FIG. 2. Bronchoscopic view of patient showing severe left main bronchial stenosis in 40-yr-old man.

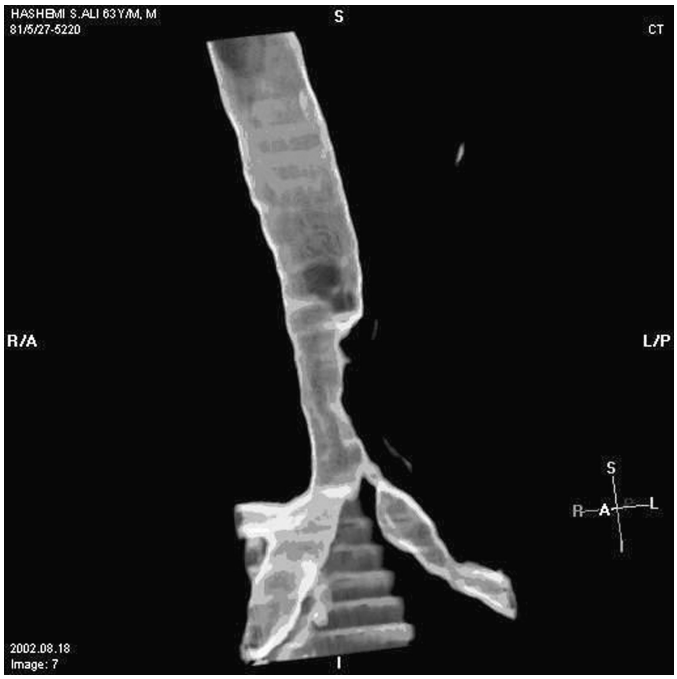

FIG. 3. Three-dimensional reconstruction of thoracic CT scan showing severe distal tracheal and left main bronchial stenosis in 63-yr-old man.

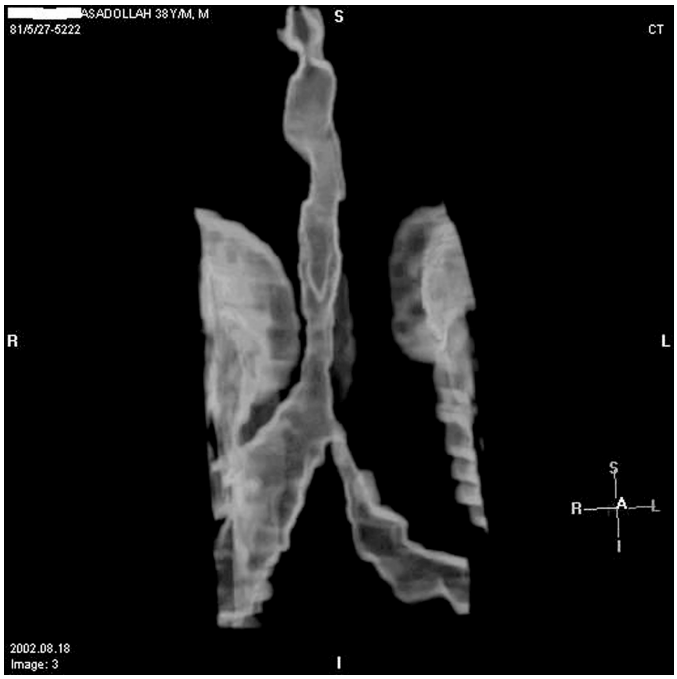

FIG. 4. Three-dimensional reconstruction of thoracic CT scan showing severe total tracheal and left main bronchial stenosis in 38-yr-old man.

together, the TBS in HD-exposed cases with no other known risk factors could be attributed to the primary toxic effects of HD inhalation.

Previous studies show that irritant gases such as aldehydes, ammonia, and hydrochloric acid could result in severe tracheobronchitis with sloughing of the mucosa, which can be followed by TBS (Crapo, 1990). Clinical and experimental studies indicate that in the presence of intact basal membrane layer, early repair occurs following the inhalation injury (Shimazu et al., 1987). With the basal membrane layer destroyed (at the time of exposure to irritant gases or due to further trauma) and consequently its delayed repair, granulation tissue and stenosis may be established. It is evident that sulfur mustard is a potent alkylating and blistering agent that reacts with membranes, RNA, and proteins (Somani & Babu, 1989). Considering these properties, one can hypothesize that the mechanism of TBS stenosis in HD-exposed patients is its direct toxic effects, even though many questions remain to be answered yet. For instance, although thousands of people have been exposed to these toxic agents with different exposure level during the war, TBS was not reported as a common finding among them (described later).

According to the reports of previous studies, burn-induced tracheal stenosis has features distinctive from those that occur after simple intubation or tracheostomy (Yang et al., 1999), indicating that inhalation injury alone plays an important role in tracheal stenosis. Furthermore, it was noted that burn injury of the upper airways also has features distinctive from burn-induced damages to the bronchus and lung parenchyma. Unlike the lower airway injury, which manifests soon after burns, compromise of the upper airway may develop relatively late with tracheal stenosis following a symptom-free period (Yang et al., 1999). This is compatible with the characteristic of the injury in our study, although the mechanism of damage is different here as discussed earlier. Our study also shows that the location of tracheal stenosis due to HD inhalation differs from the stenosis following prolonged intubation or tracheostomy. We did not observe any case with right main bronchus involvement, while left main bronchus (LMB) was commonly involved. Involvement of LMB can be referred to the aortic arch compression on LMB. Continuous pulsating external compression of the damaged LMB by the aorta may have led, over a period of years, to focal narrowing of the injured left but not the right main bronchus. The length, diameter, and angle of LMB might render it more susceptible to HD-induced stenosis as well.

To our knowledge there were few studies determining prevalence of TBS following HD exposure (Freitag et al., 1991). Even though we did not examine all exposed patients for TBS and confined our study to the suspect cases based on the primary clinical evaluations, according to anecdotal evidence it seems to be a rare complication of HD exposure. It may be instructive to compare the prevalence of upper airway stenosis in burn injury and in HD exposure. In a study of 18 patients with burn injury, 3 of them developed tracheal stenosis,

without prior intubation (Gaissert et al., 1993). In a more recent study, reviewing the records of 1878 burn patients showed that only 7 cases (0.37%) presented with tracheal stenosis after an average of 4.4 yr follow-up (Yang et al., 1999). Our radiographic and bronchoscopic findings confirmed the existence of stenosis in 8 of the 33 suspect cases, who were in turn selected from thousands of HD-exposed cases by an extensive screening project. Thus, it could be concluded that prevalence of upper airway stenosis is relatively low in both burn injury and HD exposure.

In conclusion, HD exposure can lead to TBS with different degrees of involvement as a rare but debilitating complication; this can range from diffuse TBS to the isolated LMB and glottic and subglottic stenosis. Physicians involved in management of these patients should be urged to be aware of the possibility of TBS and acquire appropriate degrees of expertise in early diagnosis and management of this complication. Based on our data, the applicability of bronchoscopy seems to be higher than that of CT scan in evaluation of subglottic stenosis, especially after the second division of airways. However, determining the length of involvement and the severity of stenosis in special cases requires evaluation by CT scan. Thus, both bronchoscopic examination and CT scan should be performed in cases suspected of TBS. As described earlier by Freitag and colleagues (1991), in diagnosed cases with TBS, implementation of stents can be life-saving.

REFERENCES

Bismuth, C., Borron, S. W., Baud, F. J., and Barriot, P. 2004. Chemical weapons: Documented use and compounds on the horizon. *Toxicol. Lett.* 149(1–3):11–18.

Calvet, J. H., Jarreau, P. H., Levame, M., Ortho, M. P., Lorino, H., Harf, A., and Macquin-Mavier, I. 1994. Acute and chronic respiratory effects of sulfur mustard intoxication in guinea pig. *J. Appl. Physiol.* 76:681–688.

Case, R. A. M., and Lea, A. J. 1955. Mustard gas poisoning, chronic bronchitis and lung cancer. *Br. J. Prev. Soc. Med.* 9:62–68.

Crapo, R. O. 1990. Causes of respiratory injury. In *Respiratory injury: Smoke inhalation and burns*, eds. E. F. Hoponik and A. M. Munster, pp. 51–56. New York: McGraw-Hill.

Dunn, W. F., Hubmayr, R. D., Pairolero, P. C., Sheedy, P. F., Edell, E. S., and Nelson, S. B. 1995. The assessment of major airway function in ventricular dependent patient with tracheomalacia. *Chest* 97:939–942.

Emad, A., and Rezaian, G. R. 1997. The diversity of the effects of sulfur mustard gas inhalation on respiratory system 10 years after a single, heavy exposure: Analysis of 197 cases. *Chest* 112:734–738.

Freitag, L., Firusian, N., Stamatis, G., and Greschuchna, D. 1991. The role of bronchoscopy in pulmonary complications due to mustard gas inhalation. *Chest* 100(5):1436–1441.

Gaissert, H. A., Lofgren, R. H., and Grillo, H. C. 1993. Upper airway compromise in burns: Complex strictures of the larynx and trachea and their management. *Ann. Surg.* 218:672.

Kauczor, H. U., Buchenroth, M., Heussel, C. P., and Mayer, E. 1996. Functional CT imaging of the lung in axial and coronal plane after single lung transplantation. *Fortshr. Roentgenstr.* 164:441–444.

Khateri, S., Ghanei, M., Keshavarz, S., Soroush, M., and Haines, D., 2003. Incidence of lung, eye, and skin lesions as late complications in 34,000 Iranians with wartime exposure to mustard agent. *J. Occup. Environ. Med.* 45(11):1136–1143.

Quint, L. E., Whyte, R. I., Kazerooni, E. A., Martinez, F. J., Cascade, P. N., Lynch, J. P., III, and Deeb, G. M. 1995. Stenosis of the central airways: Evaluation by using helical CT with multiplaner reconstruction. *Radiology* 194:871–877.

Rosemond, Z. A., Belbo, D., and Amata, R. 2003. *Toxicological profile for sulphur mustard.* U.S. Department of Health and Human Services, Public Health Service, Agency for Toxic Substances and Disease Registry, September.

Security Council of the United Nations. 1986. *Reports of specialists appointed by the Secretary General to investigate allegations by the Islamic Republic of Iran concerning the use of chemical weapons*. New York. Document S/16433.

Shepard, J. O. 1995. The bronchi: An imaging perspective. *J. Thorac. Imaging* 10:236–254.

Shimazu, T., Yukioka, T., Hubbard, G. B., Langlinais, P. C., Mason, A. D. Jr., and Pruitt, B. A. Jr. 1987. A dose-responsive model of smoke inhalation injury. *Ann. Surg.* 206:89–97.

Sohrabpour, H. 1987. Observation and clinical manifestations of patients injured with mustard gas. *Med. J. Islamic Repub. Iran* 1408:32–37.

Somani, S. M., and Babu, S. R. 1989. Toxicodynamics of sulphur mustard. *Int. J. Clin. Pharmacol. Ther. Toxicol.* 27:419–435.

Winternitz, M. C., and Finney, W. P., Jr. 1920. The pathology of mustard poisoning. In *Pathology of war gas poisoning*, ed. M. C. Winternitz, pp. 101–111, New Haven, CT: Yale University Press.

Yang, J. Y., Yang, W. G., Chang, L. Y., and Chuang, S. S. 1999. Symptomatic tracheal stenosis in burns. *Burns* 25(1):72–80.