



## CASE REPORT

# Massive Ascites, Protein Losing Enteropathy and Pseudo-Obstruction as Rare Manifestations of Systemic Lupus Erythematosus in a known case of Immune Thrombocytopenic Purpura

Ramezan Jafari<sup>1</sup>, Hassan Abolghasemi<sup>2</sup>, Mohammad Javanbakht<sup>3</sup>, Zahra Najjari<sup>2</sup>, Fatemeh Beiraghdar<sup>2,3</sup>, Zohreh Kavehmanesh<sup>2,4\*</sup>

<sup>1</sup>Department of Radiology, Baqiyatallah University of Medical Sciences, Tehran, Iran and Chemical Injuries Research Center, Baqiyatallah University of Medical Sciences, Tehran, Iran

<sup>2</sup>Department of Pediatrics, Baqiyatallah University of Medical Sciences, Tehran, Iran

<sup>3</sup>Nephrology and Urology Research Center, Baqiyatallah University of Medical Sciences, Tehran, Iran

<sup>4</sup>Gastroenterology and Liver Diseases Research Center, Baqiyatallah University of Medical Sciences, Tehran, Iran

## ARTICLE INFO

### Article History:

Received: 21.02.2020

Accepted: 18.05.2020

### Keywords:

Systemic lupus erythematosus

Ascites

Pseudo-obstruction

Lymphadenopathy

Protein-losing enteropathy

Peritoneal involvement

Immune thrombocytopenic

Purpura

### \*Corresponding author:

Zohreh Kavehmanesh,

#343 Mollasadra living complex,

Kharazmi St, Mollasadra Ave, Tehran,

1435913554, Iran

Tel: +98 21 88069866

Fax: +98 21 81263716

Email: [z\\_kaveh@hotmail.com](mailto:z_kaveh@hotmail.com)

## ABSTRACT

Systemic lupus erythematosus (SLE) is an autoimmune inflammatory disease with diverse clinical manifestations involving multiple organ systems. Peritoneal involvement as a sign of gastrointestinal disease in SLE is a rare condition. Massive ascites as the initial manifestation of SLE is an extremely rare situation. Here, we report a 13-year-old female with bile-stained vomiting, ascites and signs of pseudo-obstructions with a past medical history of immune thrombocytopenic purpura (ITP) who was later diagnosed to have SLE.

Please cite this article as: Jafari R, Abolghasemi H, Javanbakht M, Najjari Z, Beiraghdar F, Kavehmanesh Z. Massive Ascites, Protein Losing Enteropathy and Pseudo-Obstruction as Rare Manifestations of Systemic Lupus Erythematosus in a known case of Immune Thrombocytopenic Purpura. IJBC 2020; 12(2): 67-69.

## Introduction

Generalized lymphadenopathy has been described as the initial symptom of SLE if other etiologies are excluded.<sup>1</sup> Peritoneal involvement and massive painful ascites as a gastrointestinal manifestation of SLE is extremely rare.<sup>2</sup> Intestinal pseudo-obstruction in SLE could be explained by a bowel injury causing non-mechanical obstruction.<sup>3</sup> Protein losing enteropathy which is characterized by generalized edema and severe hypoalbuminemia is reported as another rare gastrointestinal manifestation of SLE which was observed in our patient.<sup>4</sup>

## Case Presentation

A 13-year-old girl was referred to our hospital with a history of fever and abdominal pain for the last two weeks. On admission, she complained of fever and fatigue, night sweats, abdominal pain and bile-stained vomiting. The parents mentioned a history of immune thrombocytopenic purpura (ITP) seven years ago which was resolved. The patient had a recent excisional biopsy of posterior cervical lymph nodes in another hospital which was reported as reactive lymphadenitis showing follicular hyperplasia. Physical examination was characterized with

fever, bilateral palpable cervical lymphadenopathies and abdominal distension which showed shifting dullness in favor of ascites. Laboratory tests showed a normal complete blood count, hypoproteinemia (Albumin 2.6 g/dL) and mild increase in LDH. Abdominal fluid analysis was suggestive of an exudative ascites with a serum-ascites albumin-gradient (SAAG) of 0.4 with no malignant cells. PCR for bacterial infections and mycobacterium tuberculosis was negative. Serologic assessment for viral infections were negative.

Abdominal ultrasound revealed mild splenomegaly, moderate to severe ascites and wall thickening at descending colon and sigmoid up to 7.1 mm. Color doppler ultrasound of hepatic, portal, splenic and mesenteric arteries and veins was normal. Chest, abdominal and pelvic CT-scan revealed mild left pleural effusion, large amount of ascites, small intestinal dilatation with air-fluid level and intestinal wall edema (Figure 1). Esophagogastroduodenoscopy was performed which histopathology indicated mild esophagitis and multiple erosions in gastric fundus along with chronic active gastritis. She was scheduled to receive conservative treatment and was discharged from the hospital.

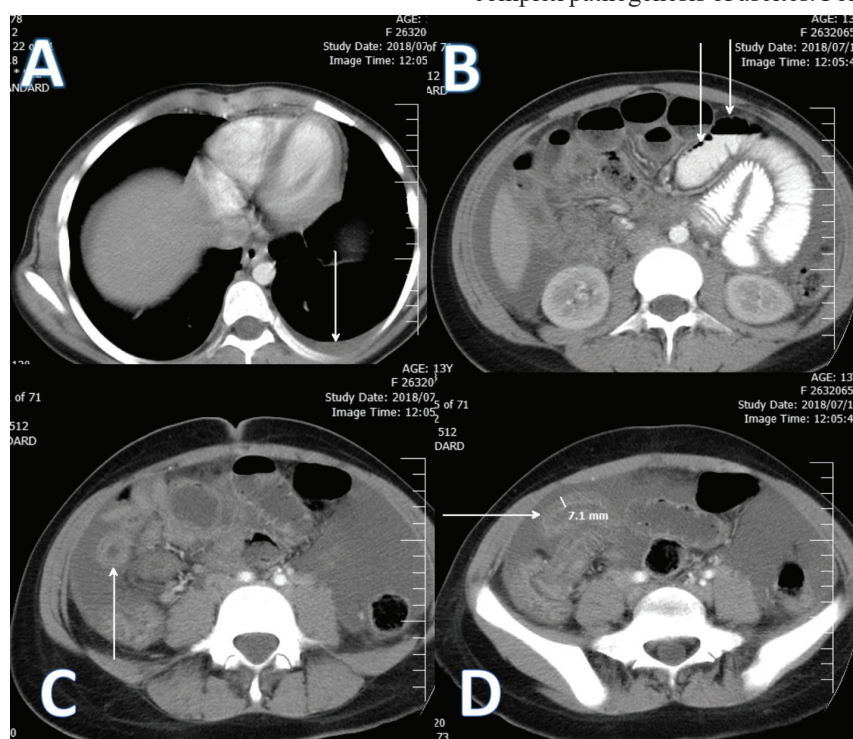
She was readmitted five days later with vomiting and acute abdominal pain. Abdominal ultrasound demonstrated free fluid in abdominopelvic cavity with small bowel end loop thickening suspicious for appendicitis. A mini-laparotomy and appendectomy was performed. Large amount of ascites with no granulation was observed during the surgery. Histopathology revealed congested vermiform appendix. Colonoscopy was also performed for further follow up which showed diffuse congestion in descending colon and rectosigmoid. Pathology showed terminal ileitis, chronic non-destructive and crypt-destructive colitis.

At this time, complete blood count showed mild to moderate thrombocytopenia ( $54-140 \times 10^9/\mu\text{L}$ ). The constellation of clinical and hematologic findings led us to strongly suspect SLE. She underwent further testing for SLE which showed increased ESR, hypocomplementemia, ANA titer 0.65 and Anti-dsDNA 19.5 U/mL. Further investigations for familial Mediterranean fever and C1 esterase inhibitor deficiency were negative. The patient was diagnosed with SLE and received methyl prednisolone pulses for 3 days followed by prednisolone and oral colchicine for abdominal pain. After 3 days of treatment, her symptoms improved rapidly and a month later she had a complete recovery. Informed consent is obtained according to guidelines from the patient parent.

## Discussion

Our patient had bilateral cervical lymphadenopathy, massive painful ascites, protein-losing enteropathy and intestinal pseudo-obstruction which all could be rare manifestations of SLE.<sup>2, 4-7</sup> Lymphadenopathy could be seen in the course of SLE and is indicative of active disease.<sup>1</sup> Generalized Lymphadenopathy is commonly observed in infections (viral, bacterial, fungal, parasitic and rickettsial), immunological diseases (Kikuchi-Fujimoto's disease, sarcoidosis and Castleman's disease) and malignancies (Hodgkin and non-Hodgkin lymphoma, leukemia and some non-hematologic malignancies).<sup>1, 8, 9</sup> Histopathological findings of SLE in lymph nodes are non-specific and include follicular hyperplasia and diffuse infiltration of immunoblasts and plasma cells with increased vascularity.<sup>1</sup>

In the case of ascites, the first step is to analyze the fluid determining the serum ascitic albumin gradient (SAAG). There are different factors involved in the complex pathogenesis of ascites. Portal hypertension and



**Figure 1:** Four axial CT-scan images with IV and oral contrast: A) mild left pleural effusion, B) massive ascites, intestinal dilatation with air-fluid level and string of bead sign, C and D) intestinal wall swelling and edema and target sign on post contrast images.

peritoneal disease are among main risk factors. Portal hypertension causes a transudate ascites with a SAAG >1.1 due to increased vascular hydrostatic pressure, whereas peritoneal damage (inflammatory or neoplastic) produces an exudate ascites with SAAG <1.1 due to vessel hyperpermeability (the same as our patient).<sup>2, 5, 10, 11</sup> In SLE, ascites may result from aggregation of lymphocytes and plasma cells, deposition of immune complexes in the peritoneum, activation of complement system and peritoneal vasculitis. Therefore, lupus ascites is usually exudative and demands an extensive investigation.<sup>2, 5, 6, 11</sup>

Pleural effusion could also be noted secondary to the communication with the peritoneal cavity.<sup>6</sup> The cause of intestinal pseudo-obstruction in SLE remains unclear and could be due to intestinal smooth muscle injury and mesenteric vasculitis resulting in hypomotility. The absence of mechanical and obstructive factors and observation of a grossly dilated bowel, abnormal bowel gas pattern, diffuse bowel wall thickening and signs of peritonitis on abdominal imaging are in favor of the diagnosis of pseudo-obstruction in which surgical intervention is not indicated and should be carefully avoided.<sup>3, 5, 7</sup>

Hypoproteinemia in SLE results from lupus nephritis or protein losing enteropathy. So, in every case of SLE with generalized edema and circumferential bowel wall thickening, protein losing enteropathy should be considered.<sup>4</sup>

The patient had a previous history of ITP whose thrombocytopenia recurred during the course of the pregnancy. Thrombocytopenia in SLE might be acute or chronic in onset. The acute onset of ITP is usually related to the active phase of the SLE, while chronic ITP is more common and less likely to be related to the disease activity. ITP could be presented in up to 16% of the patients with SLE even 10 years earlier. It has been reported that 3-15% of patients with ITP eventually develop SLE.<sup>8</sup> Also, ITP may precede the onset of lymphoma.<sup>12</sup> Among different lymphoproliferative disorders, ITP has a prevalence of about 2% in lymphomas. So lymphoreticular malignancy should be considered in any patient with a history of ITP and proper work-up for malignancy should be undertaken individually.<sup>13</sup>

### Conclusion

Gastrointestinal manifestations of SLE are nonspecific. Peritoneal involvement and protein losing enteropathy with pseudo-obstruction syndrome is a rare complication of SLE that its diagnosis requires extensive investigation to rule out the other pathology.

**Conflict of Interest:** None declared.

### References

1. Afzal W, Arab T, Ullah T, Teller K, Doshi KJ. Generalized lymphadenopathy as presenting feature of systemic lupus erythematosus: Case report and review of the literature. *J Clin Med Res.* 2016; 8(11):819–23. doi: 10.14740/jocmr2717w. PubMed PMID: 27738484. PubMed Central PMCID: PMC5047021.
2. Hammami S, Bdioui F, Ouaz A, Loghmari H, Mahjoub S, Saffar H. Successful treatment of massive ascites due to lupus peritonitis with hydroxychloroquine in old-onset lupus erythematosus. *Pan Afr Med J.* 2014; 18:165. doi: 10.11604/pamj.2014.18.165.2080. PubMed PMID: 25422683. PubMed Central PMCID: PMC4239444.
3. Álvarez-Perdomo LC, Pedraza-Atahualpa PA, Mondragón-Cardona AE, Escobar-Montealegre F, Jiménez-Canizales CE. An unusual case of intestinal pseudo-obstruction presenting in an adolescent with juvenile-onset systemic lupus erythematosus: A diagnostic challenge. *Egypt Rheumatol* 2018; 40: 213. doi: 10.1016/j.ejr.2017.10.003.
4. Chen Z, Li MT, Xu D, Yang H, Li J, Zhao JL, et al. Protein-losing enteropathy in systemic lupus erythematosus: 12 years' experience from a Chinese academic center. *PLoS One.* 2014;9:e114684. doi: 10.1371/journal.pone.0114684.
5. Zhou L, Ming Sun C, Li Chen W, Zhang H, Wang P, Wu J. Massive and painful ascites as a presenting manifestation of systemic lupus erythematosus flare: a case report and literature review. *Rev Med Chil.* 2014;142:255-60. doi: 10.4067/S0034-98872014000200016. PubMed PMID: 24953116.
6. McVorrán S, Song J, Pochineni V, Abrudescu-Opran A. Systemic lupus erythematosus presenting with massive ascites: a case of pseudo-pseudo meigs syndrome. *Case Rep Rheumatol.* 2016;2016:8701763. doi: 10.1155/2016/8701763. PubMed PMID: 25546663.
7. Wang JL, Liu G, Liu T, Wei JP. Intestinal pseudo-obstruction in systemic lupus erythematosus: a case report and review of the literature. *Medicine.* 2014; 93: e248. doi: 10.1097/MD.0000000000000248.
8. Bashal F. Hematological disorders in patients with systemic lupus erythematosus. *Open Rheumatol J.* 2013;7:87-95.
9. Melikoglu MA, Melikoglu M. The clinical importance of lymphadenopathy in systemic lupus erythematosus. *Acta Reumatol Port.* 2008; 33:402-6.
10. Liu R, Zhang L, Gao S, Chen L, Wang L, Zhu Z, et al. Gastrointestinal symptom due to lupus peritonitis: a rare form of onset of SLE. *Int J Clin Exp Med.* 2014;7:5917-20. PubMed PMID: 25664133.
11. Pott Júnior H, Amate Neto A, Teixeira MA, Provenza JR. Ascites due to lupus peritonitis: a rare form of onset of systemic lupus erythematosus. *Rev Bras Reumatol.* 2012; 52:116-9. PubMed PMID: 22286651.
12. Marino S, Di Cataldo A, Magro G, D'Amico S, Spina M, Benedetto V, et al. A difficult diagnosis of Hodgkin lymphoma due to immune thrombocytopenia. *Clin Case Rep.* 2015;3(3):179–82. doi:10.1002/ccr3.176.
13. Visco C, Rodeghiero F. Immune thrombocytopenia in lymphoproliferative disorders. *Hematol Oncol Clin North Am.* 2009; 23:1261-74. doi: 10.1016/j.hoc.2009.08.006. PubMed PMID: 19932433.