




Since January 2020 Elsevier has created a COVID-19 resource centre with free information in English and Mandarin on the novel coronavirus COVID-19. The COVID-19 resource centre is hosted on Elsevier Connect, the company's public news and information website.

Elsevier hereby grants permission to make all its COVID-19-related research that is available on the COVID-19 resource centre - including this research content - immediately available in PubMed Central and other publicly funded repositories, such as the WHO COVID database with rights for unrestricted research re-use and analyses in any form or by any means with acknowledgement of the original source. These permissions are granted for free by Elsevier for as long as the COVID-19 resource centre remains active.



## Correspondence

## Vertical transmission of COVID-19 in a 1-day-old neonate

Dear Editor

COVID-19 has led to disruption of health care in the newborns and pregnant women [1], but its clinical features are largely still unknown [2]. Therefore, the primary detection of COVID-19 may provide more desirable outcomes in pregnant women [3]. Previously, we reported a 6 months old infant with COVID-19, who was born prematurely at 28 weeks [4].

In this report, a 29-year-old pregnant woman with a history of hypothyroidism for 2 years and gestational diabetes mellitus (GDM) for 6 months was admitted to the delivery ward of a maternity hospital in Tehran (Iran) due to labor pains. The mother had no contact history with suspected and infected patients. She also had no fever, cough, dyspnea or gastrointestinal symptoms. But she lived in areas with a high prevalence of COVID-19, and blood tests revealed a normal range for the mother.

A term male newborn was born by caesarean section on April 11th, 2020 with a birth weight of 4300, a height of 47 cm and a head circumference of 35 cm. Furthermore, Apgar scores were 8 and 9 at 1 and 5 minutes after birth, respectively. Additionally, vital signs were: temperature (36.7 °C), blood pressure (67/39 mm Hg), heart rate (156 beats per minute [bpm]), respiratory rate (72 breaths per minute), oxygen saturation (90%), cyanosis, tachypnea, intercostal and subcostal retractions, grunting and the clinical respiratory score (5–6). Immediately, the newborn was transferred from another hospital to the neonatal intensive care unit (NICU) ward of Shahid Akbar-Abadi Hospital in Tehran (Iran) due to progressive respiratory distress during the first 4 hours after birth. Furthermore, the neonate had no contact with the mother after birth. There was also no skin-to-skin contact after birth due to respiratory distress, and breastfeeding was not performed by the mother.

On the first day after birth, the patient was subjected to sepsis workup and chest X-ray was then requested for the neonate. Routine blood and early biochemical examinations, including white blood cell (WBC) count, venous blood gases (VBG), and C-reactive protein (CRP) were within normal limits. Also, the neonate was treated with ampicillin (50mg/kg/TDS for 24 hours) and amikacin (10mg/kg every 12 h for 24 hours). On the second day, leukocytes levels started dropping, while CRP levels started rising.

Nasopharyngeal swab specimens were taken immediately on day 2 from the newborn because of clinical, paraclinical, and radiologic suspicion of the COVID-19 and the mother (despite lack of symptom) to evaluate COVID-19 by Reverse-Transcription Polymerase Chain Reaction (RT-PCR) assay. Unfortunately, these specimens were not collected for PCR due to a lack of access to the maternal umbilical cord and amniotic fluid. After 24 h, the RT-PCR test results of the neonate and the mother were positive for COVID-19.

Chest radiography in the early hours after birth demonstrated

bilateral scattered opacities preferably in the middle lobe of the right lung (Fig. 1). On examination, the patient had normal echocardiography. Regarding the imaging evidence and the persistence of respiratory distress of newborn, the antibiotics were changed to meropenem (20 mg/kg/TDS) and vancomycin (15 mg/kg/BD) on the second day of birth.

On the third day of birth, the newborn condition changed from high flow nasal cannula (HFNC) to hood with Fio2 (40%) due to reduced distress, retraction and tachypnea intensity. Oxygen therapy was and gradually reduced and discontinued from the fifth day. From the third day of birth, breastfeeding with formula is gradually beginning with a small volume. On this day, mother was discharged from hospital due to the asymptomatic condition.

On the fourth day, the newborn was discharged from the hospital in stable condition and quarantined with her parents for 14 days to maintain isolation at home. Then, we followed them up to an afebrile condition without clinical signs of COVID-19, when the neonate symptoms were starting to resolve and oxygen saturation started rising (98%) so over the fourth day, resulting in negative RT-PCR test of the neonate and the mother.

In summary, conventional antiviral therapy has not been started due to possible side effects and lack of definitive advice during infancy. We present a 1-day-old neonate with COVID-19 based on the, laboratory and radiological findings.

We only had supportive therapies, and the disease had a good clinical course, and there was no serious complication in the treatment process with supportive measures.

## Ethics approval

This case report has been described in accordance with the ethical standards laid down in the “Declaration of Helsinki of 1964”.

## Consent for publication

Written informed consent was obtained from parents for the publication of this case report.

## Authors' contributions

AB, MK, FR, and RJ drafted, designed and wrote the original draft.

## Declarations

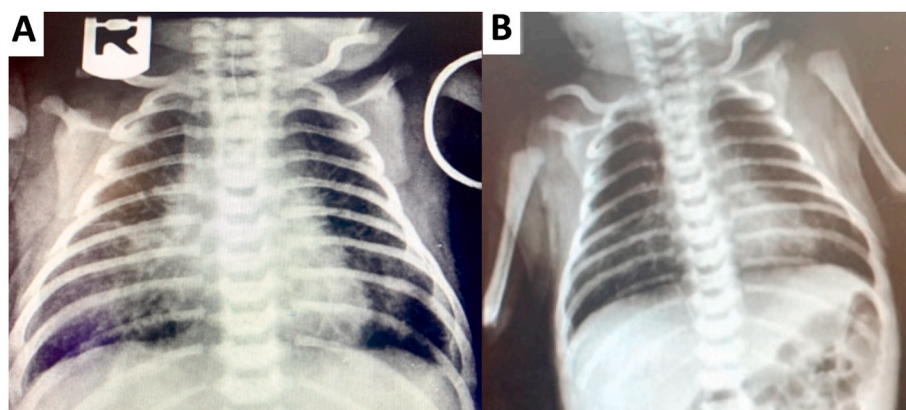
Travel Medicine and Infectious Disease requires that all authors sign a declaration of conflicting interests. If you have nothing to declare in any of these categories then this should be stated.

<https://doi.org/10.1016/j.tmaid.2020.101879>

Received 17 May 2020; Received in revised form 21 August 2020; Accepted 14 September 2020

Available online 17 September 2020

1477-8939/© 2020 Published by Elsevier Ltd.



**Fig. 1.** Two portable AP chest x rays from neonate at day one(A) show patchy reticular and ground glass infiltration at lower zone of both lungs (more prominent at right paracardiac area) with significant resolution of opacities at day four (B).

### Funding source

None.

### Declaration of competing interest

None.

### Acknowledgments

The authors would like to thank the Shahid Akbarabadi Clinical Research Development Unit (SHACRDU), Iran University of Medical Sciences (IUMS), Tehran, Iran (Ethical code NO: IR.IUMS.REC.1399.369).

### References

- [1] Choi K, Records K, Low LK, et al. Promotion of maternal-infant mental health and trauma-informed care during the coronavirus disease 2019 pandemic. *J Obstet Gynecol Neonatal Nurs* : J Obstet Gynecol Neonatal Nurs 2020 Aug. <https://doi.org/10.1016/j.jogn.2020.07.004>.
- [2] Chi H, Chiu NC, Tai YL, Chang HY, Lin CH, Sung YH, Tseng CY, Yu-Min Liu L, Lin CY. Clinical features of neonates born to mothers with coronavirus disease-2019: a systematic review of 105 neonates. *J Microbiol Immunol Infect* 2020. <https://doi.org/10.1016/j.jmii.2020.07.024>. Available online 14 August.
- [3] Dubey P, Reddy SY, Manuel S, Dwivedi AK. Maternal and neonatal characteristics and outcomes among COVID-19 infected women: an updated systematic review and meta-analysis. *Eur J Obstet Gynecol Reprod Biol* 2020 Jul;252:490–501.
- [4] Jafari R, Cegolon L, Torkaman M, et al. A 6 months old infant with fever, dyspnea and poor feeding, diagnosed with COVID-19. *Trav Med Infect Dis* 2020 Jun:101789.

Arash Bordbar, Mandana Kashaki\*, Fatemeh Rezaei  
Shahid Akbarabadi Clinical Research Development Unit (ShACRDU), Iran  
University of Medical Sciences (IUMS), Tehran, Iran

Ramezan Jafari  
Department of Radiology, Baqiyatallah University of Medical Sciences,  
Tehran, Iran

\* Corresponding author.

E-mail addresses: [mandanakashaki@gmail.com](mailto:mandanakashaki@gmail.com), [kashaki.m@iums.ac.ir](mailto:kashaki.m@iums.ac.ir)  
(M. Kashaki).