

Original Article

Best Parameter for the Evaluation of Right Ventricular Function by 2D Echocardiography in Patients With Corrected Tetralogy of Fallot

Niloufar Samiei¹, MD; Mohammad Kasaei², MD; Mahmood Salehi³, PHD;
Mohammad Reza Eftekhari^{2*}, MD

ABSTRACT

Background: Echocardiography has a widespread role in measuring cardiac function and hemodynamics. Nevertheless, the evaluation of right ventricular (RV) function is a puzzle, especially by 2D echocardiography, because of the complex anatomy of this chamber. Tetralogy of Fallot (ToF) is the most common cyanotic congenital heart disease, and an accurate evaluation of RV function is important for planning the time for pulmonary valve surgery after initial correcting surgery. Although cardiovascular magnetic resonance imaging (CMR) is the gold standard tool for measuring the right ventricular ejection fraction (RVEF), we sought to determine which classic factor for the evaluation of RV function by 2D echocardiography matched relevant CMR findings the most.

Methods: All patients (N = 26) with corrected ToF referred for CMR in Rajaie Cardiovascular Medical and Research Center between June 2018 and January 2019 were evaluated by 2D echocardiography. The findings relating to RV function by the 2 methods were analyzed using the SPSS software, version 22.

Results: Of the 4 classic parameters for the evaluation of RV function by 2D echocardiography, only fractional area change had a statistically significant correlation with RVEF by CMR (AUC for the evaluation of RVEF \geq 45%: 0.813, $P = 0.012$; the Spearman correlation coefficient: 0.40, $P = 0.04$). Additionally, tricuspid annular plane systolic excursion, S', and the RV index of myocardial performance could not predict RVEF in our patients with corrected ToF.

Conclusions: Fractional area change is a suitable parameter for the evaluation of RVEF in patients with ToF; nonetheless, the other classic parameters of RV function in 2D echocardiography cannot predict RV function in these patients. (*Iranian Heart Journal 2020; 21(3): 40-47*)

KEYWORDS: Right ventricular function, Tetralogy of Fallot, 2D echocardiography

¹Echocardiography Research Center, Rajaie Cardiovascular Medical and Research Center, Iran University of Medical Sciences, Tehran, IR Iran.

²Rajaie Cardiovascular Medical and Research Center, Iran University of Medical Science, Tehran, IR Iran.

³Chemical Injuries Research Center, Systems Biology and Poisonings Institute, Baqiyatallah University of Medical Sciences, Tehran, IR Iran.

*Corresponding Author: Mohammad Reza Eftekhari, MS; Rajaie Cardiovascular Medical and Research Center, Iran University of Medical Science, Tehran, IR Iran.

Email: dr.m.r.eftekhari@gmail.com

Received: June 1, 2019

Accepted: July 10, 2019

Tetralogy of Fallot (ToF) is the most common malformation in patients with cyanotic congenital heart disease (CHD).¹ It is estimated to have an incidence of 3.5% in infants with CHD and about 5% to 6% of all patients with CHD.² The surgical repair of ToF has been available for about 50 years, with a favorable outcome in most patients. Nonetheless, nowadays, we encounter an increasing number of patients who require regular follow-ups after the initial correction of ToF. Amongst the complications after the surgical repair of ToF, pulmonary regurgitation is the most common and unfortunately, it progressively leads to significant right ventricular (RV) dilation and dysfunction.¹ RV dysfunction also affects left ventricular (LV) systolic function, and both RV and LV dysfunction are indicators of the clinical outcome.³ Therefore, assessment of ventricular function is of paramount importance in the follow-up of this patient population.⁴ In such patients, pulmonary valve replacement resolves pulmonary regurgitation and improves RV size and function.¹ The assessment of RV function by echocardiography in patients with ToF is challenging and is currently largely qualitative⁴ and because of the complex anatomy of the RV, 2D echocardiography cannot estimate RV size and function well.⁵ Amongst the methods for assessing RV function, cardiovascular magnetic resonance imaging (CMR) is considered the reference technique because it does not require any geometrical assumptions. However, CMR is expensive and is not as widespread. Additionally, a more delicate depiction of RV function by 2D echocardiography reduces ineffectual CMR prescriptions.¹ According to the last version of adult CHD guidelines,⁶ one of the indications for pulmonary valve replacement in patients with corrected ToF is a maximum right

ventricular ejection fraction (RVEF) of 45%. Then detection of this category of patients is critical.

In the current study, we aimed to evaluate RV function in patients with corrected ToF in terms of the 4 classic parameters of RV function—namely, tricuspid annular plane systolic excursion (TAPSE), S', fractional area change (FAC), and the right ventricular index of myocardial performance (RIMP)—and compare them with RVEF derived from CMR with a view to determining which of the classic RV function parameters by 2D echocardiography matched CMR findings the most.

METHODS

Data Collection

All patients with corrected ToF referred to the CMR Ward in Rajaie Cardiovascular Medical and Research Center were included in this study. For a better evaluation of RV anatomy and function in the axial view, this image was recorded for all the patients during the CMR study. Just after CMR (on the same day), all the patients were referred to the echocardiography ward for complete 2D transthoracic echocardiography by a single experienced fellow of echocardiography. Echocardiograms were performed with Philips Epiq 7 and GE S60 machines. In all the patients, the 4 classic echocardiographic parameters of RV function (ie, TAPSE, S', FAC, and RIMP) were measured, and all the measurements were performed in the 4-chamber view (Table 1).⁷

All the CMR views were studied by a single experienced operator, blinded to the echocardiographic finding.

Ultimately, 26 patients were included in this study between June 2018 and January 2019.

Data Analysis

The data analyses were conducted using analytical and descriptive statistics with the

SPSS software, version 22. The correlations between RVEF by CMR and the 4 echocardiographic parameters (ie, FAC, S', TAPSE, and RIMP) were analyzed with the Spearman nonparametric rank correlation coefficient. Descriptive studies were performed using the receiver operating

characteristic (ROC) curve for the evaluation of the accuracy of each echocardiographic parameter for the prediction of an RVEF of less than 45%. The significance level was defined as a *P* value of lower than 0.05.

Table 1: Definition and normal values for the parameters of RV function

Parameter	Definition	Mean ± SD	Abnormality Threshold
TAPSE (mm)	Distance of lateral tricuspid annular movement between end-diastole to end-systole measured by M-mode echocardiography	24±3.5	<17
Pulsed Doppler S' wave (cm/sec)	Velocity of the movement of the lateral tricuspid annulus measured by TDI	14.1±2.3	<9.5
RV fractional area change (FAC) (%)	Difference between the RV end-diastolic and end-systolic areas divided by the RV end-diastolic area	49±7	<35
Tissue Doppler MPI (RIMP or Tei index)	By TDI study at the lateral wall of the RV measured as (IVCT + IVRT) / ET	0.38±0.08	>0.54

RV, Right ventricle; TAPSE, Tricuspid annular plane systolic excursion; FAC, Fractional area change; RIMP, Right ventricular index of myocardial performance; TDI, Tissue Doppler imaging; IVCT, Isovolumic contraction time; IVRT, Isovolumetric relaxation time; MPI, Myocardial performance index; ET, Ejection time

Table 2: Study patients' characteristics, as well as their CMR and echocardiographic findings

	Parameter	Unit	Range	Mean±SD
Demographic Data	Age	y	6-35	19.4±8.5
	BSA	m ²	0.64-2.09	1.48±0.32
	female/male ratio		15(57.7%) /11(42.3%) 1.36	
CMR Findings	RVEF	%	17-57	47.1±8.5
	RVEDV	cm ³	82-323	213±66
	RVEDV index	cm ³ /m ²	78-213	144.4±32.6
Echocardiographic Findings	FAC	%	22.3-56.4	40±8.7
	S'	cm/s	6-15	9.1±2.0
	TAPSE	mm	10-20	14.5±3.1
	RIMP		0.31-1.29	0.78±0.25

CMR, cardiovascular magnetic resonance imaging; BSA, Body surface area; RVEDV, Right ventricular end-diastolic volume; TAPSE, Tricuspid annular plane systolic excursion; RIMP, Right ventricular index of myocardial performance; FAC, Fractional area change

Table 3: Study patients' echocardiographic data

	EF<45%	EF≥45%	P value
N	8	18	
Age (y)	22.3±8.8	18.1±8.3	0.18 ^φ
Sex ratio (female/male)	1	1.57	0.59 ^α
RVEDV (cm ³)	253±51	196±66	0.04 ^φ
RVEDV index (cm ³ /m ²)	162.5±32.6	136.4±30.1	0.12 ^φ
FAC	33.7±5.8	42.8±8.4	0.01 ^φ
S	8.8±3.1	9.3±1.5	0.38 ^φ
TAPSE	15.6±4.1	14.1±2.5	0.32 ^φ
RIMP	0.81±0.34	0.77±0.22	0.69 ^φ

^φ Mann-Whitney test

^α χ^2 test

P<0.05 is statistically significant.

EF, Ejection fraction; RVEDV, Right ventricular end-diastolic volume; TAPSE, Tricuspid annular plane systolic excursion; RIMP, Right ventricular index of myocardial performance; FAC, Fractional area change

Table 4: Correlation between RVEF and echocardiographic parameters via the Spearman rho method

	FAC	S'	TAPSE	RIMP
Correlation Coefficient	0.403	0.369	-0.160	0.056
Sig. (2-tailed)	0.041	0.063	0.434	0.785
N	26	26	26	26

RVEF, Right ventricular ejection fraction; TAPSE, Tricuspid annular plane systolic excursion; RIMP, Right ventricular index of myocardial performance; FAC, Fractional area change

RESULTS

In the present study, 26 patients with corrected ToF were evaluated. The patients' age was between 6 and 35 years (19.6 ± 8.5 y). The majority of the patients were female (57.7%) (Table 2). Totally, 53.8% of the echocardiograms were performed with a Philips machine, and others were done with a GE machine.

RVEF distribution was between 17% and 57% with a mean RVEF of 47%. Eight (30.7%) patients had an RVEF of less than 45% (group 1), and the other 18 (69.3%) patients were in the range of 45% or more (group 2). The mean age of group 1 was higher than that of group 2 (22.3 ± 8.8 y vs 18.1 ± 8.3 y, respectively), but the difference was not significant (*P* = 0.18). The mean RV end-diastolic volume was significantly larger in group 1 than in group 2 (253 ± 51 cc vs 196 ± 66 cc; *P* = 0.04). No significant difference vis-à-vis sex was detected between the 2 groups (*P* = 0.59) (Table 3).

For the detection of the relationship between CMR RVEF and echocardiographic parameters, 2 methods were utilized. First, the direct relationship between each parameter and CMR RVEF was evaluated. Because the distribution of RVEF was not normal, a nonparametric Spearman analysis was carried out. According to Table 4, only FAC had a significant relationship with RVEF (*R* = 0.40, *P* = 0.04) and S' had a borderline relationship (*R* = 0.36, *P* = 0.06). This relationship was less and nonsignificant for the other parameters (ie, TAPSE and RIMP). Second, the accuracy of each parameter for the prediction of patients with an RVEF of less than 45% was measured. According to the ROC curve, only FAC predicted an RVEF of below 45% in our patients with ToF with a statistically significant power (area under the receiver operating characteristic curve [AUC]: 0.81, *P* = 0.01) (Fig. 1). At the cut point of 0.42, FAC had a sensitivity of 100%, a specificity

of 55%, and an accuracy of 69%. All the other AUCs were less with nonsignificant P values.

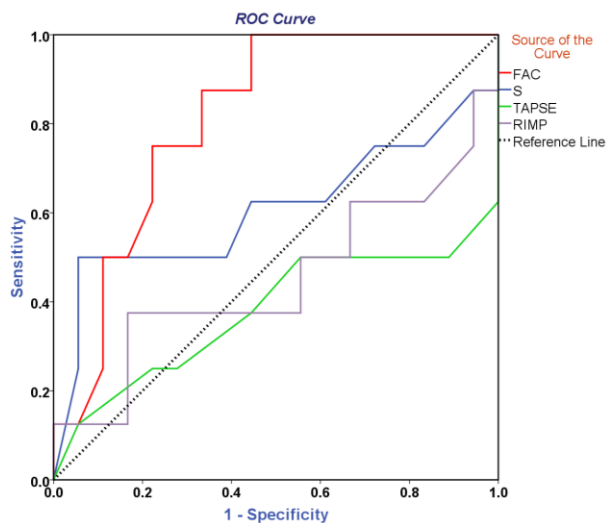


Figure 1: According to the receiver operating characteristic (ROC) curve, only fractional area change (FAC) predicted right ventricular ejection fraction (RVEF) of below 45% in our patients with tetralogy of Fallot with a statistically significant power (area under the receiver operating characteristic curve [AUC]: 0.81, $P = 0.01$).

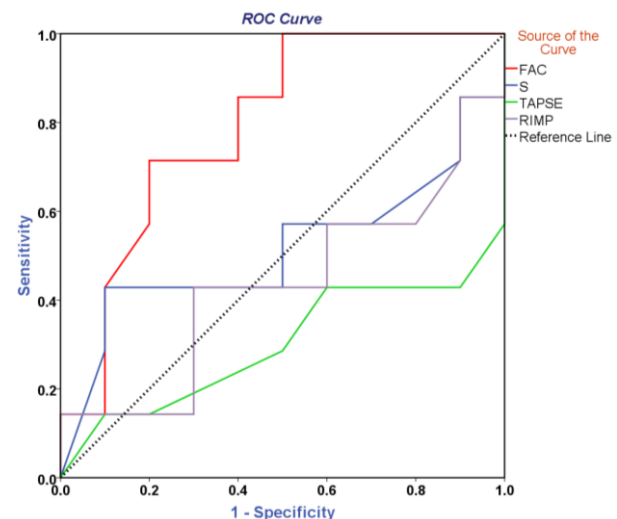
Test Result Variable(s)	Area Under the Curve (AUC)	P value
FAC	0.813	0.012
S'	0.608	0.389
TAPSE	0.378	0.331
RIMP	0.451	0.697

The power of the 4 classic parameters for the prediction of an RVEF<45% in all the patients with tetralogy of Fallot

FAC, Fractional area change; TAPSE, Tricuspid annular plane systolic excursion; RIMP, Right ventricular index

At this point, the question was whether these parameters could predict RVEF in patients with significantly enlarged RVs with the same power as they predicted RVEF in patients with small RVs. Thus, only patients with ToF who had an RV end-diastolic volume index of more than 130 cc/m² were chosen, and again statistical measurements were done for this group (Fig. 2). The results revealed no significant change in the power

of FAC for the prediction of an RVEF of less than 45% (AUC: 0.79, $P = 0.04$). Still, in this group of patients, S' could not predict RVEF at all (AUC: 0.51, $P = 0.92$).



Test Result Variable(s)	Area Under the Curve (AUC)	P value
FAC	0.793	0.045
S	0.514	0.922
TAPSE	0.300	0.172
RIMP	0.436	0.661

Figure 2: The power of the 4 classic parameters for the prediction of an RVEF<45% in the patients with tetralogy of Fallot and severe RV enlargement

FAC, Fractional area change; TAPSE, Tricuspid annular plane systolic excursion; RIMP, Right ventricular index

DISCUSSION

One of the challenges in 2D echocardiography is to determine the size and function of the RV. Indeed, despite all the advances in 2D echocardiography, considerable success has yet to be achieved in this regard. This is due to the complex anatomy of the RV insofar as this chamber, in contrast to the LV, does not have a symmetric and geometric structure. Fortunately, the evolution of 3D echocardiography has partly overcome this

problem. Nevertheless, the point is that most centers in the world do not have access to 3D echocardiography, not to mention the cost and the time it requires for special training.

Among the diseases that lead to RV involvement and, indeed, determine its size and function is CHD. The most common cyanotic heart disease is ToF. The Recommendations for Cardiac Chamber Quantification by Echocardiography in 2015⁷ posited numbers as cut points for the 4 main parameters of RV function (Table 1). Be that as it may, what can be seen in the clinic is the incomplete correspondence between these numbers and RV function, especially when the structure of the RV changes. The salient point is that the RV in various diseases that lead to its involvement is not homogeneously enlarged and the deformation manner in each disease is different from that of another disease.⁸ Hence, it might be impossible to apply the same criteria for the assessment of RV function in all diseases. According to our results, in patients with ToF, only FAC was able to predict RV function to an approximately acceptable level and the other parameters failed to exhibit high accuracy in this field. Egbe et al¹⁴ also considered an acceptable value for FAC in the evaluation of RV function in patients with ToF; nonetheless, the value of S' and TAPSE in their study was also remarkable. Mercer-Rosa et al^{4,9} demonstrated that the role of TAPSE in assessing RV function in patients with ToF was insignificant. In their 2 studies, the authors examined the correlation between RIMP and RVEF in patients with ToF and found a negative correlation between RIMP and RVEF in both studies.

The results of a study conducted by Ishizu et al¹⁵ on patients (50% with CHD) who underwent CMR are more consistent with our results inasmuch as of the 3 parameters of FAC, S', and TAPSE, only FAC had a significant relationship with RV systolic function (Table 5).

Given the contradictory results of various studies on the parameters of TAPSE, S', and RIMP, it appears that these 3 indicators cannot be used as the main criteria for the measurement of RV systolic function by 2D echocardiography. One of the great limitations of TAPSE and S' in the evaluation of RV function is that they consider the displacement (velocity) of only 1 point of the RV free wall as a criterion for the assessment of the whole RV function while they completely ignore the functions of its septum and outflow tract. Moreover, a great percentage of patients with ToF have severe pulmonary insufficiency. An increased RV end-diastolic volume secondary to pulmonary insufficiency may increase the ejection time across the pulmonary valve and reduce the isovolumic relaxation time, thereby lowering the myocardial performance index despite RV dysfunction.⁹

In contrast, FAC has a better correlation with RV function in patients with ToF, which corresponds with the results in other articles. One of the most important indications for surgery in patients with ToF who have significant pulmonary insufficiency is an RVEF of below 45%. Based on our results, the cut point of 42% for FAC can predict an RVEF of less than 45% with a sensitivity of 100%. A FAC value of less than 42% means that the patient urgently needs valve replacement.

CONCLUSIONS

Due to the complex anatomy of the RV and the variety of its remodeling in various diseases, a precise evaluation of RV function is more complex than that of LV. In ToF, the exact determination of RVEF is of great significance concerning decision-making for pulmonary valve replacement. It appears that in 2D echocardiography, FAC is the best indicator for the evaluation of RV function of the 4 classic indicators in patients with ToF.

Table 5: Relationships between FAC, S', and TAPSE and RV systolic function

	Year	Number of Patients	FAC	S'	TAPSE	RIMP	RV Free Wall Strain	3D
[10]	2007	57 ToF				R= -0.73 P<0.001		
[1]	2009	20 ToF + 40 healthy						R=0.73 (All)
[2]	2011	131 ToF + 252 healthy			R=0.47 P<0.0001 (only ToF)			
[11]	2011	30 ToF						R=0.94 P=0.03
[9]	2012	143 ToF				R= -0.33 P<0.001		
[12]	2012	156 ToF			R=0.65 P<0.001			
[13]	2012	183 ToF		R=0.66 P<0.001				
[4]	2013	125 ToF			R=0.02 P=0.77 AUC=0.57 (prediction of RVEF<50%)			
[3]	2015	94 ToF + 85 healthy					R= -0.11 P=0.48 (only ToF)	
[14]	2019	219 ToF	R= 0.66 P < 0.001 AUC= 0.71 (prediction of RVEF<47%)	R= 0.71 P<0.001 AUC=0.79 (prediction of RVEF<47%)	R=0.79 P<0.001 AUC=0.80 (prediction of RVEF<47%)			
[15]	2017	75 patients referred for CMR	R=0.34 P=0.003 AUC=0.69 P=0.01 (prediction of RVEF<30%)	R=0.06 P=0.75 AUC= 0.57 P=0.48 (prediction of RVEF<30%)	R=0.02 P=0.85 AUC=0.51 P=0.78 (prediction of RVEF<30%)		R=0.19 P=0.07 AUC=0.64 P=0.06 (prediction of RVEF<30%)	R=0.84 P<0.001

RV, Right ventricle; ToF, Tetralogy of Fallot; FAC, Fractional area change; AUC, Area under the curve; RVEF, Right ventricular ejection fraction; TAPSE, Tricuspid annular plane systolic excursion; RIMP, Right ventricular index of myocardial performance; CMR, Cardiovascular magnetic resonance imaging

Limitations

The major limitation of the present study is its low volume of patients, the most important reason for which is the inherent weakness in single-center studies. Further research on the deformity parameters of the RV such as strain and the strain rate, which were not a part of this study, could confer a more accurate evaluation of RV systolic function by 2D echocardiography.

REFERENCES

- Iriart X, Montaudon M, Lafitte S, Chabaneix J, Réant P, Balbach T, et al., Right ventricle three-dimensional echography in corrected tetralogy of Fallot: accuracy and variability. *European Journal of Echocardiography*, 2009. 10(6): p. 784-792.
- Koestenberger M, Nagel B, Ravekes W, Everett AD, Stueger HP, Heinzl B, et al., Systolic right ventricular function in pediatric and adolescent patients with tetralogy of Fallot: echocardiography versus

- magnetic resonance imaging. *Journal of the American Society of Echocardiography*, 2011. 24(1): p. 45-52.
3. Menting ME, van den Bosch AE, McGhie JS, Eindhoven JA, Cuypers JA, Witsenburg M, et al., Assessment of ventricular function in adults with repaired Tetralogy of Fallot using myocardial deformation imaging. *European Heart Journal-Cardiovascular Imaging*, 2015. 16(12): p. 1347-1357.
 4. Mercer-Rosa L, Parnell A, Forfia PR, Yang W, Goldmuntz E, Kawut SM, et al., Tricuspid annular plane systolic excursion in the assessment of right ventricular function in children and adolescents after repair of tetralogy of Fallot. *J Am Soc Echocardiogr*, 2013. 26(11): p. 1322-9.
 5. van der Hulst AE, Roest AA, Holman ER, de Roos A, Blom NA, Bax JJ, et al., Real-time three-dimensional echocardiography: segmental analysis of the right ventricle in patients with repaired tetralogy of Fallot. *Journal of the American Society of Echocardiography*, 2011. 24(11): p. 1183-1190.
 6. Stout KK, Daniels CJ, Aboulhosn JA, Bozkurt B, Broberg CS, Colman JM, et al., 2018 AHA/ACC Guideline for the Management of Adults With Congenital Heart Disease: A Report of the American College of Cardiology/American Heart Association Task Force on Clinical Practice Guidelines. *Circulation*, 2019. 139(14): p. e698-e800.
 7. Lang RM, Badano LP, Mor-Avi V, Afilalo J, Armstrong A, Ernande L, et al., Recommendations for cardiac chamber quantification by echocardiography in adults: an update from the American Society of Echocardiography and the European Association of Cardiovascular Imaging. *Eur Heart J Cardiovasc Imaging*, 2015. 16(3): p. 233-70.
 8. Addetia K, Maffessanti F, Muraru D, Singh A, Surkova E, Mor-Avi V, et al., Morphologic Analysis of the Normal Right Ventricle Using Three-Dimensional Echocardiography-Derived Curvature Indices. *J Am Soc Echocardiogr*, 2018. 31(5): p. 614-623.
 9. Mercer-Rosa L, Yang W, Kutty S, Rychik J, Fogel M, Goldmuntz E, et al., Quantifying pulmonary regurgitation and right ventricular function in surgically repaired tetralogy of Fallot: a comparative analysis of echocardiography and magnetic resonance imaging. *Circulation: Cardiovascular Imaging*, 2012. 5(5): p. 637-643.
 10. Schwerzmann M, Samman AM, Salehian O, Holm J, Provost Y, Webb GD, et al., Comparison of echocardiographic and cardiac magnetic resonance imaging for assessing right ventricular function in adults with repaired tetralogy of fallot. *Am J Cardiol*, 2007. 99(11): p. 1593-7.
 11. Dragulescu A, Grosse-Wortmann L, Fackoury C, Riffle S, Waiss M, Jaeggi E, et al., Echocardiographic assessment of right ventricular volumes after surgical repair of tetralogy of Fallot: clinical validation of a new echocardiographic method. *Journal of the American Society of Echocardiography*, 2011. 24(11): p. 1191-1198.
 12. Koestenberger M, Nagel B, Avian A, Ravekes W, Sorantin E, Cvirn G, et al., Systolic right ventricular function in children and young adults with pulmonary artery hypertension secondary to congenital heart disease and tetralogy of Fallot: tricuspid annular plane systolic excursion (TAPSE) and magnetic resonance imaging data. *Congenit Heart Dis*, 2012. 7(3): p. 250-8.
 13. Koestenberger M, Nagel B, Ravekes W, Avian A, Heinzl B, Fandl A, et al., Tricuspid annular peak systolic velocity (S') in children and young adults with pulmonary artery hypertension secondary to congenital heart diseases, and in those with repaired tetralogy of Fallot: echocardiography and MRI data. *J Am Soc Echocardiogr*, 2012. 25(10): p. 1041-9.
 14. Egbe AC, Pislaru SV, Kothapalli S, Jadav R, Masood M, Angirekula M, et al., The role of echocardiography for quantitative assessment of right ventricular size and function in adults with repaired tetralogy of Fallot. *Congenit Heart Dis*, 2019.
 15. Ishizu T, Seo Y, Atsumi A, Tanaka YO, Yamamoto M, Machino-Ohtsuka T, et al., Global and Regional Right Ventricular Function Assessed by Novel Three-Dimensional Speckle-Tracking Echocardiography. *J Am Soc Echocardiogr*, 2017. 30(12): p. 1203-1213.