


The Effect of *Descurainia Sophia* Seed Extract on Nephrotoxicity Markers Induced by Acetaminophen in Mice

Pedram Moshai-Nezhad¹ , Zahra Bahari² , Zohreh Jangravi³ ,
Seyed Mohammad Zarei⁴ , Maryam Iman^{1,5*} 

1. Chemical Injuries Research Center, Systems Biology and Poisonings Institute, Baqiyatallah University of Medical Sciences, Tehran, Iran
2. Dept. of Physiology and Medical Physics, Faculty of Medicine, Baqiyatallah University of Medical Sciences, Tehran, Iran
3. Dept. of Biochemistry, Faculty of Medicine, Baqiyatallah University of Medical Sciences, Tehran, Iran
4. Dept. of Pharmacognosy, Faculty of Pharmacy, Baqiyatallah University of Medical Sciences, Tehran, Iran
5. Dept. of Pharmaceutics, Faculty of Pharmacy, Baqiyatallah University of Medical Sciences, Tehran, Iran

Article Info

 10.30699/jambs.29.134.139

Received: 2020/08/04;
Accepted: 2020/10/21;
Published Online: 30 Dec 2020;

Use your device to scan and read the article online



Corresponding Information:

Maryam Iman,

Dept. of Pharmaceutics, Faculty of Pharmacy, Baqiyatallah University of Medical Sciences, Tehran, Iran

E-Mail: iman1359@yahoo.com

ABSTRACT

Background & Objective: Acetaminophen is known as the most common agent which causes hepatic and renal toxicity in human and experimental animals at supra-therapeutic doses. The current study investigated the protective effects of *Descurainia sophia* seed extract on the acetaminophen-induced nephrotoxicity markers in male mice.

Materials & Methods: Experimental male mice (n=60, Swiss albino mice) were divided into six groups as follows: Group A (control group), Group B (acetaminophen group), and treatment groups including T1, T2, T3, and T4 (*D. sophia* seed extract groups). Toxicity was induced by acetaminophen (500 mg/kg). The mice administered *D. sophia* seed extract for 7 days in doses of 50, 100, 200, and 300 mg/kg. In the next step, animals were euthanized 24 hours after acetaminophen administration. Blood samples were collected. Serum levels of blood urea nitrogen (BUN), creatinine, and uric acid were analysed. Furthermore, kidney tissues were removed for histopathological examination via haematoxylin and eosin staining.

Results: Our data revealed that acetaminophen increased the levels of BUN, creatinine and uric acid ($P < 0.05$). Pre-treatment of *D. sophia* seed extract decreased the serum BUN, creatinine and uric acid significantly compared to the acetaminophen group ($P < 0.05$). Additionally, in histopathological examination, *D. sophia* extract had restored acetaminophen-induced nephrotoxicity, particularly in the dose of 300 mg/kg.

Conclusion: The present findings suggested that oral administration of *D. sophia* seed extract has protective effect against acetaminophen nephrotoxicity in mice.

Keywords: Acetaminophen, BUN, Creatinine, *Descurainia sophia* seed, Mice, Nephrotoxicity



Copyright © 2021, This is an original open-access article distributed under the terms of the Creative Commons Attribution-noncommercial 4.0 International License which permits copy and redistribution of the material just in noncommercial usages with proper citation.

Introduction

Acetaminophen (N-acetyl-p-aminophenol, APAP) is one of the most popular and widely used analgesic and anti-fever agents in both children and adults (1). However, APAP is safe and effective when is administered at therapeutic doses. However, in high doses, it can lead to hepatotoxicity and nephrotoxicity (1). It is well accepted that the majority of APAP molecules convert to inactive conjugate forms (glucuronidation and sulfation), which are described as detoxification pathway. However, minor fraction of APAP which undergoes cytochrome P450 oxidation converts to a toxic metabolite, N-acetyl-p-benzoquinone

imine (NAPQI). It can react with glutathione (GSH) and produces harmless metabolites (2).

At supra-therapeutic doses of APAP (more than 4 g/day), detoxification pathways are saturated, due to glucuronidation and sulfation insufficiency. At supra-therapeutic doses, APAP undergoes oxidation by cytochrome P450, which causes GSH depletion. It promotes toxic free NAPQI binding to various cellular proteins which leads to aggravation of cellular oxidative stress and cellular necrosis (2, 3). APAP-induced hepatotoxicity has been studied widely, but APAP-induced nephrotoxicity has not been clearly understood. Since APAP can induce hepatotoxicity and

nephrotoxicity, it seems logical to find an agent to neutralize the toxic effects (4). *Descurainia sophia*, a member of Brassicaceae family, is a popular traditional medicine, which grows in various regions of Asia and Europe (5, 6). Ample evidences reported various therapeutic effects of *D. sophia* on many health disorders, including asthma, cough, urinary system problems, pain, oedema, cardiac problems, constipation, fever, pruritus, intestinal worms (7, 8), and internal haemorrhage (9). Furthermore, it has been reported that *D. sophia* seeds are used to treat various pathological conditions such as gastrointestinal disorders, inflammation, asthma, and cardio-vascular problems (10, 11). It is also suggested for vitamin C deficiency treatment (5).

Limited number of studies have evaluated protective effects of this plant on body organs. For example, Moshai-Nezhad et al. reported that oral administration of *D. sophia* seed extract (dosage range 50-300 mg/kg, for seven days) improves oxidative stress markers and liver toxicity in the paracetamol treated mice (12). Additionally, Luo et al. reported that *D. sophia* treatment for three months, improves cardiac fibrosis and apoptosis in rats as compared to sham group (13). They also claimed that protective effects of *D. sophia* on cardiac function may be mediated by activation of PI3k/Akt/mTOR signalling pathway (13). Similarly, Wei-sheng et al. showed that H9c2 cell exposure to *D. sophia*, increases the survival rate of H9c2 and mitochondrial membrane potential. They also observed that *D. sophia* treatment decreases apoptosis rate and ROS level in doxorubicin-induced cardio myocyte injury, significantly (14).

So far, no study has been done on the protective effects of *D. sophia* on kidney. Therefore, the aim of the current research was to assess protective effects of *D. sophia* seed extract on acetaminophen-induced nephrotoxicity markers. For this purpose, we evaluated the effects of oral administration of *D. sophia* on BUN, creatinine, and uric acid in blood samples of mice. Furthermore, we examined the protective effects of *D. sophia* on acetaminophen-induced nephrotoxicity via histopathological study of kidney tissue.

Materials and Methods

Animals

In the current study, healthy adult male mice (Swiss albino) were purchased from Pasteur Institute (Iran, Tehran). The animals were kept in Plexiglas cages at room temperature ($23\pm 2^{\circ}\text{C}$) having a 12-hour light/dark cycle, as well as free access to standard pellet diet and water. The animals acclimatized to the environment for one week before starting the experiments. The present study is approved by the ethic committee of Baqiyatallah University of Medical Sciences, Tehran, Iran (Ethical code: IR.BMSU.REC.1396.464).

Plant Material and Extraction

A sample of prepared seeds was rendered to the Herbarium of the Faculty of Pharmacy, Isfahan University of Medical Sciences, Isfahan, Iran. It got a Voucher number (2834).

Using a homemade grinder, the dried seeds were pulverized into fine powder. Then, ethyl alcohol 96% (22 g/21 ml of ethyl alcohol) was added to powdered seed. Subsequently, samples were shaken for 24 hours at room temperature using a shaker. Using a rotary device, the alcohol was extracted and so the extract was condensed. It was incubated in an oven for 22 hours at 61°C to dry (15).

Experimental Protocol

In the current study, the animals were divided into six groups, randomly ($n=6$ in each group). The groups were labelled as follows: A, B, T1, T2, T3, and T4. Group A members were considered as control and the animals received normal saline solution (200 mg/kg) for seven days, orally. Group B were considered as acetaminophen group. The animals received acetaminophen solution in water (intraperitoneal, 500 mg/kg) on the eighth day of the experiment. T1, T2, T3 and T4 groups were treatment groups. The animals were orally treated with seed extract every 12 hours with different dosages (50, 100, 200 and 300 mg/kg), for seven days.

Fresh *D. sophia* seed extract was dissolved in normal saline 0.9% before the administration. The doses and duration of treatment were based on previous studies (6, 16, 17). The animals were euthanized 24 hours after acetaminophen administration, and their blood samples were collected for analysis of BUN, creatinine and uric acid. Kidney tissues were removed and stored in 10% formalin for further histopathological examination via haematoxylin and eosin staining.

Measurement of Urea, Creatinine and Uric Acid Levels

Blood samples were taken from animals' hearts after 24 hours of acetaminophen injection. Using centrifuge apparatus, the serum samples separated at 3500 rpm for 10 minutes. Urea, Creatinine and Uric acid concentrations were measured by auto analyser machine with commercial reagent kits, according to provided procedure of the manufacturer (Pars Azmoon Kits).

Histopathological Assessment

For haematoxylin and eosin staining, the kidney tissues were fixed in phosphate buffered 10% for 48 hours and the paraffin blocks were prepared. The blocks were cut into sections ($5\ \mu\text{m}$), using a rotary microtome. The sections were stained with haematoxylin and eosin, then were visually checked under a light microscope. Finally, alterations of the histopathology parameters of kidney tissues were graded (18).

Statistical Analysis

All the data presented as mean \pm standard error of the mean (SEM). Analyses were performed using SPSS 22.0 (SPSS Inc., Chicago, IL., USA). Statistical analyses

were performed with one-way analyses of variance (ANOVAs) and Duncan's-test as a post-test. P-value \leq 0.05 was considered as statistically significant.

Results

BUN, Creatinine and Uric Acid Measurement

BUN, creatinine and uric acid levels showed a significant increase in acetaminophen group compared to the controls (P<0.05). Also, BUN and uric acid levels significantly decreased in T4, T3 and T2 groups after administration of *D. sophia* seed extract compared to the acetaminophen group. Moreover, there was no statistical differences between T4 and the control group. Similarly, there was no statistical differences in creatinine levels in the treatment groups.

Administration of *D. sophia* seed extract caused a significant decrease in T3 and T4 groups as compared with the acetaminophen group. The best treatment was observed in T4 group, (300 mg/kg) compared to the

control in terms of BUN, creatinine and uric acid levels (P>0.05) (Table 1).

Histologic Examination

In the histopathological study, the control group exhibited the normal architecture of kidneys (Figure 1.a). Our data identified inflammatory cell infiltration, congestion, vacuolar degeneration, as well as necrosis in the acetaminophen and T1 groups. Indeed, these alterations demonstrated effective renal damage (Figure 1.b).

T2 group was similar to T1 with less damage severity (Figure 1.c.d). In the T3 group, mild vacuolar degeneration and necrosis were seen (Figure 1.e). In the T4 group (300 mg/kg), we observed mild necrosis with minimal tissue damage (Figure 1.f). Histopathology parameters for kidney tissues were graded in Table 2.

Table 1. The effects of different doses of DS seed extract (50, 100, 200 and 300 mg/kg) on the serum levels of urea, uric acid and creatinine.

Groups	BUN(mg/dl)	Uric Acid(mg/dl)	Creatinine(mg/dl)
Control	20.40±1.98	7.40±.392	0.600±.057
Acetaminophen (500mg/kg)	50.40±3.64*	12.82±.703*	1.61±.111*
T1(50mg/kg)	46.30±3.314	11.97±.883	1.54±.093
T2(100mg/kg)	40.50±3.152 [#]	10.43±.553 [#]	1.41±.110
T3(200mg/kg)	32.10±1.728 [#]	9.01±.495 [#]	1.10±.148 [#]
T4(300mg/kg)	26.90±3.816 [#]	8.68±.504 [#]	0.928±.125 [#]

Nephrotoxicity was determined 24 h later by quantifying the BUN, uric acid and creatinine. Each value represents the mean \pm SD. Treatments groups: T1 (DS seed extract, 50 mg/kg), T2 (DS seed extract, 100 mg/kg), T3 (DS seed extract, 200 mg/kg) and T4 (DS seed extract, 300 mg/kg). The symbols * and # denote significant differences from control, and acetaminophen groups, respectively; *P-value<0.05, and #P-value<0.05.

Table 2. The effects of different doses of DS seed extract on the histopathologic changes following acetaminophen administration.

Group	Inflammatory cell infiltration	Congestion	Degeneration	Necrosis
Control	-	-	-	-
Acetaminophen	+	+	++	++
T1 (50mg/kg)	+	+	++	++
T2 (100mg/kg)	+	+	+	+
T3 (200mg/kg)	-	-	+	+
T4 (300mg/kg)	-	-	-	+

Histopathologic assessments of the experimental parameters following acetaminophen administration. Treatments groups: T1 (DS seed extract, 50 mg/kg), T2 (DS seed extract, 100 mg/kg), T3 (DS seed extract, 200 mg/kg) and T4 (DS seed extract, 300 mg/kg).

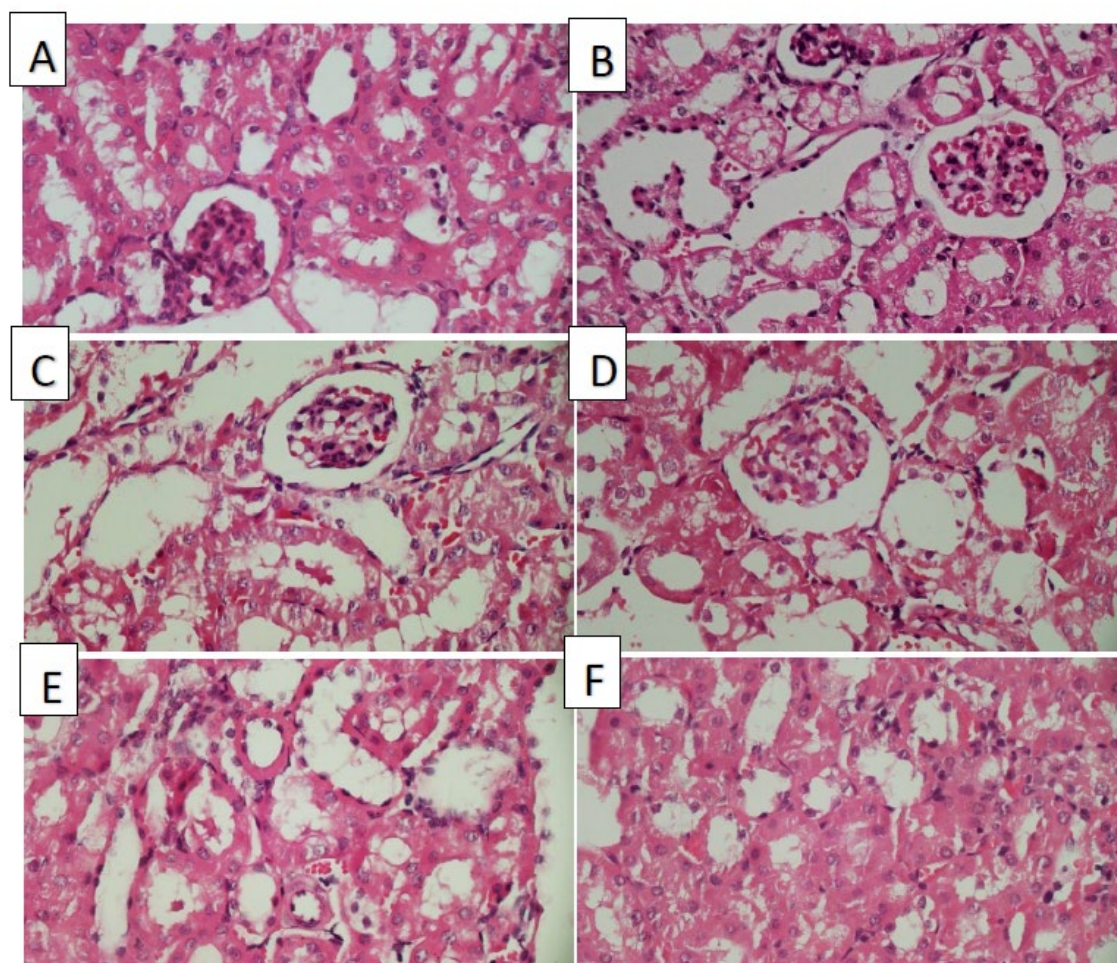


Figure 1. Histopathological alterations following acetaminophen administration in all experimental groups; A) Control, B) Acetaminophen, C) T1 (DS seed extract, 50 mg/kg), D) T2 (DS seed extract, 100 mg/kg), E) T3 (DS seed extract, 200 mg/kg) and F) T4 (DS seed extract, 300 mg/kg).

Discussion

The present study determined that acetaminophen administration at high doses results in a markedly increase of serum urea, creatinine, and uric acid concentration which can lead to nephrotoxicity. The Mechanism of acetaminophen-induced renal damage had been reported previously (19-23). Several documents have reported that acetaminophen can cause oxidative stress and renal toxicity at high doses, which was consistent with our findings.

The intensity of acetaminophen-induced renal damage is related to cytochrome P450 activity and glutathione deposits. In the kidney, cytochrome P450 enzyme is mainly found in proximal tubules. Also, there is a small amount in the glomerulus, distal and collecting ducts. Indeed, the highest amount of cytochrome P450 enzyme is located in the proximal tubules. The concentration of toxic metabolites in the proximal tubules is more than other segments of the nephrons, due to high absorption and secretion (2, 3).

The purpose of the current study was to investigate the effects of *D. sophia* seed extract on acetaminophen-induced nephrotoxicity. We observed that the application of *D. sophia* seed extract decreases acetaminophen caused damages. Furthermore, *D. sophia* treatment reduced the level of BUN, creatinine, and uric acid. Using metabolomics research, in 2017, Zhou et al. detached *D. sophia* seed extract into five fractions based on its polarity. They found that the fat oil fraction could reverse the abnormal metabolism and improve cardiac function (6). Sun et al. isolated a new sulphur glycoside structure of *D. sophia*, which is called descurainoside. They observed that *D. sophia* therapy can suppress cough, asthma, and oedema and also can increase urination, and cardiac function (5). In the present study, results of histopathological examination demonstrated clear evidence of renal damage and inflammation after high-dose acetaminophen administration in the acetaminophen group. Histopathology of kidneys confirmed that *D.*

sophia seed extract can attenuate kidney damage in the acetaminophen-treated mice. Furthermore, we observed that administration of *D. sophia* seed extract reduces cell inflammation, swelling, degeneration, and necrosis in the kidney. The present study is in line with our previous research, which showed that application of *D. sophia* seed extract decreases oxidative stress markers and also hepatotoxicity in paracetamol-treated animals, effectively (12).

There are not many studies about *D. sophia* side effects and complications. However, Lee et al. isolated 14 compounds (C1-C14) of *D. sophia* seeds, which were separated by chromatographic method. Among the 14 components, only C4 has cytotoxicity potent, ranging from 0.034 to 0.596 μ M against all human cancer cell lines. Hence, the C4 is identified as the main active cytotoxic constituent of *D. sophia* plant (24). Additionally, in a clinical trial study, Nabimeybodi et al. claimed that *D. sophia* treatment of patients with cervicitis do not cause any side effects or complications (25). The limitation of the present investigation was lack of studies on the therapeutic effects of *D. sophia* extract. Therefore, we could not find relevant clinical studies and systematic reviews to enrich our research.

Conclusion

In the light of histopathological and biochemical results, the present findings demonstrate the benefits of *D. sophia* seed extract for renal damages. It can markedly decrease the biomarkers of kidney damage and renal inflammation in acetaminophen-induced nephrotoxicity in mice. The most effective renal protection effects of extract was observed in the dose of 300 mg/kg.

Further studies and evidences are needed to establish the underlying mechanisms of nephron-protective activities of *D. sophia*.

Acknowledgments

Present study was supported by Islamic Azad University, Babol branch, Babol, Iran (IR.BMSU.REC.139.464).

Funding and support

This research resulted from an independent research without receiving any financial support.

Conflict of Interest

Authors declared no conflict of interest.

References

1. Deen J, von Seidlein L. Paracetamol for dengue fever: no benefit and potential harm? *The Lancet*. 2019; 7:552-53. [DOI:10.1016/S2214-109X(19)30157-3]
2. Mazer M, Perrone J. Acetaminophen-induced nephrotoxicity: pathophysiology, clinical manifestations, and management. *J Med Toxicol*. 2008; 4:2-6. [DOI:10.1007/BF03160941]
3. McGill MR, Williams CD, Xie Y, Ramachandran A, Jaeschke H. Acetaminophen-induced liver injury in rats and mice: comparison of protein adducts, mitochondrial dysfunction, and oxidative stress in the mechanism of toxicity. *Toxicol Applied Pharm*. 2012; 264:387-94. [DOI:10.1016/j.taap.2012.08.015]
4. Abdel-Zaher AO, Abdel-Hady RH, Mahmoud MM, Farrag MM. The potential protective role of alpha-lipoic acid against acetaminophen-induced hepatic and renal damage. *Toxicology*. 2008; 243:261-70. [DOI:10.1016/j.tox.2007.10.010]
5. Sun K, Li X, Liu J-M, Wang J-H, Li W, Sha Y. A novel sulphur glycoside from the seeds of *Descurainia sophia* (L.) Note. *J Asian Nat Prod Res*. 2005; 7:853-56. [DOI:10.1080/1028602042000204072]
6. Zhou N, Sun Y-P, Zheng X-K, Wang Q-H, Yang Y-Y, Bai Z-Y, et al. A Metabolomics-Based Strategy for the Mechanism Exploration of Traditional Chinese Medicine: *Descurainia sophia* Seeds Extract and Fractions as a Case Study. *Evid Based Complementary Altern Med*. 2017; 2017. [DOI:10.1155/2017/2845173]
7. Barnes J, Anderson LA, Phillipson JD. *Herbal medicines: a guide for healthcare professionals: pharmaceutical press*. 2003; 2003.
8. Nimrouzi M, Zarshenas MM. Phytochemical and pharmacological aspects of *Descurainia sophia* Webb ex Prantl: modern and traditional applications. *AJP*. 2016; 6:266.
9. Lee YJ, Kim NS, Kim H, Yi J-M, Oh S-M, Bang O-S, et al. Cytotoxic and anti-inflammatory constituents from the seeds of *Descurainia sophia*. *Arch Pharm Res*. 2013; 36:536-41. [DOI:10.1007/s12272-013-0066-x]
10. Mohamed NH, Mahrous AE. Chemical constituents of *Descurainia sophia* L. and its biological activity. *Rec Nat Prod*. 2009; 3:58.

11. Wang A, Wang X, Li J, Cui X. Isolation and structure identification of chemical constituents from the seeds of *Descurainia sophia* (L.) Webb ex Prantl. *Acta Pharm Sin.* 2004; 39:46-51.
12. Moshai-Nezhad P, Iman M, Faed Maleki F, Khamesipour A. Hepatoprotective effect of *Descurainia sophia* seed extract against paracetamol-induced oxidative stress and hepatic damage in mice. *J Herbmed Pharmacol.* 2018; 7(4):267-72. [DOI:10.15171/jhp.2018.40]
13. Luo Y, Sun Z, Hu P, Wu Y, Yu W, Huang S. Effect of aqueous extract from *descurainia sophia* (L.) webb ex prantl on ventricular remodeling in chronic heart failure rats. *Evid Based Complement Altern Med.* 2018; 2018:1904081. [DOI:10.1155/2018/1904081]
14. Wei-sheng F, Fang-fang Y, Li Z, Yan-yun Y, Zhi-yao B, Meng L, Hui F, Meng-meng L, Xiao-ke Z. Protective effects of aqueous extract from *descurainia sophia* on doxorubicin-induced cardiomyocyte injury via suppressing apoptosis and oxidative stress. *Chin Pharm J.* 2018; 53(23):1999-2007.
15. Johari H, Sharifi E, Ansari N, Hosseini M, Amiri F. Effect of hydro alcoholic ginger extracts on the body weight, testis weight and spermatogenesis in male rats undergoing chemotherapy with cyclophosphamide. *SSUMS.* 2010; 17:365-74.
16. Forouzandeh H, Azemi ME, Rashidi I, Goudarzi M, Kalantari H. Study of the protective effect of *Teucrium polium* L. extract on acetaminophen-induced hepatotoxicity in mice. *IJPR.* 2013; 12:123.
17. Girish C, Koner BC, Jayanthi S, Ramachandra Rao K, Rajesh B, Pradhan SC. Hepatoprotective activity of picroliv, curcumin and ellagic acid compared to silymarin on paracetamol induced liver toxicity in mice. *Fund Clin Pharmacol.* 2009; 23:735-45. [DOI:10.1111/j.1472-8206.2009.00722.x]
18. Aydin G, Gökçimen A, Öncü M, Çicek E, Karahan N, Gökalp O. Histopathologic changes in liver and renal tissues induced by different doses of diclofenac sodium in rats. *Turk J Vet Anim Sci.* 2003; 27:1131-40.
19. Ameer B, Greenblatt DJ. Acetaminophen. *Ann Intern Med.* 1997; 87: 202-09. [DOI:10.7326/0003-4819-87-2-202]
20. Honmore V, Kandhare A, Zanwar AA, Rojatkar S, Bodhankar S, Natu A. *Artemisia pallens* alleviates acetaminophen induced toxicity via modulation of endogenous biomarkers. *Pharm Biol.* 2015; 53:571-81. [DOI:10.3109/13880209.2014.934382]
21. Naguib YM, Azmy RM, Samaka RM, Salem MF. *Pleurotus ostreatus* opposes mitochondrial dysfunction and oxidative stress in acetaminophen-induced hepato-renal injury. *BMC Complem Altern M.* 2014; 14:494. [DOI:10.1186/1472-6882-14-494]
22. Olaleye MT, Rocha BJ. Acetaminophen-induced liver damage in mice: effects of some medicinal plants on the oxidative defense system. *Exp Toxicol Pathol.* 2008;59: 319-27. [DOI:10.1016/j.etp.2007.10.003]
23. Perneger TV, Whelton PK, Klag MJ. 1994. Risk of kidney failure associated with the use of acetaminophen, aspirin, and nonsteroidal antiinflammatory drugs. *N Engl J Med.* 1994; 331:1675-79. [DOI:10.1056/NEJM199412223312502]
24. Lee YJ, Kim NS, Kim H, Yi JM, Oh SM, Bang OS, Lee J. Cytotoxic and anti-inflammatory constituents from the seeds of *Descurainia Sophia*. *Arch Pharm Res.* 2013; 36(5):536-41. [DOI:10.1007/s12272-013-0066-x]
25. Nabimeybodi R, Meyari A, Vahiddastjerdi M, Hajimehdipoor H, Ghasemi E, Bioos S, Tansaz M. The effect of flixweed-honey vaginal product on cervicitis: a clinical trial. *RJP.* 2018; 5(2): 41-9.

How to Cite This Article:

Moshai-Nezhad P, Bahari Z, Jangravi Z, Zarei S M, Iman M. The Effect of *Descurainia Sophia* Seed Extract on Nephrotoxicity Markers Induced by Acetaminophen in Mice. *J Adv Med Biomed Res.* 2021; 29 (134) 139-144

Download citation:

[BibTeX](#) | [RIS](#) | [EndNote](#) | [Medlars](#) | [ProCite](#) | [Reference Manager](#) | [RefWorks](#)

Send citation to:

 [Mendeley](#)  [Zotero](#)  [RefWorks](#) [RefWorks](#)