

## Original Article

## AN EXPERIENCE WITH ANGIOPLASTY AND STENTING OF CAROTID ARTERY STENOSIS WITH EMBOLIC PROTECTION DEVICES

Ali-Mohammad Haji-Zeinali MD\*, Davood Kazemi-Saleh MD\*\*

**Background:** Carotid artery stenting has recently been recommended as an alternative to carotid endarterectomy by some clinicians.

**Objective:** To evaluate success rate, as well as in-hospital and 30-day adverse events in our first experience in Iran for carotid artery stenting with protection devices.

**Methods:** From December 2003 through July 2004, we performed 12 consecutive (9 males and 3 females) carotid artery stenting procedures. The patients had a mean age of 62 (range: 46 – 78) years. Indications for carotid artery stenting included primary lesions in all patients, stenosis  $\geq 50\%$  in symptomatic, and stenosis  $\geq 80\%$  in asymptomatic patients.

**Results:** Carotid artery stenting was technically successful in all 12 patients. The mean  $\pm$  SD severity of stenosis before carotid artery stenting was  $85 \pm 14\%$  as compared with  $15 \pm 10\%$  after the procedure. No periprocedural death occurred. No in-hospital or 30-day minor or major stroke/death was observed.

**Conclusion:** Percutaneous stenting of the carotid artery stenosis, when a cerebral protection device is used, is feasible and effective but not without technical difficulties and potential complications. We, therefore, recommend carotid artery stenting for patients who are at high risk for undergoing carotid endarterectomy. Nevertheless, a long-learning curve may be needed for anyone who wishes to start this technique.

*Archives of Iranian Medicine, Volume 9, Number 2, 2006: 138 – 143.*

**Keywords:** Angioplasty • carotid stenosis • Iran • protection device • stenting

### Introduction

Currently, carotid endarterectomy (CEA) is the recommended standard for management of symptomatic<sup>1–3</sup> and asymptomatic<sup>4,5</sup> high-grade extracranial carotid stenosis. Carotid artery stenting (CAS) has emerged as a useful and potentially less invasive alternative to CEA.<sup>6–11</sup> Recent published consensus statements<sup>12,13</sup> have suggested that CAS may be preferred in certain subgroups of stenotic lesions, including carotid recurrent stenosis after

previous CEA, stenosis in patients at high risk with significant medical comorbidity, anatomically inaccessible lesions above C<sub>2</sub>, and radiation-induced stenosis. However, recent clinical trials have reported<sup>14,15</sup> 30-day stroke and death rates of 10%, raising significant issues and concerns regarding the safety of this new technique. We began our experience with CAS in a prospective case series of patients, who were at risk of CEA, in order to assess our in-hospital and short-term results and to provide guidance for further treatment with CAS in Iran.

### Patients and Methods

From December 2003 through July 2004, a total of twelve consecutive patients underwent percutaneous angioplasty and stenting of the extracranial carotid artery, protected by embolic protection

**Authors' affiliations:** \*Department of Interventional Cardiology, Tehran Heart Center, Tehran University of Medical Sciences, \*\*Baghiatallah University of Medical Sciences, Tehran, Iran.

**Corresponding author and reprints:** Ali-Mohammad Haji-Zeinali MD, Department of Interventional Cardiology, Tehran Heart Center, Tehran University of Medical Sciences, Tehran, Iran. Fax: +98-21-88029724, E-mail: ali\_zeinali\_cardio@yahoo.com.

Accepted for publication: 24 August 2005

devices. Written informed consent for intervention was obtained from all patients.

### **Inclusion criteria**

Symptomatic patients with carotid artery stenosis of  $\geq 50\%$  or asymptomatic patients with stenosis of  $\geq 80\%$  were included in the study. All patients had a primary carotid stenosis and some of them had one or more medical comorbidity for CEA.

### **Exclusion criteria**

These included thrombocytopenia; leucopenia; neutropenia; gastrointestinal tract bleeding during the previous three months; allergy to aspirin, clopidogrel, or ticlopidine; angiographic appearance of fresh thrombus at the carotid lesion site; and angiographic appearance of carotid total occlusion or long preocclusive lesion (string sign lesion).

### **Patient assessment**

Before treatment, all patients underwent careful neurologic examination, performed by an independent board-certified neurologist, echocardiography, color flow Doppler imaging of the lesion site, cerebral computed tomography (CT) scan or magnetic resonance imaging (MRI), and angiographic evaluation.

Within 24 hours following the procedure and after 30 days, all patients underwent another neurologic examination, performed by the same independent neurologist, a complete echocardiography, and color flow Doppler imaging evaluation. A postprocedure cerebral CT scan was only performed in patients with documented neurologic complications.

### **Definitions**

Procedural success after carotid stent deployment was defined as the quantitative carotid angiography showing  $< 30\%$  residual diameter stenosis of all the treated lesions without alternation in the intracranial circulation at the postprocedural angiographic examination. The residual diameter stenosis was assessed by averaging at least two matched views on quantitative angiography. Transient ischemic attack (TIA) was defined as a focal retinal or hemispheric event, from which the patient made a complete recovery within 24 hours. "Minor stroke" was defined as a new neurologic deficit that either resolved completely within 30 days. "Major

stroke" was defined as a new neurologic deficit, which persisted for  $> 30$  days. Finally, "fatal stroke" was defined as death attributed to an ischemic stroke or intracerebral hemorrhagic stroke.

### **Medical treatment**

Before the procedure, all patients were treated with 325 mg/day ASA and 75 mg/day clopidogrel (Plavix) for at least five days before admission. The mean dosage of heparin used during the procedure was 100 units/kg. A mean of one mg atropine was given to patients before balloon inflation. After the procedure, Plavix (75 mg/day) was continued for at least 30 days and ASA was continued indefinitely.


### **Carotid artery stenting protocol and devices**

Local anesthetic (2% lidocaine) was infiltrated at the access site. No sedation was given before or during the procedure. Intraarterial blood pressure was monitored continuously, and the neurologic status was assessed at regular intervals. Activating clotting time (ACT) was maintained at 250 to 300 seconds.

Standard retrograde access was achieved through the common femoral artery, with a 7F vascular sheath. Using a 0.035-inch guide wire (175 cm), the common carotid artery was selectively engaged by the use of a primary guiding catheter. When use of primary guiding catheter was not possible because of particular anatomy of the supraaortic vessels, a stiff wire was placed into the external carotid artery for positioning of a long sheath or guiding catheter into the common carotid artery. Next, all patients underwent an angiographic examination of the culprit carotid lesion in two different projections (anteroposterior [AP] and lateral) and an angiographic examination of the intracranial circulation in the AP and lateral projections. The same angiographic check-up was performed at the end of the procedure, to determine whether there was any variation in the intracranial blood flow (Figure 1). Embolic protection devices were used for all patients. Here, we used two different devices, namely, the Boston Scientific filter wire "EZ" for six patients, and the Guidant filter wire "AccUNET" for another six patients (Figure 2).

### **Carotid stenting**

Carotid stenting was carried out, using self-



**Figure 1.** Carotid angioplasty devices: self-expandable stent (up), filter wire (down).

expandable stents, in all patients. The stents were of two types; Boston Scientific carotid stent “Wallstent” used for six patients, and the Guidant stent “Acculink” used in another six patients. Predilation was performed with coronary balloons in tight or subocclusive carotid stenosis. The predilation balloons were routinely undersized (artery/balloon ratio: 1.5 – 1.8) to reduce vessel dissection and/or distal embolization. Stent placement was optimized with postdilation, by using suitably-sized balloons, based on a quantitative analysis of the vessel. During the postdilation phase, atropine (1 mg IV) was given to all patients before inflation, to reduce the likelihood of bradycardia and hypotension which are potentially associated with carotid dilation.

Patients were transferred to Coronary Care Unit

for two days and discharged on the third day. Neurologic examination was carried out before discharge with duplex and/or CT scan. A significant arterial access site complication was defined as any dissection, hematoma, pseudoaneurysm, arteriovenous fistula, or infection.

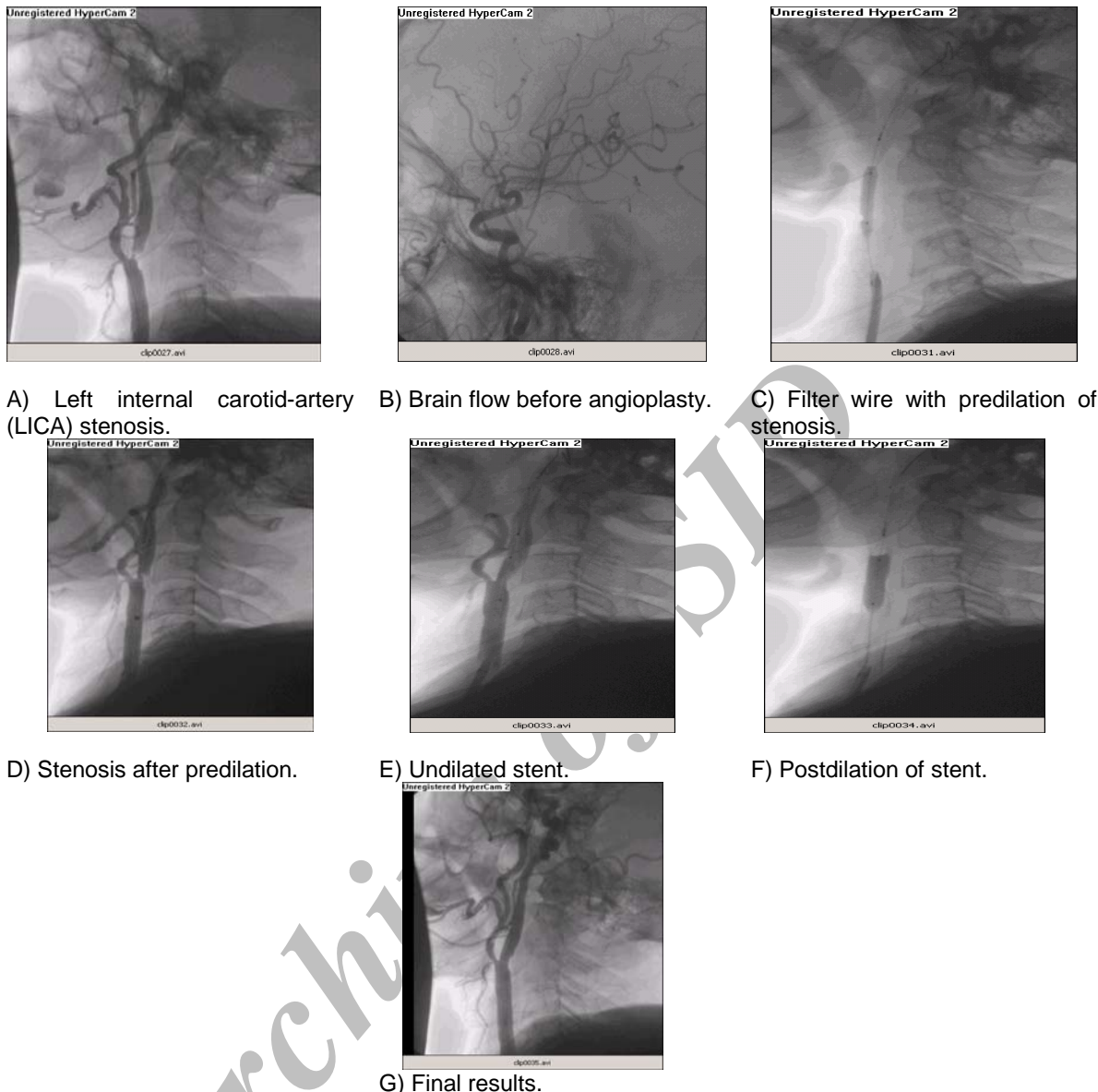
## Results

The demographic and clinical data, angiographic evaluation, and neurologic history characteristics of the study group are summarized in Tables 1 and 2.

All CAS procedures were accomplished successfully with residual stenosis of  $\leq 30\%$ . No contrast extravasation, arterial disruption, or subintimal dissections were observed. Residual

**Table 1.** Clinical data and angiographic evaluation.

Clinical data and angiographic evaluation	N	%
Population	12	100
Male	9	75
Female	3	25
Mean $\pm$ SD age (yr)	62 $\pm$ 16	–
Angiographic evaluation		
Right carotid artery	5	40
Left carotid artery	7	60
Mean lesion length (mm)	25 (range: 15 – 40)	–
Mean severity of stenosis (%)		85 (range: 70 – 99)
Bilateral carotid disease >70%	–	–
Contralateral carotid occlusion	1	8



**Figure 2.** Carotid artery angiography and angioplasty stages (A to G).

stenosis after CAS did not exceed 20% in any case.

The mean  $\pm$  SD residual stenosis was  $15 \pm 5\%$ . Arterial access site hematoma was observed in two patients. No pseudoaneurysm requiring blood transfusion or operative intervention was observed. Simple neurologic examinations, performed during and just after the procedure, were normal. Mild headache and lightheadedness, or small discomfort in the neck, ipsilateral ear, or the mandible, observed in five patients, relieved by itself after a few minutes. Significant bradycardia and one episode of three-second sinoatrial node arrest were noted during the balloon dilatation in three patients. In-hospital stroke and death were not

encountered. All patients were discharged two to four days following the procedure, without any complications or complaints. All patients were checked every two weeks, for a period of 30 days. No stroke was observed over 30 days after the procedure. One patient died of pump failure during coronary artery bypass graft (CABG) surgery performed on the third week after CAS. Another patient readmitted on the second week, for development of congestive heart failure and was

**Table 2.** Neurologic history.

Neurologic history	n	%
Symptomatic patients with culprit lesion	9	75
Asymptomatic patients with culprit lesion	3	25

treated. During the 30-day follow-up, there was no major or minor neurologic complications such as TIA, retinal infarction, or epileptic seizures.

## Discussion

Elective CAS may provide an alternative to CEA, especially in those patients deemed to be at higher risk for endarterectomy. The short-term results derived from the largest series reported to date, comply with the other reports, and suggest that the procedure could be performed with an acceptable complication rate.<sup>9, 14, 15</sup> The long-term durability of CAS, however, has not been previously examined. CAS is now being performed in many centers around the world with low complication rates.<sup>14, 16</sup> Data from a worldwide registry reported a technical success rate of 98.4%, an overall minor stroke rate of 2.7%, a major stroke rate of 1.49%, and a mortality rate of 0.88%.<sup>15</sup> Although techniques used vary slightly between operators and centers, the results are concordant with the findings of the current study, which suggests that CAS can be carried out with acceptable procedural outcomes.

The only randomized study conducted so far, the carotid and vertebral artery transluminal angioplasty study, comparing carotid angioplasty (with bailout stenting in 26% of patients) and CEA, demonstrated similar periprocedural stroke rates for the two groups (10% vs. 9.9%, respectively).<sup>17</sup> Satisfactory comparison of the results obtained from this study with those of the complication rates obtained from the published CEA studies, restricted because of the difference in the case mix, completeness of neurologic evaluation, and nonstandardized end-points. In particular, a large proportion of the symptomatic patients in this study were North American Symptomatic Carotid Endarterectomy Trial (NASCET) ineligible.<sup>18</sup> Nonetheless, stroke rates (often CAS) appear to be in a range similar to those observed in randomized trials of CEA for symptomatic patients. In NASCET, the 30-day rate of minor stroke was 4%, major stroke 1.6%, mortality rate 1.2%, and the overall stroke and mortality rates were 6.7% in patients with symptomatic carotid stenosis ( $\geq 50\%$  diameter stenosis) randomized to the CEA arm.<sup>19</sup> The Veterans Affairs Cooperative Study (VACS) also reported a 30-day stroke and mortality rate of 6.5%.<sup>3</sup> The European Carotid Stent Trial (ECST) reported an overall major stroke and mortality rates

of 7% in patients with symptomatic carotid stenosis.<sup>20</sup> In symptomatic patients, comparison is particularly difficult. The Asymptomatic Carotid Atherosclerosis Study (ACAS) reported periprocedural stroke and mortality rates of 2.3% in a lower-risk subset.<sup>21</sup> The asymptomatic surgical group in VACS suffered a 4.7% permanent stroke and mortality rate.<sup>4</sup>

Many of our patients were thought to be very poor candidates for undergoing surgical operation, due to the existence of comorbid states such as severe coronary artery disease, pulmonary disease, advanced age, severe cerebrovascular disease, or other factors elevating the risk of surgery. Forty percent of the patients were referred by surgeons. Our patients had an average score of 3.5 on the Mayo Clinic Carotid Endarterectomy Risk Scale. In the Mayo Clinic series, the incidence of major complications (i.e., permanent stroke, MI, or death) was 3.1% for grade 3 and 8.1% for grade 4 patients. With the use of stenting,<sup>22</sup> we were able to reduce balloon inflation time and minimize cerebral blood flow interruption to 15 – 30 seconds. This was well-tolerated by patients, even those with contralateral carotid occlusion.

We accomplished carotid stenting in twelve consecutive procedures, with a technical success rate of 100%. The mean residual stenosis, immediately, postprocedure was  $15 \pm 5\%$ . This indicates technical feasibility of CAS, once appropriate training and experience with necessary catheter and guide wire skills are obtained. Further technical improvements, such as employing distal-protection devices during stenting, will certainly improve periprocedural outcomes for both asymptomatic and symptomatic patients. In the present study, in-hospital major stroke, MI, and death were not seen. Minor stroke and TIA were also not reported by our neurologist. Some neurologic symptoms, such as headache and lightheadedness were recovered a few hours after the procedure. Two vascular complications—one hematoma and one small distal emboli (treated medically)—were reported. On cardiovascular and neurologic examinations performed two weeks and 30 days after the treatment, no major stroke, TIA, minor stroke, and death was observed. One patient died of pump failure after CABG three weeks after the procedure (month mortality of 8%).

Our good results and success rate, as well as the low early and 30-day complication rates might be due to the number of patients, as compared to the international studies such as NACET and ACAS.

We are in need of long-term studies, including a greater number of patients, along with appropriate follow-ups in order to make our study comparable with other multicenter studies. The potential advantages of CAS over CEA include avoidance of neck wound complications and cranial nerve palsies, as well as a reduction in periprocedural MI. These results underscore the need to validate this less invasive procedure against CEA, which is the current “gold standard” surgically-proven treatment for carotid artery disease. Each center should make a decision regarding the continued use of CAS on the basis of their individual experiences.

### Acknowledgment

The authors wish to acknowledge the valuable contributions of Oscar A. Mendiz, MD, FACC, Head of the Department of Interventional Cardiology of Favaloro Foundation of Buenos Aires, Argentina and M. Rezaei MD, from the Interventional Department of Stanford University, USA, for their assistance in holding two carotid stenting workshops in Tehran Heart Center.

### References

- No authors listed. Beneficial effect of carotid endarterectomy in symptomatic patients with high-grade carotid stenosis. North American Symptomatic Carotid Endarterectomy Trial Collaborators. *N Engl J Med*. 1991; **325**: 445 – 453.
- No authors listed. MCR European Carotid Surgery Trial: interim results for symptomatic patients with severe (70 – 99%) or with mild (0 – 29%) carotid stenosis. European Carotid Surgery Trialists' Collaborative Group. *Lancet*. 1991; **337**: 1235 – 1243.
- Mayberg MR, Wilson SE, Yatsu F, et al. Carotid endarterectomy and prevention of cerebral ischemia in symptomatic carotid stenosis. Veterans Affairs Cooperative Studies Program 309 Trialist Group. *JAMA*. 1991; **266**: 3289 – 3294.
- Hobson RW, Weiss DG, Fields WS, et al. Efficacy of carotid endarterectomy for asymptomatic carotid stenosis. The Veterans Affairs Cooperative Study Group. *N Engl J Med* 1993; **328**: 221 – 227.
- No authors listed. Endarterectomy for asymptomatic carotid artery stenosis. Executive Committee for the Asymptomatic Carotid Atherosclerosis Study. *JAMA*. 1995; **273**: 1421 – 1428.
- Theron J, Raymond J, Casasco A, Courtheoux F. Percutaneous angioplasty of atherosclerotic and postsurgical stenosis of carotid arteries. *AJNR Am J Neuroradiol*. 1987; **8**: 495 – 500.
- Roubin GS, Yadav S, Iyer SS, Vitek J. Carotid stent-supported angioplasty: a neurovascular intervention to prevent stroke. *Am J Cardiol*. 1996; **78**: 8 – 12.
- Diethrich EB, Ndiaye M, Reid BD. Stenting in the carotid artery: initial experience in 110 patients. *J Endovasc Surg*. 1996; **3**: 42 – 62.
- Yadav JS, Roubin GS, Iyer S, et al. Elective stenting of the extracranial carotid arteries. *Circulation*. 1997; **95**: 376 – 381.
- Hobson RW, Goldstein JE, Jamil Z, et al. Carotid restenosis: operative and endovascular management. *J Vasc Surg*. 1999; **29**: 228 – 238.
- Hobson RW, Lal BK, Chakhtoura EY, et al. Carotid artery closure for endarterectomy does not influence results of angioplasty stenting for restenosis. *J Vasc Surg*. 2002; **35**: 435 – 438.
- Bettmann MA, Katzen BT, Whisnant J, et al. Carotid stenting and angioplasty: a statement for healthcare professionals from the Councils on Cardiovascular Radiology, Stroke, Cardio-Thoracic and Vascular Surgery, Epidemiology and Prevention, and Clinical Cardiology, American Heart Association. *Stroke*. 1998; **29**: 336 – 338.
- Veith FJ, Amor M, Ohki T, et al. Current status of carotid bifurcation angioplasty and stenting based on a consensus of opinion leaders. *J Vasc Surg*. 2001; **33** (2 suppl): S111 – 116.
- Henry M, Amor M, Masson I, et al. Angioplasty and stenting of the extracranial carotid arteries. *J Endovasc Surg*. 1998; **5**: 293 – 304.
- Wholey MH, Wholey M, Mathias K, et al. Global experience in cervical carotid artery stent placement. *Cathet Cardiovasc Interv*. 2000; **50**: 160 – 167.
- Mathias K, Jager H, Sahl H, Hennigs S, Gissler HM. Interventional treatment of arteriosclerotic carotid stenosis [in German]. *Radiology*. 1999; **39**: 125 – 134.
- Brown M. Results of the carotid and vertebral artery transluminal angioplasty study (CAVATAS). *Cerebrovasc Dis*. 1998; **8** (suppl 4): 21.
- No authors listed. Beneficial effect of carotid endarterectomy in symptomatic patients with high-grade carotid stenosis. North American Symptomatic Carotid Endarterectomy Trial Collaborates. *N Engl J Med*. 1991; **325**: 445 – 453.
- Barnett HI, Taylor DW, Eliasziw M, et al. Benefit of carotid endarterectomy in patients with symptomatic moderate or severe stenosis. North American Symptomatic Carotid Endarterectomy Trial Collaborates. *N Engl J Med*. 1998; **339**: 1415 – 1425.
- No authors listed. Randomised trial of endarterectomy for recently symptomatic carotid stenosis: final results of the MRC European Carotid Surgery Trial (ECST). *Lancet*. 1998; **351**: 1379 – 1387.
- No authors listed. Endarterectomy for asymptomatic carotid artery stenosis. Executive Committee for the Asymptomatic Carotid Atherosclerosis Study. *JAMA*. 1995; **273**: 1421 – 1428.
- Sundt TM Jr, Meyer FB, Piepgras SG, Fodee NC, Ebersold NJ, Marsh WR. Risk factors and operative results. In: Meyer FB, ed. *Sundt's Occlusive Cerebrovascular Disease*. 2nd ed. Philadelphia, Pa: WB Saunders; 1994: 241 – 247.