Radiology Case Reports 16 (2021) 2534–2536

Available online at www.sciencedirect.com

ScienceDirect

journal homepage: www.elsevier.com/locate/radcr

Case report

Simultaneous Giant cavity pulmonary lesion and pneumothorax following COVID-19 pneumonia ☆,☆☆

Ramezan Jafari, PhD[a], Luca Cegolon, MD, MSc, PhD[b], Houshyar Masghsoudi, PhD[a], Shi Zhao, PhD[c], Saeid Fathi, PhD[d], Leila Khedmat, PhD[e], Mohammad Javanbakht, PhD[f,]*

[a] *Department of Radiology, Baqiyatallah University of Medical Sciences, Tehran, Iran*
[b] *Local Health Unit N. 2 "Marca Trevigiana", Public Health Department, Treviso, Italy*
[c] *JC School of Public Health and Primary Care, Chinese University of Hong Kong, Hong Kong*
[d] *Tehran University, Tehran, Iran*
[e] *Health Management Research Center, Baqiyatallah University of Medical Sciences, Tehran, Iran*
[f] *Nephrology and Urology Research Center, Baqiyatallah University of Medical Sciences, Tehran, Iran*

ARTICLE INFO

Article history:
Received 28 May 2021
Revised 8 June 2021
Accepted 8 June 2021
Available online 14 June 2021

Keywords:
COVID-19
Lung
Pneumothorax
Cavitary

ABSTRACT

Cavitary lung formation with spontaneous pneumothorax has been rarely reported as a complication of COVID-19 pneumonia. We report a rare case of a 38 years-old male patient affected by COVID-19 pneumonia, exceptionally complicated by a simultaneous giant cavity in the right upper lung and a small right pneumothorax in the right hemithorax. Whilst pneumothorax emphysema, giant bullae and pneumothorax with alveolar rupture are known to potentially develop in COVID-19 patients as a result of high-flow O_2 support, the exact origin of the giant lung cavitation in our patient could be not confirmed. Cavitary lesions – featured by high mortality rate - are reportedly associated with lung infarctions and can be the aftermaths of pulmonary embolism, a rather common sequela of COVID-19 pneumonia. Radiological imaging is critical to support clinical decision making in the management of COVID-19 pneumonia, since not only it can visualize and stage the disease, but it can also detect and monitor the eventual onset of complications over time, even following patient discharge from hospital.

Introduction

COVID-19 can present in various manifestations and computed tomographic (CT) imaging plays an critical role in diagnosing the stages of pneumonia caused by SARS-CoV-2 [1].

Idiopathic cavitary pulmonary lesions and pneumothorax are rare complications reportedly affecting a small proportion of COVID-19 patients [2-6],

Herein, we report a 38 years old male patient affected by COVID-19 pneumonia, developing simultaneous lung cavitation and pneumothorax.

☆ Acknowledgments: Not applicable.
☆☆ Thanks to guidance and advice from "Clinical Research Development Unit of Baqiyatallah Hospital"
* *Corresponding author.*
E-mail address: mhmjvbt81@gmail.com (M. Javanbakht).
https://doi.org/10.1016/j.radcr.2021.06.026

Case presentation

On February 25, a 38-year-old-male patient presented to accident & emergency service (A&E) of Baqiyatallah hospital in Tehran (Iran) for fever (38°C), complaining shortness of breath, chilling and malaise during the preceding 4 days. The patient had no relevant medical history.

Baseline O_2 saturation at admission was 85%, increasing up to 92% following O_2 supplementation. Laboratory tests showed a white blood cell count of 10,200/mm^3 with 6.2% lymphocytes. The erythrocyte sedimentation rate (ESR = 84 mm/h) and the C reactive protein (CRP = 114.2 mg/L) were both importantly elevated. Liver function tests were also considerably abnormal [SGOT (AST) = 193 IU/L; SGPT (ALT) = 406 IU/L; alkaline phosphatase (ALP) = 609 IU/L]. Real time reversed polymerase chain reaction (RT-PCR) following nasopharyngeal swab samples resulted positive for SARS-CoV-2 infection.

A Spiral multi-slice chest CT scan, performed on the same day of A&E admission, showed bilateral multilobar patchy ground glass opacities (GGOs) and consolidative lung opacities (CLO) with peripheral lung distribution (Fig. 1A), a radiological pattern compatible with COVID-19 pneumonia.

The patient was treated with oral hydroxychloroquine sulfate 200mg twice a day, oral oseltamivir 75 mg twice a day, palliative therapy and O_2 supplements. After 10 days of the latter treatment regimen, the WBC count decreased to 4.90/mm3 and the lymphocyte rate increased up to 24%. The ESR (95 mm/h) and CRP (115 mg/L) were still both elevated. The O_2 saturation increased up to 89% without respiratory support and the patient's symptoms improved. As the patient's health conditions were progressively improving, a follow-up spiral chest computerized tomography (CT) scan, performed after 10 days since hospital admission, showed a significant reduction of the CLO and GGOs. However, the CT scan also revealed a giant cavity of about 40mm diameter, with a thick irregular wall in the right upper lung and a small pneumothorax in the right hemithorax (Fig. 1B).

Discussion

Classic COVID-19 pneumonia presents with GGO and CLO, predominantly in the lower lung lobes, without cavitary lesions, pneumothorax, lymphadenopathy and pleural effusion [3,4,7,8]. Complications of COVID-19 pneumonia can still arise over time and cavitary lung lesions (also of gigantic size) as well as pneumothorax have also been reported [2,4,9-13]. Nevertheless, a simultaneous pneumothorax as well as cavitary lung formation is an exceptional and idiopathic feature.

Spontaneous pneumotorax can be a late evolution of COVID-19 pneumonia [14], although a bilateral sudden onset was also described in a 50 year old male smoker with history of mandibular carcinoma [15]. Emphysema, giant bullae and pneumothorax with alveolar rupture can develop in COVID-19 patients as a result of high-flow O_2 support [12].

By contrast, pulmonary cavitary lesions are usually associated with mycobacterial diseases, fungal or parasitic infections, malignancies or autoimmune disorders [16,17]. Although the exact origin of the giant lung cavitation in our patient was not confirmed, diffuse alveolar damage, intra-alveolar haemorrhage and parenchymal necrosis associated with COVID-19 pneumonia can be explanatory factors [18,19]. Furthermore, cavitary lesions are reported in 4%-7% lung infarctions and can be the aftermaths of pulmonary embolism, a rather common complication of COVID-19 pneumonia [20, 21].

High mortality rates are reported with cavitations with due to pulmonary infarctions, whether infected or not [22]. Radiological imaging is therefore critical to support clinical decision making in the management of COVID-19 pneumonia, since not only it can visualize and stage the disease, but it can also

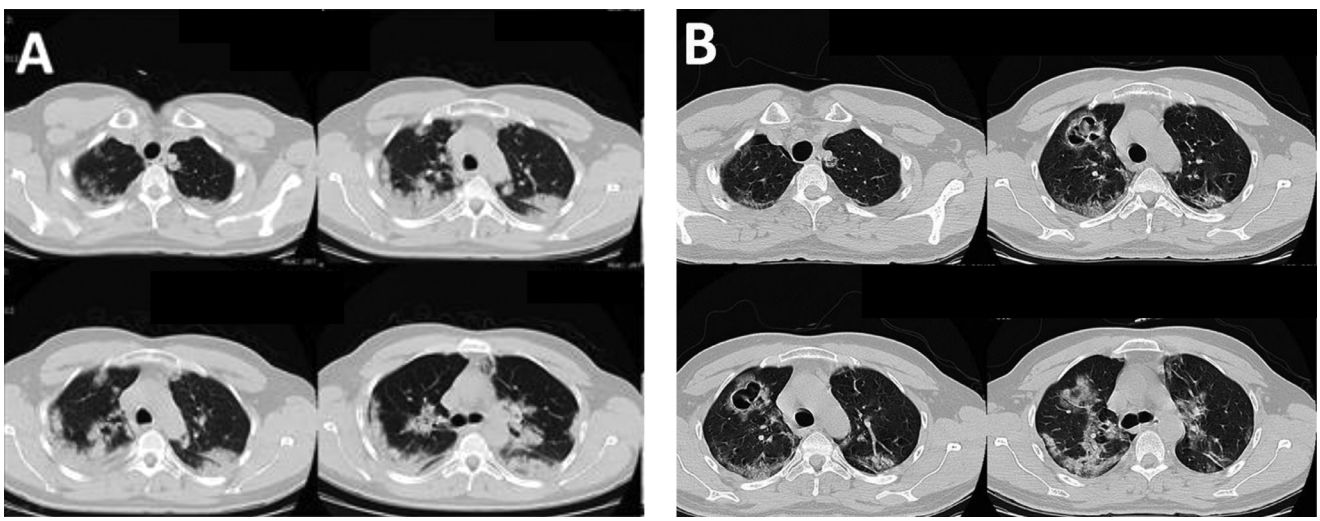

Fig. 1 – (A) Four IMAGES (on the first day, at hospital admission): multifocal subpleural patchy consolidative opacities compatible with COVID-19 pneumonia confirmed by RT-PCR test. (B) Four IMAGES (10 days later, at same chest level): significant clinical response to drug treatment, with a small right pneumothorax (black arrow) and an irregular wall cavitary lesion of about 40 mm in diameter (white arrow) at the right upper lung lobe.

detect and monitor the eventual onset of complications over time, even following patient discharge from hospital [4].

Authors' contributions

All authors contributed equally to the drafting, designing and writing of the manuscript and provided critical revision. All authors read and approved the final manuscript.

Ethics approval and consent to participate

This case report has been described in accordance with the ethical standards laid down in the "Declaration of Helsinki 1964."

Patient consent

Informed written consent was taken from the patient

Declaration of Competing Interest

The authors declare that they have no known competing financial interests or personal relationships that could have appeared to influence the work reported in this paper.

REFERENCES

[1] Campagnano S, Angelini F, Fonsi GB, Novelli S, Drudi FM. Diagnostic imaging in COVID-19 pneumonia: a literature review. J Ultrasound 2021:1–13.

[2] Zoumot Z, Bonilla MF, Wahla AS, Shafiq I, Uzbeck M, El-Lababidi RM, et al. Pulmonary cavitation: an under-recognized late complication of severe COVID-19 lung disease. BMC Pulm Med 2021;21(1):24.

[3] Chen Y, Chen W, Zhou J, Sun C, Lei Y. Large pulmonary cavity in COVID-19 cured patient case report. Ann Palliat Med 2021;10(5):5786–91 Jun 9:apm-20-452.

[4] Selvaraj V, Dapaah-Afriyie K. Lung cavitation due to COVID-19 pneumonia. BMJ Case Rep 2020;13(7): e237245.

[5] Martinelli AW, Ingle T, Newman J, Nadeem I, Jackson K, Lane ND, et al. COVID-19 and pneumothorax: a multicentre retrospective case series. Eur Respir J 2020;56(5): 2002697.

[6] Alhakeem A, Khan MM, Al Soub H, Yousaf Z. Case report: COVID-19-associated bilateral spontaneous pneumothorax-a literature review. Am J Trop Med Hyg 2020;103(3):1162–5.

[7] Chung M, Bernheim A, Mei X, Zhang N, Huang M, Zeng X, et al. CT imaging features of 2019 novel coronavirus (2019-nCoV). Radiology 2020;295:202–7.

[8] Haseli S, Khalili N, Bakhshayeshkaram M, Taheri MS, Moharramzad Y, et al. Lobar distribution of COVID-19 pneumonia based on chest computed tomography findings; a retrospective study. Arch Acad Emerg Med 2020;8:e55.

[9] Afrazi A, Garcia-Rodriguez S, Maloney JD, Morgan CT. Cavitary lung lesions and pneumothorax in a healthy patient with active coronavirus-19 (COVID-19) viral pneumonia. Interact Cardiovasc Thorac Surg 2021;32(1):150–2.

[10] Ammar A, Drap é J, Revel M. Lung cavitation in COVID-19 pneumonia. Diagn Interv Imaging 2021;102(2):117–18.

[11] Marchiori E, Nobre LF, Hochhegger B, Zanetti G. Pulmonary infarctions as the cause of bilateral cavitations in a patient with COVID-19. Diagn Interv Radiol 2020 (16 December)https://doi.org/10.5152/dir.2020.20865 [Epub Ahead of Print].

[12] Vural A, Kahraman AN. Pulmonary embolism and giant cavitary lesion developing after COVID-19 pneumonia. HCA Healthcare J Med 2020 1: Iss. 0, Article 11.

[13] Ufuk F, Yavas HG, Kis A. An unusual cause of spontaneous pneumothorax: post-COVID-19 pulmonary fibrosis. Am J Emerg Med 2021 S0735-6757(21)00371-5.

[14] Shirai T, Mitsumura T, Aoyagi K, Okamoto T, Kimura M, Gemma T, et al. COVID-19 pneumonia complicated by bilateral pneumothorax: a case report. Respir Med Case Rep 2020;31:101230.

[15] Teng E, Bennett L, Morelli T, Banerjee A, et al. An unusual presentation of pulmonary embolism leading to infarction, cavitation, abscess formation and bronchopleural fistulation. BMJ Case Rep 2018 2018.

[16] Koroscil MT, Hauser TR. Acute pulmonary embolism leading to cavitation and large pulmonary abscess: a rare complication of pulmonary infarction. Respir Med Case Rep 2017;20:72–4.

[17] Menter T, Haslbauer JD, Nienhold R, Savic S, Hopfer H, Deigendesch N, et al. Post-Mortem examination of COVID19 patients reveals diffuse alveolar damage with severe capillary congestion and variegated findings of lungs and other organs suggesting vascular dysfunction. Histopathology 2020:198–209.

[18] Yao XH, Li TY, He ZC, Ping YF, Liu HW, Yu SC, et al. A pathological report of three COVID-19 cases by minimal invasive autopsies. Zhonghua Bing Li Xue Za Zhi 2020;49:411–17.

[19] Libby LS, King TE, LaForce FM, Schwarz MI. Pul- monary cavitation following pulmonary infarc- tion. Medicine (Baltimore) 1985;64(5):342–8.

[20] Griffin DO, Jensen A, Khan M, Chin J, Chin K, Saad J, et al. Pulmonary embolism and increased levels of d-Dimer in patients with coronavirus disease. Emerg Infect Dis 2020;26(8):1941–3.

[21] Butler MD, Biscardi FH, Schain DC, Humphries JE, Blow O, Spotnitz WD. Pulmonary resection for treatment of cavitary pulmonary infarction. Ann Thorac Surg 1997;63(3):849–50.