

Available online at www.sciencedirect.com

ScienceDirect

journal homepage: www.elsevier.com/locate/radcr

Case Report

Simultaneous spontaneous pneumomediastinum and pneumopericardium in a critically ill patient with COVID-19[☆]

Mohammad Javad Behzadnia, PhD^a, Abbas Samim, PhD^b, Fatemeh Saboori, PhD^a, Mosa Asadi, PhD^c, Mohammad Javanbakht, PhD^{c,*}

^aTrauma Research Center, Baqiyatallah University of Medical Sciences, Tehran, Iran

^bChemical Injuries Research Center, Baqiyatallah University of Medical Sciences, Tehran, Iran

^cNephrology and Urology Research Center, Baqiyatallah University of Medical Sciences, Tehran, Iran

ARTICLE INFO

Article history:

Received 28 June 2021

Revised 19 July 2021

Accepted 24 July 2021

Available online 30 July 2021

Keywords:

Pneumomediastinum

Pneumopericardium

CT

Lung

COVID-19

ABSTRACT

Case in the paper is of a 24-year-old woman presenting to Baqiyatallah hospital, Tehran, Iran with the occasional fever, weakness, myalgia, fatigue, body aches, and headache who was diagnosed with Coronavirus disease-19 (COVID-19) PCR test. Chest computed tomography (CT) showed spontaneous pneumomediastinum (SPM) and pneumopericardium (SPP). Here, we described SPM, and SPP in a patient with COVID-19, presenting a severe course of the disease.

© 2021 The Authors. Published by Elsevier Inc. on behalf of University of Washington.

This is an open access article under the CC BY-NC-ND license

(<http://creativecommons.org/licenses/by-nc-nd/4.0/>)

Introduction

Severe acute respiratory syndrome coronavirus 2 (SARS-CoV-2) poses crucial health challenges for medical and public health systems worldwide [1,2]. Clinical manifestation of Coronavirus disease 2019 (COVID-19) vary from asymptomatic to severe disease [3–7]. Rare reports described com-

plications such as spontaneous pneumomediastinum (SPM), and pneumopericardium (SPP), as well as pneumothorax, and subcutaneous emphysema in patients suffered from COVID-19 [8–11].

We reported a rare finding of SPM and SPP complications in COVID-19 patient receiving non-invasive ventilation (NIV). Here, we presented clinical manifestation, outcome and management of a COVID-19 case with SPM, and SPP.

[☆] Competing Interests: The authors declare that they have no known competing financial interests or personal relationships that could have appeared to influence the work reported in this paper

* Corresponding author.

E-mail address: mhmjvbt81@yahoo.com (M. Javanbakht).

<https://doi.org/10.1016/j.radcr.2021.07.062>

1930-0433/© 2021 The Authors. Published by Elsevier Inc. on behalf of University of Washington. This is an open access article under the CC BY-NC-ND license (<http://creativecommons.org/licenses/by-nc-nd/4.0/>)

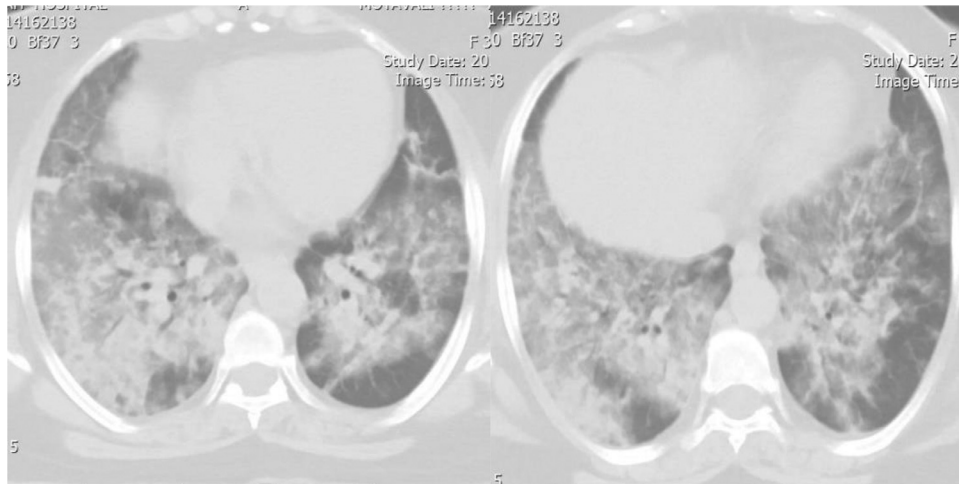


Fig. 1 – First day of admission. The CT scan showed only diffused lung consolidations.

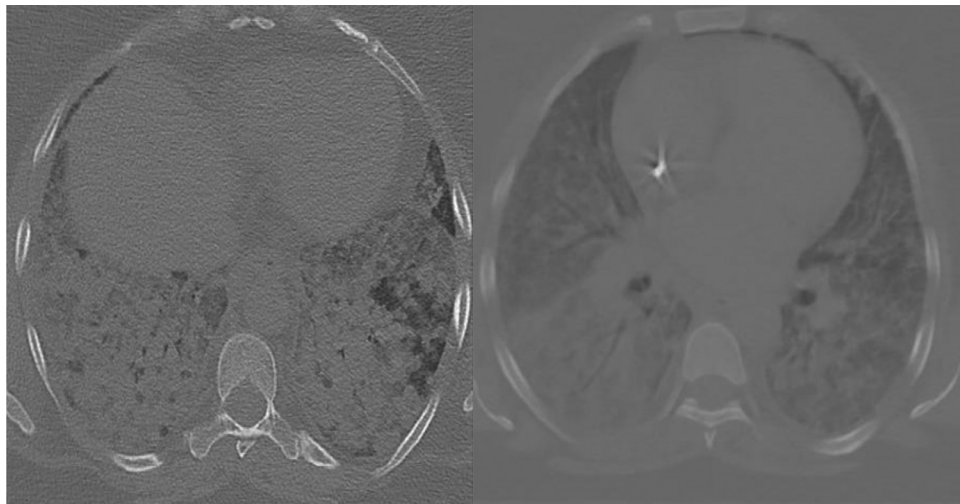


Fig. 2 – CT scan of the lungs showed the progression of lung lesions and were highly recommend of COVID-19 pneumonia within 72 hours later.

Case presentation

We present a case of a 24-year-old woman presenting to hospital ward with the complaint of occasional fever, myalgia, fatigue, body aches, and headache. At admission, her examination revealed a progressive dyspnea that had gradually worsened. The patient did not exhibit some of the COVID-19 infection symptoms including nausea, diarrhea, and vomiting, as well as loss of smell and taste. At the time of referral, vital signs were as follows: BP: 125/70; PR: 110/Min; RR: 25/Min; O₂Sat: 85% (without supplemental O₂), O₂Sat: 94% (by using mask); T: 37.2C (Fig. 1).

Nothing special was found in examination except for respiratory distress, tachypnea, and scattered crackles on the surface of the lungs. The patient was admitted to the hospital ward on January 26, 2021. The patient was diagnosed with

COVID-19 by RT-PCR. She transferred to the ICU 42 hours after hospitalization due to severe dyspnea. Scheduled medications included dexamethasone 8 mg (twice a day), melatonin 6 mg daily, enoxaparin 6000 IU twice daily (60 mg), famotidine 40 mg twice daily, and vitamin D3 (50,000-100,000 IU/week). Reserve-bag oxygen therapy was also performed for patient. Three days later, the patient dyspnea was worsened. The pulmonary CT scan showed progression of lung lesions, presenting typical finding of COVID 19 infection (Fig. 2).

Therefore, the patient was administered 250 mg methylprednisolone pulse for 3 days and 2 sessions with CytoSorb were performed within the following 24 hours. She rapidly developed exacerbation of dyspnea and a decrease in oxygen saturation, requiring non-invasive ventilation (PS: 18-20, PEEP: 10-12) due to O₂Sat of 70% on January 30, 2021, leading to improved O₂Sat to some extent (80%). Fur fays after being on non-invasive ventilation. She developed pneumome-

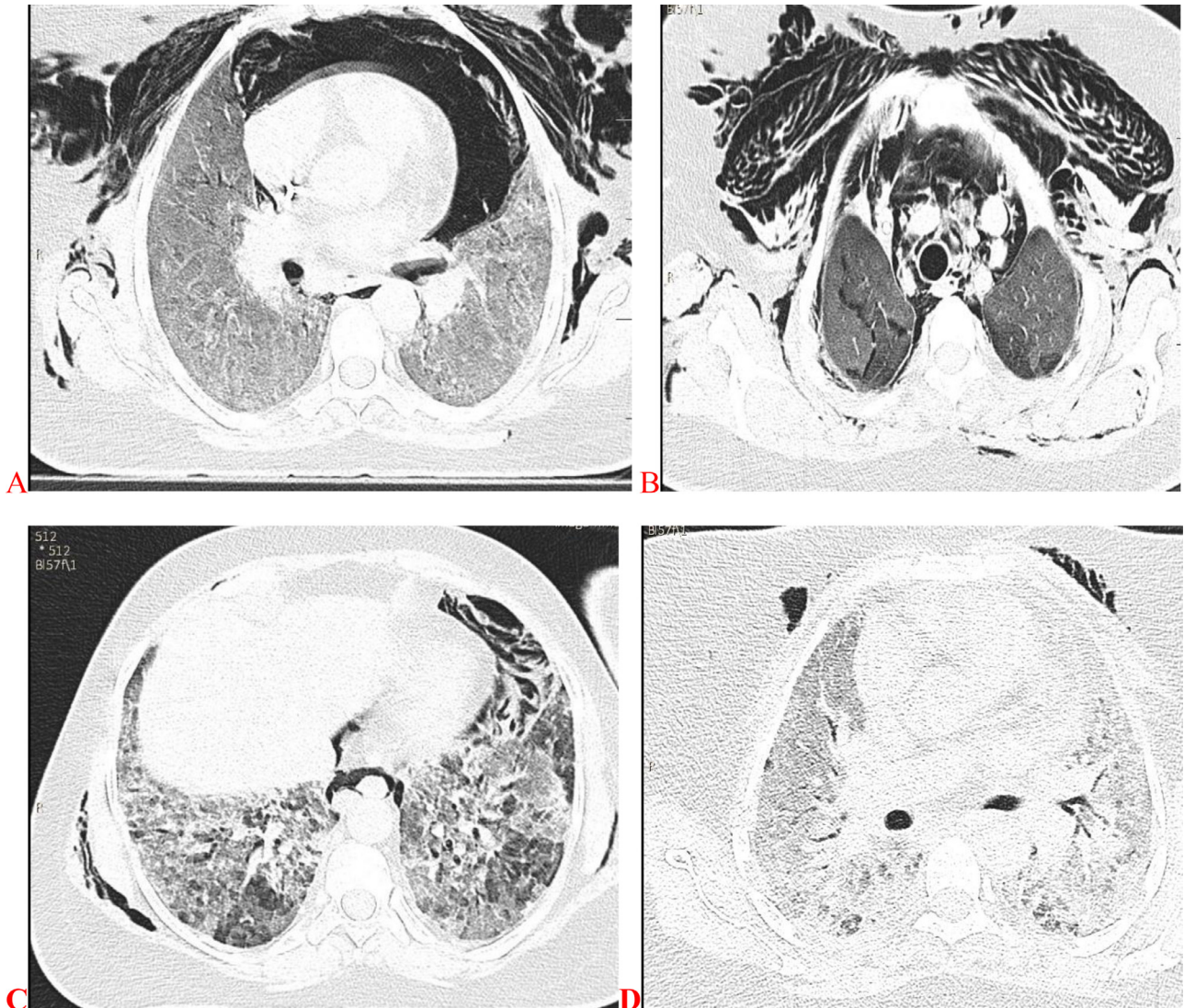


Fig. 3 – Bilateral lung involved by Covid-19 infection, massive air is seen around the heart, and bilateral soft tissue emphysema. (A and B). Ground glass opacities combined with consolidation are seen 10 days later after the air resorption (C and D).

diastinum and pneumopericardium, as well as a decrease in O₂Sat (decreased from 80% to 58%). The O₂Sat improved relatively with the increase of positive end expiratory pressure (PEEP) and pressure support (PS), reaching 91%. Fortunately, her echocardiography revealed no signs of cardiac tamponade (Figs. 3 A and B). Based on the symptoms, the patient alternately received NIV nasal mask. Twelve days later, achieving O₂S at greater than 93% was found to improve her clinical condition. Two days later, the pulmonary CT scan revealed improvement of pneumomediastinum and pneumopericardium. During this time, medical management consisted of dexamethasone 8 mg daily, meropenem (1 g every 8 hours), Targocid 400 mg daily, 3 g/day vitamin C, ASA 80 mg daily, and atorvastatin 40 mg daily.

Following these significant findings, the NIV procedure was discontinued. Laboratory findings showed melena, hematochezia, and a decrease of hemoglobin within the following

2 days, while emergency endoscopy was found to be normal. Two days later, our patient exhibited delirium and restlessness, and psychiatric counseling was initiated due to refusing treatment. Therefore, she received haloperidol, and sertraline. At this time, nasogastric (NG) Tube was implanted for our patient, followed by gavage of medicine and food. Given worsening O₂Sat level, the patient was commenced on NIV for 6 days until her mental condition returned to normal. Then, oral feeding was started and her NIV was discontinued. Seven days later, her clinical condition started improving. Her dexamethasone administration was gradually reduced and then transferred to the hospital ward. With the above treatment, her O₂Sat kept improving, and patient was then discharged home along with nasal oxygen (Figs. 3 C and D).

She was closely followed up and he continued having CT scan. Her last lung CT after 2 months revealed a complete re-

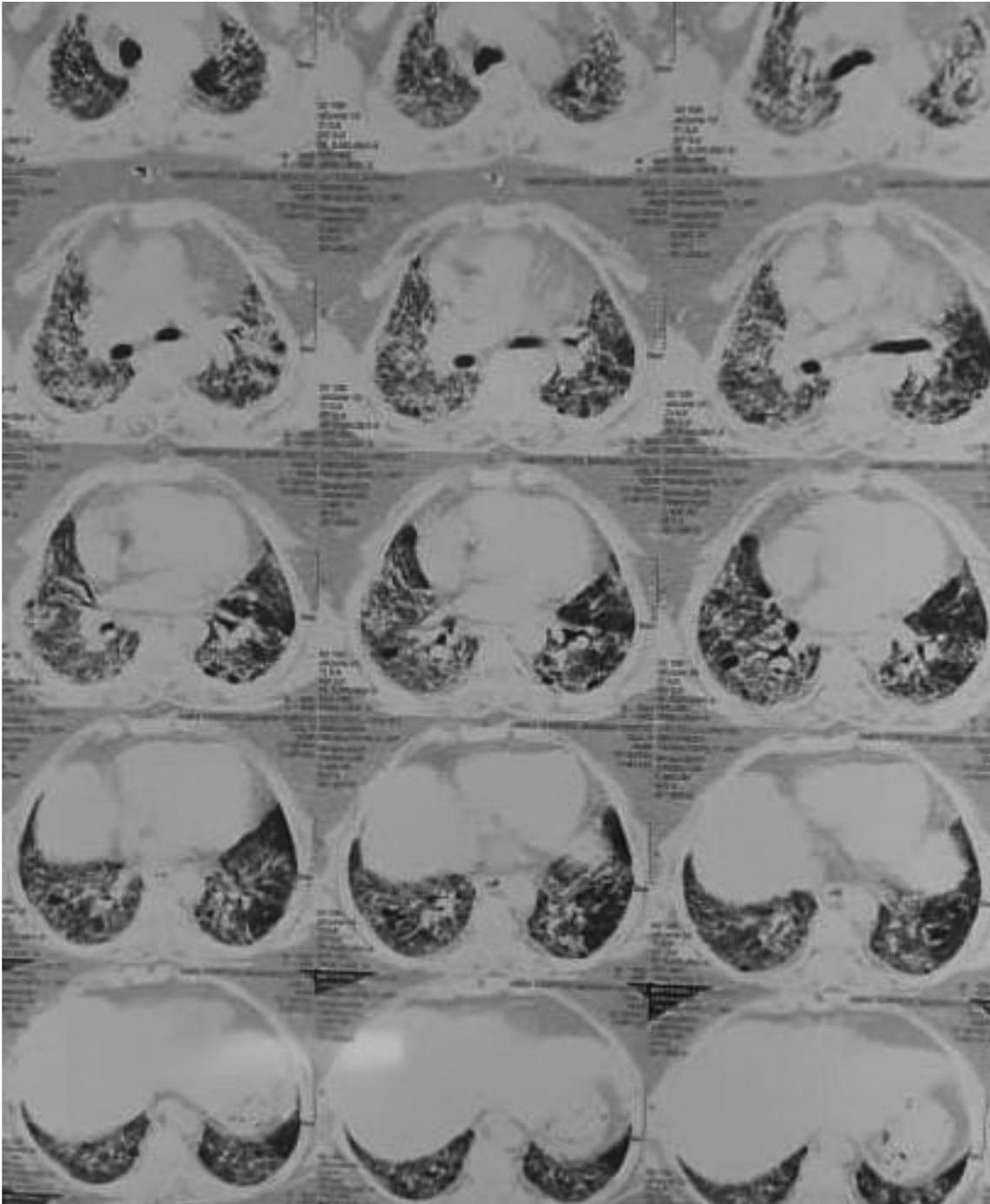


Fig. 4 – The lung CT Scan 2 month after recover at home. The lesions are resolved and there is no evidence of pneumomediastinum and pneumopericardium.

sorption of air. She is now in a stable condition without any supplemental oxygen (Fig. 4).

Discussion

Air leakage via diffuse alveolar damage (DAD) into the interstitium of the lung results in pneumomediastinum and its

travel into the pleural or pericardial space has been described to be associated with pneumothorax and pneumopericardium [12-14].

Rare complications such as SPM, SPP, and pneumothorax have been reported in relation to COVID-19 [8-10,15,16].

Diffuse alveolar damage has been revealed to be predominate pattern of pulmonary injury in patients suffered from COVID-19 as reported by pulmonary post-mortem findings [17]. Herein, the authors report SPM and SPP in a case of

COVID-19 in association with a severe course of the disease, suggesting their association with poor prognosis, further investigations may be capable of clarifying the association of spontaneous alveolar air leakage with outcomes of COVID-19 patients, eg, poor prognosis.

The presented case was a critically ill covid-19 patient with a poor outcome that survived with critical ICU care and continuous follow up. Accordingly, SPM, and SPP are rarely occurred without any positive pressure ventilation. Surprisingly, the patient started to recovery during 2 days after receiving the medical treatments without any invasive intervention. This case also showed one of the rare covid 19 complications and reasons of deterioration in such cases.

Patient consent

The authors obtained written informed consent from the patient for submission of this manuscript for publication.

REFERENCES

- [1] Al-Tawfiq JA, Al-Yami SS, Rigamonti D. Changes in healthcare managing COVID and non-COVID-19 patients during the pandemic: striking the balance. *Diagn Microbiol Infect Dis* 2020;98(4):115147.
- [2] Li D, Jin M, Bao P, Zhao W, Zhang S. Clinical characteristics and results of semen tests among men with coronavirus disease 2019. Erratum in: *JAMA Netw Open* 2020;3(6):e2010845.
- [3] Zhou F, Yu T, Du R, Fan G, Liu Y, Liu Z, et al. Clinical course and risk factors for mortality of adult inpatients with COVID-19 in Wuhan, China: a retrospective cohort study. *Lancet* 2020;395(10229):1054–62.
- [4] Al Mutair A, Alhumaid S, Alhuqbani WN, Zaidi ARZ, Alkoraisi S, Al-Subaie MF, et al. Clinical, epidemiological, and laboratory characteristics of mild-to-moderate COVID-19 patients in Saudi Arabia: an observational cohort study. *Eur J Med Res* 2020;25(1):61.
- [5] Aljishi JM, Alhajjaj AH, Alkhabbaz FL, AlAbduljabar TH, Alsaif A, Alsaif H, et al. Clinical characteristics of asymptomatic and symptomatic COVID-19 patients in the Eastern Province of Saudi Arabia. *J Infect Public Health* 2021;14(1):6–11.
- [6] Jafari R, Cegolon L, Jafari A, Kashaki M, Otoukesh B, Ghahderijani BH, et al. Large saddle pulmonary embolism in a woman infected by COVID-19 pneumonia. *Eur Heart J* 2020;41(22):2133.
- [7] Jafari R, Cegolon L, Dehghanpoor F, Javanbakht M, Izadi M, Saadat SH, et al. Early manifestation of ARDS in COVID-19 infection in a 51-year-old man affected by Mounier-Kuhn syndrome. *Heart Lung* 2020;49(6):855–7.
- [8] Zhou C, Gao C, Xie Y, Xu M. COVID-19 with spontaneous pneumomediastinum. *Lancet Infect Dis* 2020;20(4):510.
- [9] Elhakim TS, Abdul HS, Pelaez Romero C, Rodriguez-Fuentes Y. Spontaneous pneumomediastinum, pneumothorax and subcutaneous emphysema in COVID-19 pneumonia: a rare case and literature review. *BMJ Case Rep* 2020;13(12):e239489.
- [10] Hamad AM, Elmahrouk AF, Abdulatty OA. Alveolar air leakage in COVID-19 patients: Pneumomediastinum and/or pneumopericardium. *Heart Lung* 2020;49(6):881–2.
- [11] Jafari R, Cegolon L, Dehghanpoor F, Javanbakht M, Tabatabaei SMH. Typical Covid-19 case with primary pneumomediastinum in a 37 year old male. *Radiol Case Rep* 2021. doi:10.1016/j.radcr.2021.04.079.
- [12] Hazariwala V, Hadid H, Kirsch D, Big C. Spontaneous pneumomediastinum, pneumopericardium, pneumothorax and subcutaneous emphysema in patients with COVID-19 pneumonia, a case report. *J Cardiothorac Surg* 2020;15(1):301.
- [13] Rashedi S, Mardani M, Fooladgar M, Aliannejad R. Spontaneous pneumomediastinum, pneumopericardium, pneumothorax, and subcutaneous emphysema in a patient with COVID-19. *Radiol Case Rep* 2021;16(5):1158–61.
- [14] Chu CM, Leung YY, Hui JY, Hung IF, Chan VL, Leung WS, et al. Spontaneous pneumomediastinum in patients with severe acute respiratory syndrome. *Eur Respir J* 2004;23(6):802–4.
- [15] Machiraju PK, Alex NM, Safinaaz Baby NM. Pneumomediastinum in COVID-19: A series of three cases and review of literature. *SAGE Open Med Case Rep* 2021;9:2050313X211011807.
- [16] Juárez-Lloclla JP, León-Jiménez F, Urquiaga-Calderón J, Temoche-Nizama H, Bryce-Alberti M, Portmann-Baracco A, et al. Spontaneous pneumopericardium and pneumomediastinum in twelve COVID-19 patients. *Archivos de bronconeumologia* 2021;57(Suppl 1):86–8.
- [17] Carsana L, Sonzogni A, Nasr A, Rossi RS, Pellegrinelli A, Zerbi P, et al. Pulmonary post-mortem findings in a series of COVID-19 cases from northern Italy: a two-centre descriptive study. *Lancet Infect Dis* 2020;20(10):1135–40.