

“Rings of Saturn” appearance: a unique finding in a case of COVID-19 pneumonitis

Ramezan Jafari 

Patrick M. Colletti 

Amin Saburi 

From the Department of Radiology (R.J.), and Chemical Injuries research center (R.J., A.S. ✉ aminsaburi@yahoo.com), Baqiyatallah University of Medical Sciences Faculty of Medicine, Tehran, Iran; Department of Radiology (P.M.C.), Keck School of Medicine of USC, Los Angeles, CA, USA.

Dear Editor,

Since March 2019 when the severe respiratory syndrome of coronavirus disease 2019 (COVID-19) was announced, many radiologic manifestations of COVID-19 have been reported (1). Bilateral ground glass opacities (GGOs) predominantly at lower and posterior segments, mixed pattern of GGOs and consolidation and septal thickening are the most common features. Halo sign, nodular pattern, pleural effusion, and even completely normal findings are less frequently reported.

We have encountered a unique CT appearance of COVID-19 pneumonitis in a 24-year-old man. This finding is not a halo or reverse halo sign as might be expected in these organizing pneumonias. Figure demonstrates focal core opacity and two ring-like opacities immediately around it as in the “rings of Saturn”.

From a pathologic perspective, initially the virus enters the alveoli, followed by viral proliferation and local and generalized immune system response with cytokine storm by immunological modulators. This is most commonly followed by a recovery phase

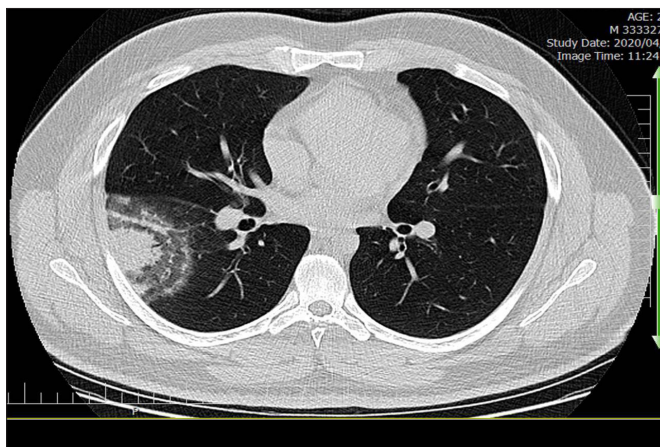


Figure. Axial chest CT scan shows a focal core opacity and two ring-like opacities immediately around it forming the appearance of “rings of Saturn”, at the periphery of the right lung.

with pulmonary parenchymal tissue repair processes (2). CT may initially demonstrate localized GGOs, followed by more widespread GGOs, typically combined with consolidation, crazy paving, and the formation of fibrotic strips (3, 4). Concurrent invasion and resolving phases are due to immunity response in multiple phases as seen in organizing pneumonia.

The most prominent differences between organizing pneumonia and resolving focal GGOs of COVID-19 include faster and less severe local reaction, with faster recovery and less fibrotic changes of simple resolving GGOs. Focal necrosis with surrounding hemorrhage is the main pathology of the halo sign typical of organizing pneumonia, which is not expected in COVID-19.

The pathological distribution of organizing pneumonia is in both alveoli and terminal bronchioles. Bronchiolar involvement can be due to thick alveolar exudates and inflammatory bronchial wall thickening.

Similarly, our presented feature appears to be due to bronchiole interstitial spreading and vascular impairment as a part of the cytokine storm with interstitial pneumonitis and focal organizing pneumonia with step-by-step veno-lymphatic spreading. This is the first report of this particular finding and needs to be supported by additional observations and studies.

Conflict of interest disclosure

The author declared no conflicts of interest.

References

1. Güneşli S, Atçeken Z, Doğan H, Altınmakas E, Atasoy KC. Radiological approach to COVID-19 pneumonia with an emphasis on chest CT. *Diagn Interv Radiol* 2020 Apr 30. [\[Crossref\]](#)
2. Mehta P, McAuley DF, Brown M, Sanchez E, Tattersall RS, Manson JJ. COVID-19: consider cytokine storm syndromes and immunosuppression. *Lancet* 2020; 395:1033–1034. [\[Crossref\]](#)
3. Pan F, Ye T, Sun P, Gui S, Liang B, Li L, et al. Time course of lung changes on chest CT during recovery from 2019 novel coronavirus (COVID-19) pneumonia. *Radiology*; 295:715–721. [\[Crossref\]](#)
4. Han R, Huang L, Jiang H, Dong J, Peng H, Zhang D. Early clinical and CT manifestations of coronavirus disease 2019 (COVID-19) pneumonia. *AJR Am J Roentgenol* 2020; 2020:1–6. [\[Crossref\]](#)

Received 25 May 2020; revision requested 2 June 2020; last revision received 3 June 2020; accepted 15 June 2020.

Published online 6 July 2020.

DOI 10.5152/dir.2020.20266

You may cite this article as: Jafari R, Colletti PM, Saburi A. “Rings of Saturn” appearance: a unique finding in a case of COVID-19 pneumonitis. *Diagn Interv Radiol* 6 July 2020 10.5152/dir.2020.20266 [Epub Ahead of Print]